

## PubMed

U.S. National Library of Medicine  
National Institutes of Health

Display Settings: Abstract



[J Craniovertebr Junction Spine](#). 2010 Jul;1(2):126-9.

### Supratentorial glioblastoma multiforme with spinal metastases.

Shah A, Redhu R, Nadkarni T, Goel A.

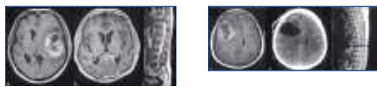
Department of Neurosurgery, K.E.M. Hospital and Seth G.S. Medical College, Parel, Mumbai, Maharashtra, India.

#### Abstract

Glioblastoma multiforme is the most common malignant brain tumor in adults. Metastasis of intracranial glioblastoma via the cerebrospinal fluid to the spine is a rare occurrence. We present two cases of glioblastoma multiforme with spinal leptomeningeal spread who presented with back pain and paraparesis.

PMID: 21572635 [PubMed - in process] PMID: PMC3075830 [Free PMC Article](#)

[Images from this publication.](#) [See all images \(2\)](#) [Free text](#)



[LinkOut - more resources](#)