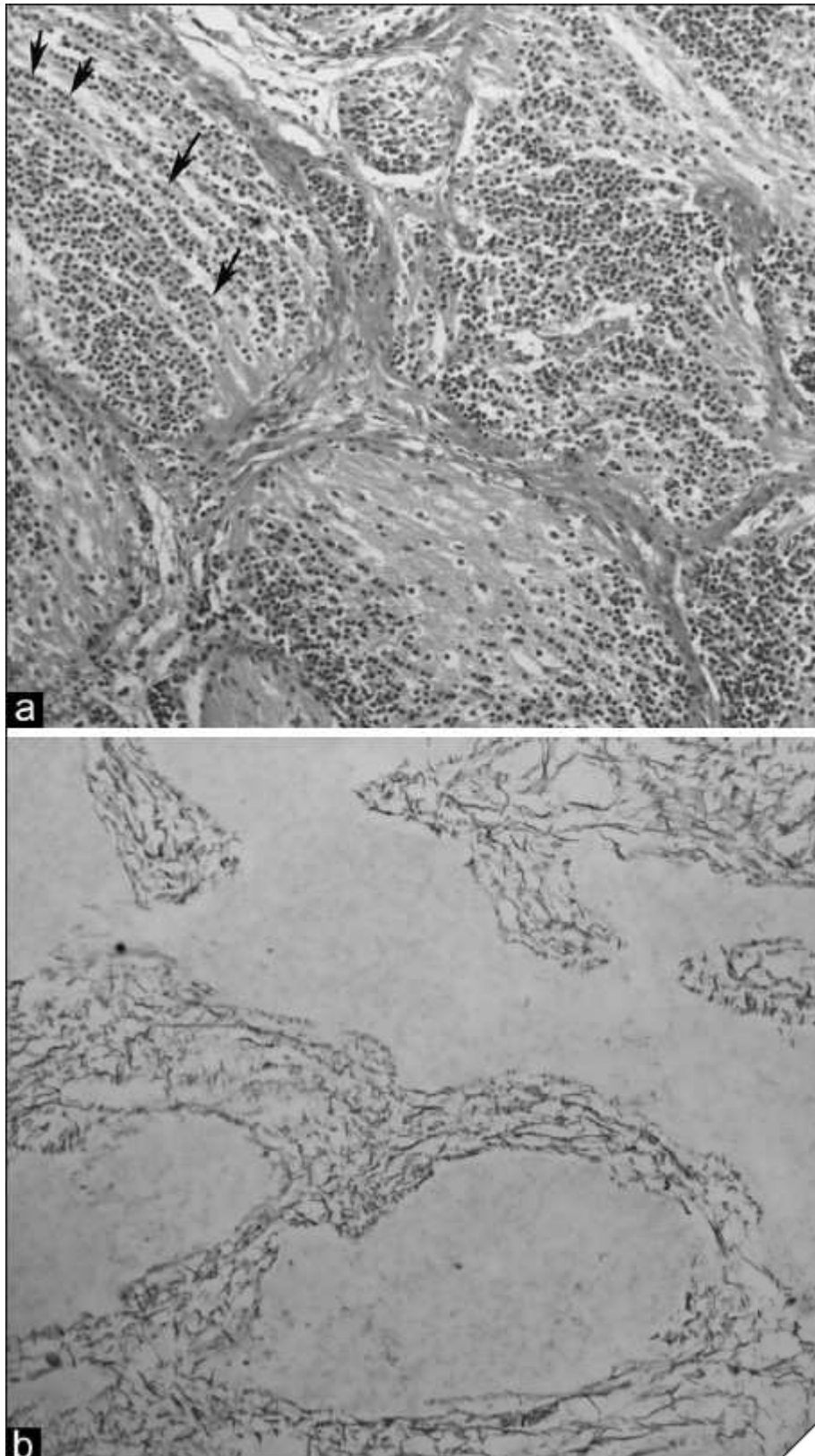



Figure 2: Hematoxylin-eosin stained section (a) shows large nodules with small neurocytic cells streaming (arrows) in a background of abundant neuropil (×200, original magnification). Reticulin stained section (b) shows "reticulin free" nodules with very little "reticulin rich" internodular component (×200, original magnification)





Impact Factor® for 2010
0.834
(®Thomson Reuters)