



Trigeminal neuralgia as the initial manifestation of temporal glioma: Report of three cases and a review of the literature

Mahmood Khalatbari and Abbas Amirjamshidi^{1*}

Department of Neurosurgery, Arad General Hospital, Somaye Ave., Tehran, Iran
¹Department of Neurosurgery, Sina Hospital, Emam Ave., Tehran, Iran
 Mahmood Khalatbari: mrkhalatbari@hotmail.com; Abbas Amirjamshidi: abamirjamshidi@yahoo.com
 *Corresponding author

Received April 29, 2011; Accepted June 19, 2011.

This is an open-access article distributed under the terms of the Creative Commons Attribution License, which permits unrestricted use, distribution, and reproduction in any medium, provided the original author and source are credited.

Abstract

Background:

It is almost an accepted scenario that trigeminal neuralgia (TN) occurs when there is a kind of vascular compression on the root entry zone of trigeminal nerve at pons. There are occasional reports about trigeminal neuralgia as the presenting sign of intracranial tumors but temporal glioma has rarely been included in the list.

Case Description:

We report three cases of temporal lobe glioma which presented with trigeminal neuralgia as the initial manifestation and review the relevant literature briefly. The patients were 19-, 20-, and 31-year-old males who presented with partially controlled TN. The tumor mass could be detected in paraclinical evaluations when the usual modalities of therapy for facial pain in our community were not effective. Excisional surgery led in full pain control in all the cases. Two of the patients died because of tumor recurrence after a year and the other one is being treated by adjuvants.

Conclusion:

We add these types of intracranial tumors to the list of the etiologies for TN and the possible mechanisms for the initiation of pain in these types of intracranial tumors are discussed.

Keywords: Glioma, intracranial tumor, tic douloureux, trigeminal neuralgia

INTRODUCTION

Trigeminal neuralgia (TN) is a sudden unilateral, brief stabbing recurrent pain, localized to the distribution of one or more divisions of the fifth cranial nerve.[1,5–7,14] It is classified into primary (idiopathic or classic) TN and secondary (or symptomatic) TN.[2,6,7] The exact etiology of primary TN is unknown, although vascular compression is often accepted as the origin of the pain,[1,7,18] but symptomatic TN is said to have a manifest cause, such as tumor, amyloidoma, infarct, or multiple sclerosis (MS).[1–7,9,11,12,14,16,19] Temporal glioma is a rare cause of TN, and our wide search of the literature using relevant key words and hand search of all the references could find only three similar cases reported previously.[9,12] It is intended to report three cases of temporal glioma of different grades presenting with TN and we will try to explain different mechanisms possibly involved in this relationship.

CASE REPORTS

Case 1

A 19-year-old male was admitted with severe headache and blurred vision. Episodic, lancinating left-sided facial pain

was a prominent complaint which appeared during the previous 3 months occurring several times a day and each time lasting 15–30 s. This pain was accompanied by toothache. The patient had been examined for sinusitis and dental problems for several times and his decayed left upper molar tooth was extracted but the pain sustained. He developed severe headache and blurred vision a week before admission.

Neurological examination revealed bilateral papilledema and mild right hemiparesis. The neuralgia extended along the V2 and V3 branches while, no trigger point could be specified. Other neurological examinations were normal. Magnetic resonance imaging (MRI) after contrast material injection demonstrated a large left temporal mass with mild perilesional edema and nonhomogeneous enhancement. It appeared to be attached to the floor of the temporal fossa, distorting the brain stem and enlarging the left cerebellopontine angle (CPA) cistern [Figure 1a–c].

A left frontotemporal craniotomy revealed a large tumor mass with severe adhesion to the dura of the temporal floor and temporal surface of the petrous bone. The tumor could be excised completely and turned out to be glioblastoma multiformis (GBM). The postoperative course was uneventful and the patient underwent whole brain radiotherapy. His neuralgia improved remarkably after operation and relieved completely 2 months thereafter. The patient died 13 months later because of tumor recurrence.

Case 2

A 31-year-old man presented with severe episodic, lancinating right-sided facial pain in the distribution of the mandibular nerve and with less severity in the distribution of the maxillary nerve of 6-month duration. The pain was associated with numbness of the right side of his face, especially in the vicinity of the mandibular nerve which could be triggered with drinking cold water. Considering his poor orodental hygiene, decayed teeth had been diagnosed to be the cause of pain and lead to the extraction of several of the right upper and lower teeth while he was also treated with antibiotics for gingivitis for a long period of time.

Two days before admission, he developed generalized tonic clonic seizure. Neurological examination revealed bilateral papilledema and mild paresthesia detectable along the distribution area of the mandibular nerve especially over the labial commissure. MRI revealed a large right temporal mass with nonhomogenous postcontrast enhancement, invading the wall of the right cavernous sinus, and spreading down to the right CPA. The enhancing bundle in the right CPA was compatible with the thickened course of the fifth nerve extending to the surface of the pons [Figures 2a and b].

A right temporal craniotomy was performed and a solid fleshy tumor infiltrating the dura of the floor of the right temporal fossa and lateral wall of the cavernous sinus could be resected as much as possible. The deepest part of the tumor could be excised as a layer of the tumor infiltrating the surface of the cavernous sinus. We stopped just over the tentorium and no dissection was done beyond this point. The contrast-enhanced CT scan and MRI performed in the postoperative period revealed a minimal residual tumor in the right CPA, located along the course of the right trigeminal nerve [Figure 2c].

The postoperative course was uneventful and a histopathological examination revealed the tumor to be GBM. The patient received postoperative whole brain radiotherapy. Five weeks after surgery, the patient was pain free but numbness of the face persisted for another 6 months. The patient died 17 months after surgery with tumor recurrence.

Case 3

A 20-year-old student was referred complaining from left hemifacial pain of more than 18 months. According to the report of the neurologist who was taking care of the patient, the pain was a rather typical lancinating left V2/V3 neuralgic pain which could hardly be managed by carbamazepin three times daily. Considering the young girl being too busy in the preparation for university examinations, some tranquilizers and other ordinary analgesics were also administered. She developed papilledema and visual field disturbances and accepted to undergo CT scanning and MR examination. When admitted in the department of neurosurgery, she was well cooperative with normal memory and speech. She complained of severe left hemifacial pain occurring every half an hour, with a burning sensation all

over the left side of her face, taking about less than 1 min each session. Bilateral papilledema, decreased visual acuity in both eyes to 6/10, and mild atrophy of the left temporalis and masticatory muscles were the findings in the physical examination. A contrast-enhanced CT scan [Figure 3a] showed a left frontotemporal deeply located, low-density lesion filling up the perichiasmatic cistern in the left side and extending alongside the edge of the tentorium into the parapeduncular cistern as a bubble (white arrow in Figure 3a). In MRI, it appeared as a deeply located infiltrative, gliomatous lesion involving the deep medial temporal region, extending along the connecting thalamic and frontal fibers toward the brain stem and thickening the fifth nerve bundle (white arrow in Figures 3b–d). Considering the large tumor mass and the need for mass decompressive surgery, a left pterional approach was performed and the left Sylvian fissure was opened. A whitish nonhomogeneously fibrogelatinous tumor was encountered filling up the limen insulae at a depth of 2 cm. Tumor decompression could be achieved in all directions while the arachnoid membrane of the most medial portion of the temporal fossa could be preserved intact. Looking through the deformed edge of the tentorium, the fifth nerve was bulky, whitish, and serpiginous in shape ending into a ballooned pontine surface infiltrated by the tumor of the same appearance. Histologically, the tumor was a grade II astrocytoma. The postoperative course was uneventful and all her headache and hemifacial neuralgic pain recovered. She underwent a course of whole brain radiation and there has been no sign of tumor regrowth after 10 months and no further pain.

DISCUSSION

The pathogenesis of TN is uncertain. What is nominated as typically TN is idiopathic, but may be due to a structural lesion.[4,6,14] The focal compression of the trigeminal nerve root, by an aberrant loop of an artery or vein at the root entry zone (REZ), has been the most acceptable theory for the development of idiopathic TN.[1,2,4,5,9] There are also other etiologies mentioned for TN including, infiltration of the nerve root, Gasserian ganglion or branches by a tumor or amyloidoma,[1,3,9,11,12] small infarcts, angioma or cavernoma in the pons, medulla, or REZ,[1,2,7,16] chemical irritation by neoplastic factors,[2,11,12,14] herniation of the temporal lobe,[2] chronic subdural hematoma, hydrocephalous[4] posterior fossa tumors,[5–8,14] contralateral posterior fossa tumors,[5,8] ipsilateral and contralateral supra tentorial tumors,[4,6,8,9,12] basilar invagination,[8] and Chiari malformation.[10]

Treatment options include medical and surgical treatment.[14,16] A mechanism-based versus a symptom-based treatment should be favored. Microvascular decompression (MVD) has become the main surgical treatment of TN.[8,14] The resection of tumor, with or without MVD, allows for the structures of posterior fossa to return to their normal position, and pain relief may be achieved.[4,8]

A supratentorial tumor can initiate TN even without a direct involvement of the trigeminal ganglion or nerve. Such tumors may lead to increased intracranial pressure and brain shift generating a pressure cone that distorts the brain stem and displaces an adjacent vessel, compressing the trigeminal nerve root.[4] Another explanatory mechanism in a patient with supratentorial tumor and hydrocephalous can be that pressure over the trigeminal sensory root rather than stretching of the nerve fiber leads to TN.[4] Such mechanisms can be an explanation for the development of pain in our case 1.

Extra-axial tumors of middle and posterior fossa can affect the trigeminal nerve by three different mechanisms: direct contact, direct compression, or infiltration.[3,12,13] All portions of the trigeminal nerve may be involved including nerve root, ganglion, and/or peripheral branches.[1–3] Tumors located in CPA, Gasserian ganglion, or trigeminal roots may produce TN.[3,11,12] TN, either classic or symptomatic, may represent the first manifestation of these tumors.[6] In these patients, TN reflects invasion, compression, distortion, or spread of the tumor in continuity of the trigeminal nerve.[3,15] This can be the better explanatory mechanism of pain development in the second case reported in this series.

The most common cause of tumoral TN is posterior fossa tumors.[3,7] These tumors are usually benign, slow growing, and extra-axially located that compress the trigeminal root and produce classic TN, although a type of symptomatic TN may also occur.[3] TN due to Gasserian ganglion infiltration by glioblastoma is a rare occurrence as in our cases 2 and 3, even though dural invasion is not uncommon in GBM.[6,12,17]

CONCLUSION

TN may be the initial manifestation of an intracranial supratentorial gliomatous tumor, especially in young patients. It is essential that MRI be undertaken to identify the underlying pathogenic mechanism of the symptom. A proper decompression of the tumor might have an essential role in the control of TN.

Footnotes

Available FREE in open access from: <http://www.surgicalneurologyint.com/text.asp?2011/2/1/114/83734>

REFERENCES

1. Bullitt E, Tew JM, Boyd J. Intracranial tumor in patient with facial pain. *J Neurosurg.* 1986;64:865–71. [PubMed: 3009737]
2. Cambuzzi E, Presa K, Silveira LC, Perondi GE. Epidermid cyst of the posterior fossa. A case report. *J Bras Pathol Med Lab.* 2011;47:79–82.
3. Cheng WC, Chang CN. Trigeminal neuralgia caused by contralateral supratentorial meningioma. *J Clin Neurosci.* 2008;15:1162–3. [PubMed: 18703336]
4. Cirak B, Kimaz N, Arslanoglu A. Trigeminal neuralgia caused by intracranial epidermoid tumor: Report of a case and review of different therapeutic modalities. *Pain Physician.* 2004;7:129–32. [PubMed: 16868626]
5. Deshmukh VR, Hott JS, Tabrizi P, Nakaji P, Feiz-Erfan I, Spetzler RF. Cavernous malformation of the trigeminal nerve manifesting with trigeminal neuralgia: Case report. *Neurosurgery.* 2005;56:E623. [PubMed: 15730590]
6. Deshpande S, Kaptain GJ, Pobereskin LH. Temporal glioblastoma causing trigeminal neuralgia. *J Neurosurg.* 1999;91:515. [PubMed: 10470832]
7. Gnanalingham K, Joshi SM, Lopez B, Ellamushi H, Hamlyn P. Trigeminal neuralgia secondary to Chiari's malformation--treatment with ventriculoperitoneal shunt. *Surg Neurol.* 2005;63:586–8. discussion 588-9. [PubMed: 15936398]
8. Goel A, Sham A. Trigeminal neuralgia in the presence of ectatic basilar artery and basilar invagination: Treatment by foramen magnum decompression: Case report. *J Neurosurg.* 2009;111:1220–2. [PubMed: 19558301]
9. Guttal KS, Naikmasur VG, Joshi SK, Bathi RJ. Trigeminal neuralgia secondary to epidermoid cyst at the cerebellopontine angle: Case report and brief review. *Odontology.* 2009;97:54–6. [PubMed: 19184299]
10. Hess B, Oberndorfer S, Urbanits S, Lahrmann H, Horvath-Mechtler B, Grisold W. Trigeminal neuralgia in two patients with glioblastoma. *Headache.* 2005;45:1267–70. [PubMed: 16178962]
11. Klieb HB, Freeman BV. Trigeminal neuralgia caused by intracranial epidermoid tumor: Report of a case. *J Can Dent Assoc.* 2008;74:63–5. [PubMed: 18298887]
12. Love S, Coakham HB. Trigeminal neuralgia: Pathology and pathogenesis. *Brain.* 2001;124:2347–60. [PubMed: 11701590]
13. Nomura T, Ikezaki K, Matsushima T, Fukui M. Trigeminal Neuralgia: Differentiation between intracranial mass lesion and ordinary vascular compression as causative lesion. *Neurosurg Rev.* 1994;17:51–7. [PubMed: 8078609]
14. Peñarrocha-Diago M, Mora-Escribano E, Bagán JV, Peñarrocha-Diago M. Neoplastic trigeminal neuropathy: Presentation of 7 cases. *Med Oral Patol Oral Cir Bucal.* 2006;11:E106–11. [PubMed: 16505784]
15. Perrini P, Rasile F, Leggate J. Trigeminal neuralgia as initial symptom of paramedian tentorial meningioma. *Neurol Sci.* 2009;30:81–3. [PubMed: 19169626]
16. Pfund Z, Szapáry L, Jászberényi O, Nagy F, Czopf J. Headache in intracranial tumors. *Cephalalgia.* 1999;19:787–90. discussion 765. [PubMed: 10595287]
17. Puca A, Meglio M, Tamburrini G, Vari R. Trigeminal involvement in intracranial tumors: Anatomical and clinical observation on 73 patients. *Acta Neurochir (Wien)* 1993;125:47–51. [PubMed: 8122555]
18. Toda K. Etiology of trigeminal neuralgia. *Int J Oral Sci.* 2007:10–8.
19. Warren HG, Kotsenas AL, Czervionke LF. Trigeminal and concurrent glossopharyngeal neuralgia secondary to lateral medullary infarction. *AJNR Am J Neuroradiol.* 2006;27:705–7. [PubMed: 16552020]

Figures and Tables

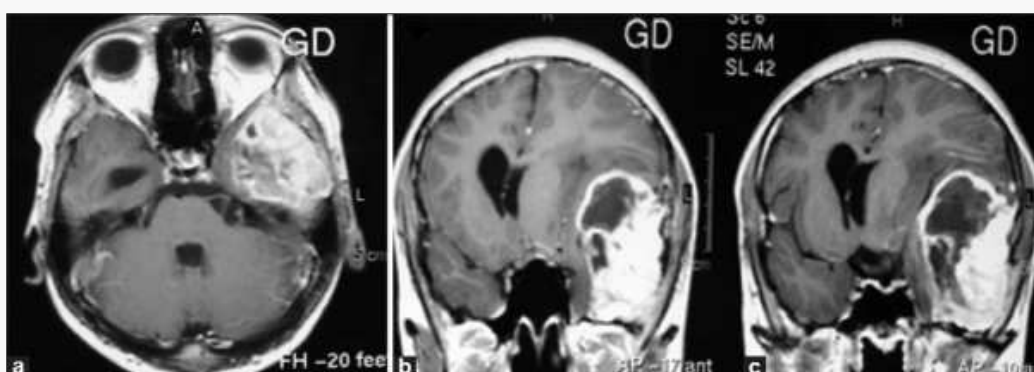


Figure 1

(a) Axial and (b and c) coronal T1-weighted GD-enhanced MRI showing a large left temporal glioblastoma multiformis. Tumor is infiltrating the dura of the floor of the temporal fossa and lateral wall of the cavernous sinus

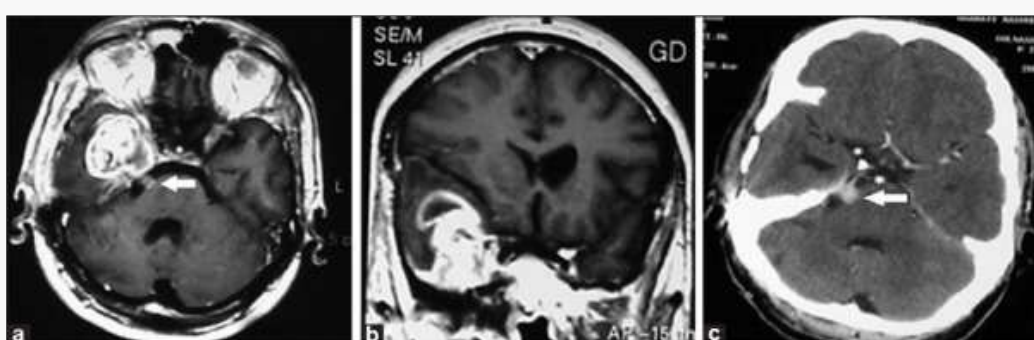


Figure 2

(a and b) Axial T1-weighted GD MRI showing a large right mesiotemporal glioblastoma multiformis with infiltration of gasserian ganglion and extension to the posterior fossa along the trigeminal nerve. (c) Coronal view taken after tumor excision, showing the remainder of the tumor infiltrating along the fifth nerve within the cerebellopontine angle

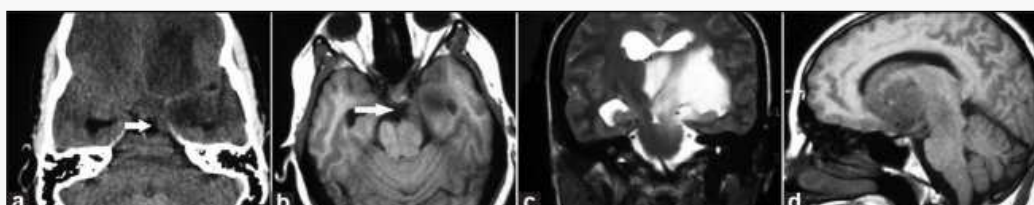


Figure 3

(a) Preoperative CT scan showing the hypodense intra-axial tumor infiltrating the frontal and temporal lobes extending into the ipsilateral cerebellopontine angle (white arrow). (b) The same view in MRI showing the tumor in the cerebellopontine angle located along the fifth cranial nerve (white arrow). (c) T₂W coronal view demonstrating the tumor infiltration into the ipsilateral cerebral peduncle. (d) Lateral view MR image in T₁W sequence and after contrast enhancement demonstrating the tumor extension along the fifth nerve at the edge of the tentorium