

Surgical Management of Spinal Metastases

PAUL KLIMO, JR., MEIC H. SCHMIDT

Department of Neurosurgery, University of Utah School of Medicine, Salt Lake City, Utah, USA

Key Words. Spine · Metastases · Surgery · Radiosurgery · Outcomes

ABSTRACT

Metastatic spread to the spinal column is a growing problem in patients with cancer. It can cause a number of sequelae including pain, instability, and neurologic deficit. If left untreated, progressive myelopathy results in the loss of motor, sensory, and autonomic functions. Except in rare circumstances, treatment is palliative. Traditionally, conventional fractionated external beam radiotherapy has been the treatment of choice. "Surgery" for metastatic spinal disease was, and generally continues to be, equated with laminectomy by many physicians. However, there has been a remarkable evolution in surgical techniques over the last 20 years. Today, the goal of surgery is to achieve circumferential decompression of the neural elements

while reconstructing and immediately stabilizing the spinal column. This has been made possible by the use of different surgical approaches and the exploitation of a burgeoning array of internal fixation devices. More recently, minimally invasive surgical techniques, such as endoscopy, kyphoplasty/vertebroplasty, and stereotactic radiosurgery, have been added to the surgeon's armamentarium. As the number of treatment options for metastatic spinal disease grows, it has become clear that effective implementation of treatment can only be achieved by a multidisciplinary approach. This will provide the surest means of maximizing the quality of the remainder of the patient's life. *The Oncologist* 2004;9:188-196

INTRODUCTION

Approximately 70% of patients with cancer have evidence of metastatic disease at the time of their deaths [1] (Fig. 1). The spinal column is the most common location among osseous sites for metastatic deposits [2]. Spinal involvement may occur in up to 40% of patients with cancer. Of 832 autopsies performed by Wong *et al.* [3] on patients who had died of cancer, 300 (36%) had spinal metastases. However, not all spinal metastases lead to neurologic compromise. Spinal cord compression from epidural metastases occurs in 5%-10% of cancer patients and in up to 40% of patients with preexisting nonspinal bone metastases [3-8]. Of those with bony spinal disease, 10%-20% develop symptomatic spinal cord compression, resulting in over 25,000 cases per year, and the number is expected to grow [7, 9, 10].

The thoracic spine is the most common site of disease (70%), followed by the lumbar spine (20%), and cervical spine (10%) [6, 7, 11]. Metastatic spinal disease can arise

from one of three locations (Fig. 2): the vertebral column (85%), the paravertebral region (10%-15%), and, rarely, the epidural or subarachnoid/intramedullary space itself (<5%) [6, 7, 11]. The posterior half of the vertebral body is usually involved first, with the anterior body, lamina, and pedicles invaded later [12]. Intramedullary metastases, including those that are intramedullary, are extremely rare but have been reported [13, 14]. Multiple lesions at noncontiguous levels occur in 10%-40% of cases [6, 7, 11, 15].

Approximately 50% of metastases arise from one of three primary types of cancer: breast, lung, or prostate [6]. These are followed by renal cancer, gastrointestinal cancer, thyroid cancer, sarcoma, and the lymphoreticular malignancies: lymphoma and multiple myeloma. Metastases from prostate cancer, breast cancer, melanoma, and lung cancer commonly cause spinal metastases in 90.5%, 74.3%, 54.5%, and 44.9% of patients, respectively [3]. However, the frequency of neurologic deficit as a result of epidural spinal cord compression

Correspondence: Meic H. Schmidt, M.D., University of Utah, Department of Neurosurgery, 30 North 1900 East Suite #3B-409 SOM, Salt Lake City, Utah 84132-2303, USA. Telephone: 801-581-6908; Fax 801-581-4385; e-mail: meic.schmidt@hsc.utah.edu
Received July 30, 2003; accepted for publication December 12, 2003. ©AlphaMed Press 1083-7159/2004/\$12.00/0

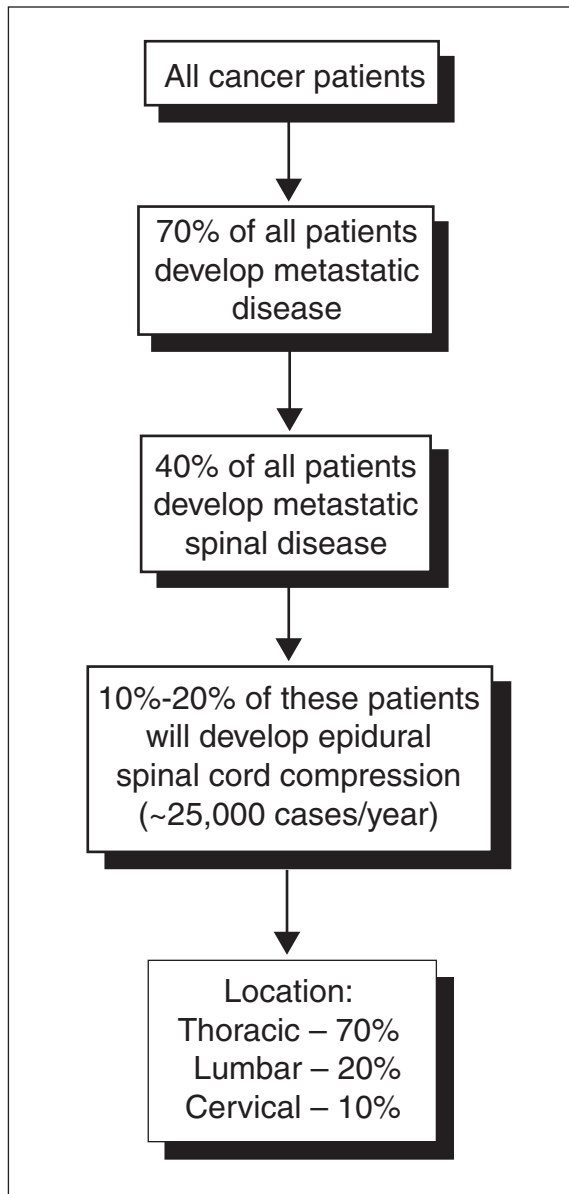


Figure 1. Diagram depicting the proportion of cancer patients affected by spinal metastases and epidural spinal cord compression and the distribution of involvement within regions of the spine.

varies with the site of primary disease as follows: 22% with breast cancer, 15% with lung cancer, and 10% with prostate cancer [7]. Some patients present with neurologic dysfunction and spinal pain without a known history of cancer. In some of the older surgical literature, this group accounted for up to 70% of the study population [16-19]. Of these cases, lung was the primary source more than 50% of the time [7, 18].

SURGICAL INDICATIONS

Treatment for spinal metastases is largely palliative. Only in rare cases, usually with renal cell carcinoma, can

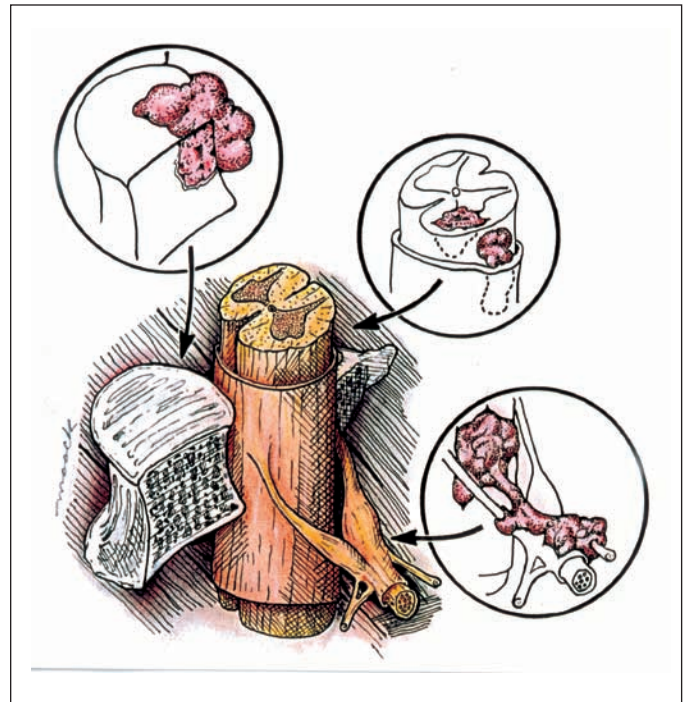


Figure 2. Locations of metastases to the spine. Most tumor emboli are found in the vertebral column surrounding the spinal cord, with the posterior half of the vertebral body being the most common initial focus (upper left inset). Tumor can also originate in a paravertebral location and track along the spinal nerves to enter the spinal column by way of the neural foramina (lower right inset). Both of these mechanisms can lead to epidural spinal cord compression. Intramedullary and subdural/leptomeningeal metastatic deposits are rarely encountered (middle inset).

cure be the goal if the spine is the only known site of metastasis [20]. Treatment can involve chemotherapy, radiation therapy, and surgery. The decision to pursue radical surgical treatment is complex, but the indications are becoming clearer. These include radioresistant tumors (sarcoma, lung, colon, renal cell), obvious spinal instability, clinically significant neural compression secondary to retropulsed bone or from spinal deformity, intractable pain unresponsive to nonoperative measures, and radiation failure (progression of deficit during treatment or spinal cord tolerance reached). Even if the patient satisfies one or more of the above indications, the type and goals of surgery must be determined by the patient's ability to tolerate the procedure (i.e., the patient's general medical condition) and, more importantly, by their estimated life expectancy. The latter is primarily based on the extent and aggressiveness of the cancer and its response to previous therapies. In general, the goals of surgery are to correct and prevent any further deformity by stabilizing the spine, decompressing neural structures (spinal cord and nerves), obtaining a diagnosis if the primary is unknown, and preventing local recurrence.

In general, most surgeons agree that excisional surgery should only be offered to those patients with an estimated life expectancy of greater than 3 months [21-23]. However, determining this estimate is difficult and is usually left to the expertise of the individual oncologist. In an effort to more accurately predict survival, *Tokuhashi et al.* [24] proposed a preoperative prognostic scoring system. Their model takes into account six variables: general medical condition, number of extraspinal metastases, number of vertebral metastases, status of metastases to the major internal organs, primary tumor type, and presence of a neurologic deficit (Table 1). Patients who have scores ≤ 5 generally die within 3 months whereas those with total scores ≥ 9 survive an average of 12 months or more. Several others, including the authors, have used this scoring system and have found it useful in making decisions regarding treatment [25-27].

SURGERY IN THE OLD ERA

For years, posterior decompressive laminectomy was the only surgical treatment offered for metastatic spinal cord compression. It is a relatively quick and simple procedure that enlarges the space for the spinal cord by removing the roof of the spinal canal (Fig. 3). Surgeons at that time realized that the operation was of limited value in regaining neurologic function, and some stated that the goal of surgery should be pain control rather than neurologic rescue [8, 28-32]. A number of retrospective reports found that laminectomy with adjuvant radiation was no more effective than radiation alone in retaining or restoring ambulatory function [29, 33, 34]. Furthermore, significant complications were associated with laminectomies, most notably the acceleration of preexisting spinal instability and wound complications. Thus, conventional external beam radiotherapy became and continues to be the first-line treatment in the majority of patients with newly diagnosed metastatic spinal disease.

SURGERY IN THE NEW ERA

With the failure of the indiscriminant use of laminectomies, the surgical treatment of spinal metastases remained dormant until the emergence and acceptance of approaches that were tailored to the exact anatomic location of the disease. This marked the beginning of a new era in the surgical management of spinal metastases. For example, transthoracic and posterolateral trajectories give the surgeon access to the thoracic vertebral bodies, the most common site of metastatic disease (Fig. 3). Currently, any part of the spine can be reached by the surgeon's hand. Using one approach or a combination of approaches allows the surgeon to excise the tumor, reconstruct the spinal column, and place internal fixation devices to achieve immediate stabilization. The goal of surgery in these patients today is to achieve

Table 1. Tokuhashi score [24]

1. General condition (Karnofsky)	Score
Poor (10%-40%)	0
Moderate (50%-70%)	1
Good (80%-100%)	2
2. Number of extraspinal bone metastases	
≥ 3	0
1-2	1
0	2
3. Number of metastases in the spine	
≥ 3	0
2	1
1	2
4. Metastases to major internal organs	
Irremovable	0
Removable	1
No metastases	2
5. Primary site of cancer	
Lung, stomach	0
Kidney, liver, uterus, other, unidentified	1
Thyroid, prostate, breast, rectum	2
6. Myelopathy	
Complete	0
Incomplete	1
None	2

circumferential spinal cord decompression. This requires removing the tumor at the site of spinal cord compression, a philosophy diametrically opposite to that of the days of decompressive laminectomies.

Sundaresan et al. [35] reported their results in 80 patients with solitary metastatic spinal lesions. Depending on the anatomic and radiologic extent of the tumor, they used a variety of approaches: an anterior approach was used in 32 patients, a strictly posterior or posterolateral approach was used in eight patients, and a combined anteroposterior approach was used in 40 patients. Preoperatively, 48 patients (60%) were ambulatory and 55 (69%) had a significant amount of pain. Postoperatively, 78 (98%) were ambulatory, including 94% of those who were initially nonambulatory. Pain was improved in 95% of patients with 76% having complete relief. Although the overall survival time was 30 months, there was a considerable range with the various tumor types. Patients with breast and renal cell carcinoma both had median survival times of 36 months, compared with 15 months and 12 months for gastrointestinal and unknown primary carcinomas, respectively.

Neurologic recovery is dependent on the rapidity of neurologic decline, duration of neurologic decline, and, most importantly, neurologic status before treatment. Use of these

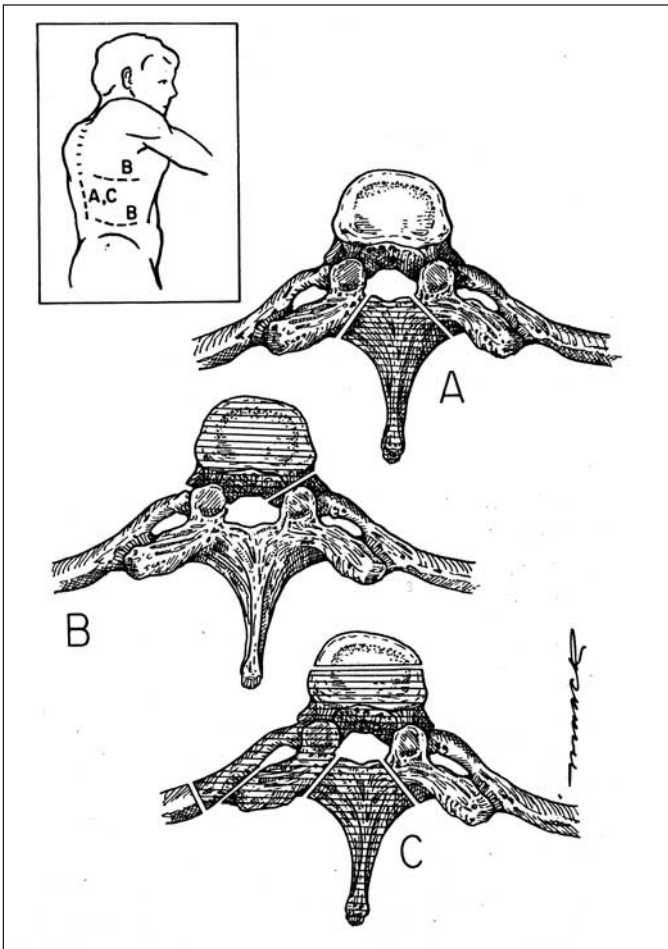


Figure 3. Surgical approaches to the spine. The shaded areas indicate the bone removed in each of the approaches. A) Laminectomy. The spinous process and the adjacent lamina are removed up to the junction of the pedicles. This was the standard surgical procedure for many years regardless of where the tumor was actually located within the vertebra. It can still be used for disease isolated to the posterior elements. B) Transthoracic or retroperitoneal. These anterior approaches provide direct access to the vertebral body in the thoracic (transthoracic) and thoracolumbar/lumbar regions (retroperitoneal). C) Posterolateral. For patients who cannot tolerate an anterior approach or who have significant posterior extension of their disease, a posterolateral approach provides excellent access to both the anterior and posterior elements. The inset shows the skin incisions for each of the approaches. The laminectomy (A) and posterolateral (B) approaches can be performed through a midline incision. The transthoracic (upper 'B' line) and retroperitoneal approaches (lower 'B' line) require flank incisions.

surgical techniques, usually followed by standard radiation therapy, seems to have dramatically improved neurologic outcome. In a review of the recent surgical literature, the average "success" rate was 85%, with "success" defined as the percentage of patients retaining or regaining ambulatory function after treatment [19, 21-23, 35-45]. More importantly, the average "rescue" rate from the same series, defined as the percentage of patients who regained ambulatory function, was 60%. This compares with a success rate of 73% and a rescue

rate of 29% in the most recent conventional radiation reports [46-51]. Furthermore, appropriate patient and surgical management seems to produce a positive effect on overall quality of life, especially in the reduction of pain [52]. For further details on the effectiveness of different treatment modalities for metastatic spinal disease, we direct readers to our recently published comprehensive literature review [53].

Given the seemingly superior results with surgery compared with conventional radiation therapy, it was clear to several investigators that the best way to compare these two treatment options was with a well-designed, randomized, controlled trial (RCT) [18, 33, 54]. Until recently, only one RCT had been attempted in the area of metastatic spinal disease, but it compared laminectomy with radiation and suffered from a lack of power [33]. However, at the most recent annual meeting of the American Society of Clinical Oncology (Chicago, 2003), *Patchell et al.* [55] presented results from their RCT comparing direct decompressive surgical resection followed by adjuvant radiation with conventional radiation alone. Both groups were treated with the same steroid protocol and both received the same total radiation dose (30 Gy). There were 50 patients in the surgical arm and 51 in the radiation arm. Patients treated with surgery retained ambulatory and sphincter function significantly longer than patients in the radiation group. Also, 56% of nonambulators in the surgical group regained the ability to walk, compared with 19% in the radiation group. As expected, length of survival was not significantly different between the two groups. This landmark study clearly shows, for the first time, an undisputed advantage for surgery, where the goal is to achieve complete spinal cord decompression, over radiation therapy, which has been the treatment of choice for the last 25 years.

However, there are substantial potential complications associated with this more aggressive surgical philosophy. Complications can be classified as surgical (e.g., wound infections, cerebrospinal fluid fistulas), hardware related (broken, misplaced, migrated), medical (e.g., pneumonia), and neurologic (i.e., new deficit). For example, in the series of 80 patients reported by *Sundaresan et al.* [35], 16 patients suffered surgical complications such as wound breakdowns and hematomas, four had hardware complications, two had medical complications, one had a neurologic complication, and one died from respiratory failure. *Gokaslan et al.* [40] performed transthoracic vertebrectomies on 72 patients. Complications, ranging from minor atelectasis to pulmonary embolism, occurred in 21 patients, with a 30-day mortality rate of 3%. One of the most problematic surgical complications is wound infection. Factors associated with wound infection include postoperative incontinence, posterior approach, surgery for tumor resection, and morbid obesity [56]. In metastatic spinal patients, preoperative radiation

(especially within 7 days), malnutrition, and steroid use are also risk factors [21, 35, 42, 57, 58]. The risk of developing complications is dependent on both the characteristics of the operation and the preoperative medical status of the patient. Both must be carefully considered when deciding the appropriate treatment.

In an attempt to reduce surgical morbidity and decrease recovery time, a new field called minimally invasive spinal surgery (MISS) has developed and is rapidly flourishing. MISS refers to a variety of techniques in which the primary objective is to minimize trauma to the surrounding anatomic structures during the approach to the surgical site. Many common spinal surgeries, such as microdiscectomy, interbody fusion, and pedicle screw/rod fixation, have been transformed with these new techniques [59]. Proponents of MISS cite shorter operative times, less blood loss, less postoperative pain, lower medication use, shorter hospital stays, and lower overall costs. Although much of the literature regarding MISS involves its use in degenerative disorders, there is a small, but growing, body of literature on its application in patients with spinal metastases.

One area that has received much attention recently is the use of endoscopes in the resection of metastatic tumors in the thoracic spine [60-64]. Although an endoscope can be used with open approaches, it is most often used in conjunction with a minimally invasive anterior transthoracic approach. Transthoracic endoscopic techniques were pioneered in the treatment of thoracic disc herniations and traumatic fractures but have also found a role in metastatic patients. Access to the diseased level is achieved by making 3-4 strategically placed 1-cm incisions in the lateral chest wall through which instruments are inserted (Fig. 4). The three phases of the surgery—vertebrectomy, reconstruction, and stabilization—can be performed entirely by endoscopic techniques.

Other minimally invasive spinal procedures that deserve special mention are percutaneous vertebroplasty and kyphoplasty. Both procedures involve the percutaneous injection of polymethylmethacrylate bone cement (PMMA) into a collapsed vertebral body. In vertebroplasty, the vertebral body is not re-expanded, whereas in kyphoplasty, a balloon is first inflated, thereby restoring the vertebral body height and reducing kyphosis, followed by injection of PMMA (Fig. 5). Currently, the most common indication for vertebroplasty or kyphoplasty is osteoporotic fracture; however, it is also a well-recognized therapeutic option for cancer patients [65-71]. Poor surgical candidates with disabling pain secondary to a pathologic thoracic or lumbar vertebral body fracture without epidural compression are ideal candidates for the procedure. The procedure is quick, performed on an outpatient basis, rarely associated with complications, and highly effective in reducing axial spinal pain [70]. *Fourney et al.*

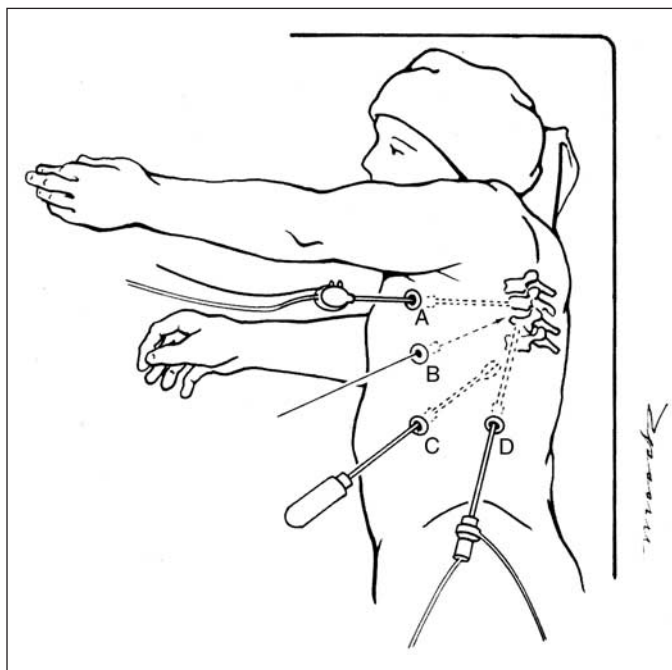


Figure 4. Schematic diagram depicting the positioning and placement of instruments for MISS. The patient is placed in a decubitus position and the lung is deflated. Multiple small incisions (A-D) are made in the chest wall through which instruments and a camera can be inserted. All stages of the more traditional open approach, including instrumentation, can be achieved through these access ports.

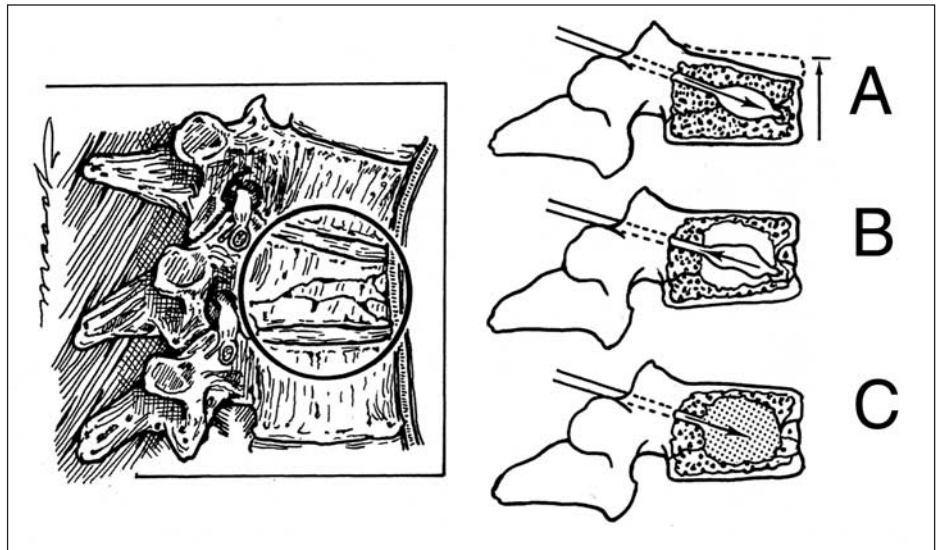
[70] performed 97 procedures (65 vertebroplasties and 32 kyphoplasties) during 58 treatment sessions in 56 patients with intractable spinal pain caused by pathologic vertebral body fractures. Using visual analog scale pain scores, there was improvement or complete relief of pain after 49 sessions (84%). None of the patients were made worse by the procedures. There was a significant decrease in analgesic usage at 1 month postprocedure, and the pain reduction remained significant at each follow-up interval for 1 year.

Although preliminary reports using the various MISS techniques appear promising, most metastatic spinal surgery is still performed via the more traditional open approaches. As with any new surgical procedure, there is a learning curve associated with MISS. Initially, MISS procedures can be more technically demanding, leading to longer operative times and higher complication rates. These drawbacks will, hopefully, diminish as MISS becomes more prevalent among spine surgeons.

SPINAL RADIOSURGERY

Conventional external beam radiotherapy typically delivers a total dose of 2,500-4,000 cGy of radiation over 8-20 daily fractions. Generous margins are used within the radiation field, typically one or two vertebral segments, to compensate for internal organ motion as well as patient

Figure 5. Vertebroplasty and kyphoplasty. A) The collapsed vertebral body is accessed through a transpedicular route. In kyphoplasty, a balloon at the end of the instrument is inflated, thus restoring the height of the body. This step is not performed in vertebroplasty. B and C) The balloon is removed and the defect is filled with bone cement (PMMA), which reestablishes the structural integrity of the vertebral body.



motion during the treatment. Thus, a substantial amount of normal tissue, including the spinal cord, is subjected to radiation [72-74]. Fractionating the treatment is done to optimize the tolerance of normal tissue to radiation. If radiation could be delivered to the target while decreasing the amount delivered to normal tissue, injury to the spinal cord would, theoretically, be reduced.

Nonconventional radiotherapy, which includes stereotactic radiosurgery (SRS) and intensity-modulated radiotherapy (IMRT), can do just that. SRS combines the principle of stereotactic localization to achieve accurate targeting with multiple radiation beams of equal intensity to deliver a high dose of radiation to a treatment site while minimizing exposure of normal tissue. In IMRT, multiple beams are also used, but the intensity of each individual beam can be modified to minimize radiation exposure to surrounding structures (Fig. 6). In SRS, treatment is usually delivered in one or two sessions, with total doses ranging from 800-1,800 cGy. Because spine lesions generally have a fixed relationship to the bony structures of the spinal column and the spine is the extracranial organ with the least breathing-related movement, SRS to the spine is particularly feasible. Early versions of spinal radiosurgery using a linear accelerator required multiple 1- to 2- cm incisions to fixate a frame to the spinous processes [75, 76]. Although the results were encouraging, the fixation process was cumbersome, resulting in long procedures and making repeat treatments difficult for the patient. Current image-guided SRS systems, such as the Novalis[®] system (BrainLAB Inc.; Munich, Germany) and CyberKnife[®] (Accuray Inc.; Sunnyvale, CA), differ from earlier frame-based systems in four ways: A) referencing is based on internal skeletal anatomy, implanted fiducials, or infrared surface markers; B) near real-time images are acquired to correct for motion; C) fixed isocenters are not required, allowing irregular dose shapes, and D) intensity modulation of radiation increases the conformality of radiation to the tumor while minimizing the dose of radiation to normal tissue [77-80].

The existing data on these modalities are, however, limited to small case series. Follow-up times have been short, and outcome measures, such as neurologic function, are rarely discussed. The research to date has shown image-guided SRS to be a safe intervention; however, its effectiveness has not been rigorously tested against other current therapies (surgery or conventional radiotherapy). Such data are needed before a treatment recommendation can be rendered. At this time, the application of spinal SRS is usually limited to patients who are poor surgical candidates with recurrent disease, and by the availability of the technology. Therefore, it should still be considered experimental therapy.

CONCLUSION

Spine surgeons are playing greater roles in the management of patients with metastatic disease. They are able to offer a wide array of effective treatment options ranging from radical, open excisional surgery to minimally invasive surgery, such as endoscopy and vertebroplasty, to ultramini-mal/noninvasive spinal radiosurgery. However, many cancer centers do not employ a multidisciplinary, upfront approach to patients with newly diagnosed metastatic spinal disease. The vast majority of patients are sent directly to radiation oncology for conventional external therapy. Most surgeons only see patients after they have failed their primary treatment. This will, hopefully, change in the near future based on the evidence of more recent reports, in particular, a randomized clinical trial that clearly shows a benefit for surgery as the primary mode of treatment. Multidisciplinary strategic treatment planning and a continuation of well-designed clinical research trials are needed in the future to fully evaluate and synthesize individualized therapy for patients with metastatic spinal disease with the ultimate goal of maximizing function and quality of life.

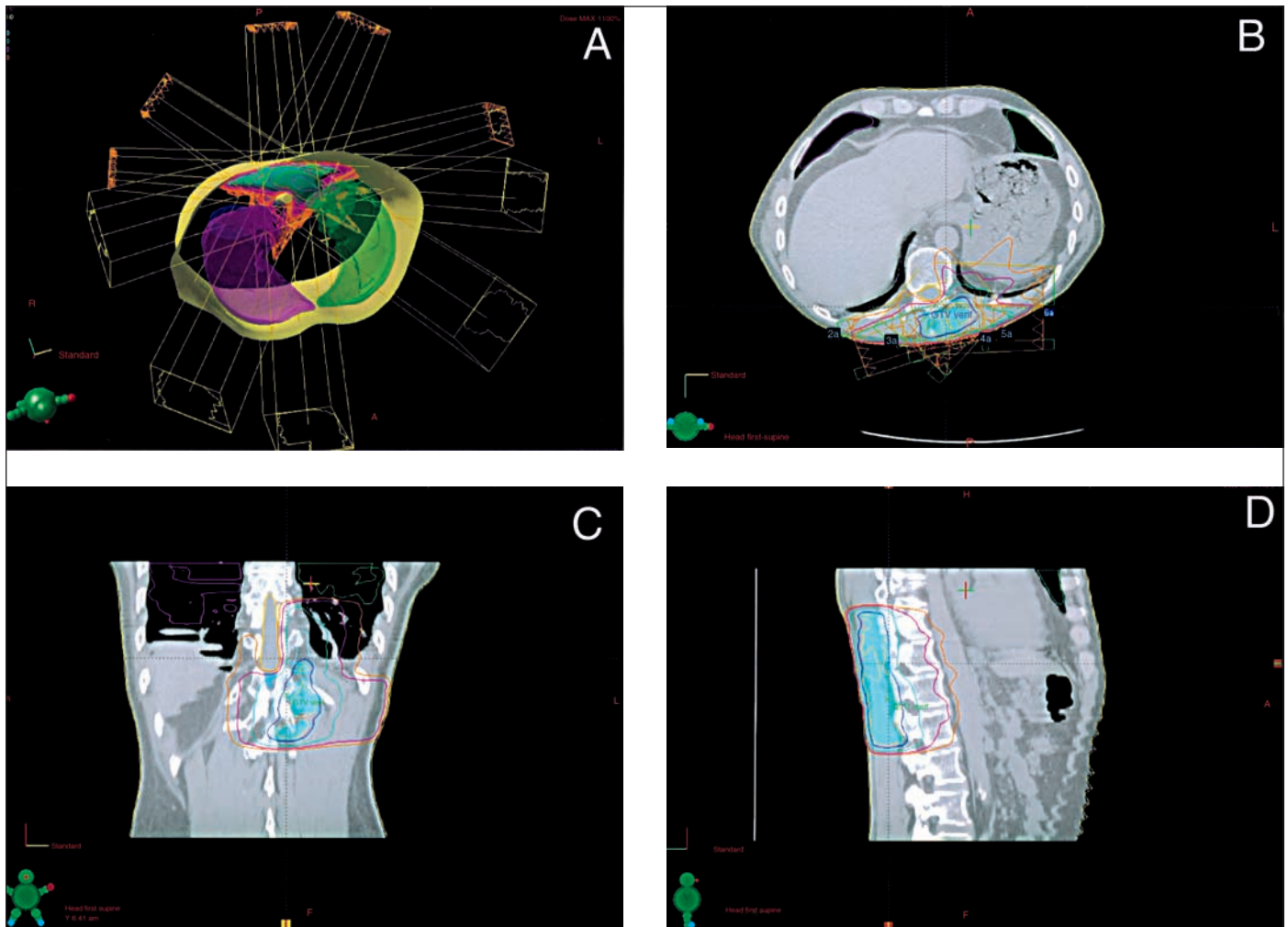


Figure 6. IMRT. This 56-year-old male has metastatic lung cancer to the left paraspinal region in the midthoracic area. A) Axial model of the patient showing the location of his tumor with respect to the spinal cord and lungs and the radial arrangement of the beams. B) Axial, C) coronal, and D) sagittal images of the planned treatment showing the isodose lines: 100% (yellow), 90% (dark blue), 80% (light blue), 50% (green), 30% (purple), and 20% (orange). The spinal cord is outlined in yellow. Note how the beams are contoured to avoid the spinal cord.

REFERENCES

- Harrington K. Metastatic tumors of the spine: diagnosis and treatment. *J Am Acad Orthop Surg* 1993;1:76-86.
- Bohm P, Huber J. The surgical treatment of bony metastases of the spine and limbs. *J Bone Joint Surg Br* 2002;84:521-529.
- Wong DA, Fornasier VL, MacNab I. Spinal metastases: the obvious, the occult, and the impostors. *Spine* 1990;15:1-4.
- Healey JH, Brown HK. Complications of bone metastases: surgical management. *Cancer* 2000;88(suppl 12):2940-2951.
- Bilsky MH, Lis E, Raizer J et al. The diagnosis and treatment of metastatic spinal tumor. *The Oncologist* 1999;4:459-469.
- Byrne TN. Spinal cord compression from epidural metastases. *N Engl J Med* 1992;327:614-619.
- Gerszten PC, Welch WC. Current surgical management of metastatic spinal disease. *Oncology (Huntingt)* 2000;14:1013-1024; discussion 1024, 1029-1030.
- Barron KD, Hirano A, Araki S et al. Experiences with metastatic neoplasms involving the spinal cord. *Neurology* 1959;9:91-106.
- Schaberg J, Gainer BJ. A profile of metastatic carcinoma of the spine. *Spine* 1985;10:19-20.
- Lada R, Kaminski HJ, Ruff R. Metastatic spinal cord compression. In: Vecht C, ed. *Neuro-oncology Part III. Neurological Disorders in Systemic Cancer*. Amsterdam: Elsevier Biomedical Publishers, 1997:167-189.
- Gilbert RW, Kim JH, Posner JB. Epidural spinal cord compression from metastatic tumor: diagnosis and treatment. *Ann Neurol* 1978;3:40-51.

- 12 Adams M, Sonntag VKH. Surgical treatment of metastatic cervical spine disease. *Contemp Neurosurg* 2001;23:1-5.
- 13 Hirsh LF, Thanki AS, Spector HB. Spinal subdural metastatic adenocarcinoma: case report and literature review. *Neurosurgery* 1982;10:621-625.
- 14 Schijns OE, Kurt E, Wessels P et al. Intramedullary spinal cord metastasis as a first manifestation of a renal cell carcinoma: report of a case and review of the literature. *Clin Neurol Neurosurg* 2000;102:249-254.
- 15 Cook AM, Lau TN, Tomlinson MJ et al. Magnetic resonance imaging of the whole spine in suspected malignant spinal cord compression: impact on management. *Clin Oncol (R Coll Radiol)* 1998;10:39-43.
- 16 Botterell EH, Fitzgerald GW. Spinal cord compression produced by extradural malignant tumours: early recognition, treatment and results. *Can Med Assoc J* 1959;80:791-796.
- 17 Brice J, McKissock W. Surgical treatment of malignant extradural spinal tumours. *Br Med J* 1965;5446:1341-1344.
- 18 Stark RJ, Henson RA, Evans SJ. Spinal metastases: a retrospective survey from a general hospital. *Brain* 1982;105:189-213.
- 19 Sundaresan N, Steinberger AA, Moore F et al. Indications and results of combined anterior-posterior approaches for spine tumor surgery. *J Neurosurg* 1996;85:438-446.
- 20 Boriani S, Biagini R, De Iure F et al. En bloc resections of bone tumors of the thoracolumbar spine. A preliminary report on 29 patients. *Spine* 1996;21:1927-1931.
- 21 Sundaresan N, Digiacinto GV, Hughes JE et al. Treatment of neoplastic spinal cord compression: results of a prospective study. *Neurosurgery* 1991;29:645-650.
- 22 Cooper PR, Errico TJ, Martin R et al. A systematic approach to spinal reconstruction after anterior decompression for neoplastic disease of the thoracic and lumbar spine. *Neurosurgery* 1993;32:1-8.
- 23 Hammerberg KW. Surgical treatment of metastatic spine disease. *Spine* 1992;17:1148-1153.
- 24 Tokuhashi Y, Matsuzaki H, Toriyama S et al. Scoring system for the preoperative evaluation of metastatic spine tumor prognosis. *Spine* 1990;15:1110-1113.
- 25 Oberndorfer S, Grisold W. The management of malignant spinal cord compression [letter]. *Spine* 2000;25:653-654.
- 26 Enkaoua EA, Doursounian L, Chatellier G et al. Vertebral metastases: a critical appreciation of the preoperative prognostic Tokuhashi score in a series of 71 cases. *Spine* 1997;22:2293-2298.
- 27 Chataigner H, Onimus M. Surgery in spinal metastasis without spinal cord compression: indications and strategy related to the risk of recurrence. *Eur Spine J* 2000;9:523-527.
- 28 Arseni CN, Simionescu MD, Horwath L. Tumors of the spine: a follow-up study of 350 patients with neurosurgical considerations. *Acta Psychiatr Scand* 1959;34:398-410.
- 29 Black P. Spinal metastasis: current status and recommended guidelines for management. *Neurosurgery* 1979;5:726-746.
- 30 Larson S, Wetzel N, Brochner R et al. The surgical treatment of metastatic epidural tumors. *Q Bull Northwestern Univ Med Sch* 1961;35:42-44.
- 31 Torma T. Malignant tumors of the spine and the spinal extradural space: a study based on 250 histologically verified cases. *Acta Chir Scand* 1957;13(suppl 225):1-176.
- 32 Perese DM. Treatment of metastatic extradural spinal cord tumors: a series of 30 cases. *Cancer* 1958;11:214-221.
- 33 Young RF, Post EM, King GA. Treatment of spinal epidural metastases. Randomized prospective comparison of laminectomy and radiotherapy. *J Neurosurg* 1980;53:741-748.
- 34 Findlay GF. Adverse effects of the management of malignant spinal cord compression. *J Neurol Neurosurg Psychiatry* 1984;47:761-768.
- 35 Sundaresan N, Rothman A, Manhart K et al. Surgery for solitary metastases of the spine. Rationale and results of treatment. *Spine* 2002;27:1802-1806.
- 36 Fidler MW. Anterior decompression and stabilisation of metastatic spinal fractures. *J Bone Joint Surg Br* 1986;68:83-90.
- 37 Harrington KD. Anterior decompression and stabilization of the spine as a treatment for vertebral collapse and spinal cord compression from metastatic malignancy. *Clin Orthop* 1988;233:177-197.
- 38 Moore AJ, Uttley D. Anterior decompression and stabilization of the spine in malignant disease. *Neurosurgery* 1989;24:713-717.
- 39 Akeyson EW, McCutcheon IE. Single-stage posterior vertebrectomy and replacement combined with posterior instrumentation for spinal metastasis. *J Neurosurg* 1996;85:211-220.
- 40 Gokaslan ZL, York JE, Walsh GL et al. Transthoracic vertebrectomy for metastatic spinal tumors. *J Neurosurg* 1998;89:599-609.
- 41 Bilsky MH, Boland P, Lis E et al. Single-stage posterolateral transpedicle approach for spondylectomy, epidural decompression, and circumferential fusion of spinal metastases. *Spine* 2000;25:2240-2249; discussion 2250.
- 42 Fourney DR, Abi-Said D, Lang FF et al. Use of pedicle screw fixation in the management of malignant spinal disease: experience in 100 consecutive procedures. *J Neurosurg* 2001;94(suppl 1):25-37.
- 43 Hatrick NC, Lucas JD, Timothy AR et al. The surgical treatment of metastatic disease of the spine. *Radiother Oncol* 2000;56:335-339.
- 44 Weigel B, Maghsudi M, Neumann C et al. Surgical management of symptomatic spinal metastases. Postoperative outcome and quality of life. *Spine* 1999;24:2240-2246.
- 45 Wise JJ, Fischgrund JS, Herkowitz HN et al. Complication, survival rates, and risk factors of surgery for metastatic disease of the spine. *Spine* 1999;24:1943-1951.
- 46 Maranzano E, Latini P, Checaglini F et al. Radiation therapy in metastatic spinal cord compression. A prospective analysis of 105 consecutive patients. *Cancer* 1991;67:1311-1317.
- 47 Maranzano E, Latini P. Effectiveness of radiation therapy without surgery in metastatic spinal cord compression: final results from a prospective trial. *Int J Radiat Oncol Biol Phys* 1995;32:959-967.
- 48 Latini P, Maranzano E, Ricci S et al. Role of radiotherapy in metastatic spinal cord compression: preliminary results from a prospective trial. *Radiother Oncol* 1989;15:227-233.

- 49 Helweg-Larsen S. Clinical outcome in metastatic spinal cord compression. A prospective study of 153 patients. *Acta Neurol Scand* 1996;94:269-275.
- 50 Katagiri H, Takahashi M, Inagaki J et al. Clinical results of nonsurgical treatment for spinal metastases. *Int J Radiat Oncol Biol Phys* 1998;42:1127-1132.
- 51 Zaidat OO, Ruff RL. Treatment of spinal epidural metastasis improves patient survival and functional state. *Neurology* 2002;58:1360-1366.
- 52 Wai EK, Finkelstein JA, Tangente RP et al. Quality of life in surgical treatment of metastatic spine disease. *Spine* 2003;28:508-512.
- 53 Klimo P, Kestle JRW, Schmidt MH. Treatment of metastatic spinal epidural disease. *Neurosurg Focus* 2003;15:1-9.
- 54 Loblaw DA, Laperriere NJ. Emergency treatment of malignant extradural spinal cord compression: an evidence-based guideline. *J Clin Oncol* 1998;16:1613-1624.
- 55 Patchell R, Tibbs P, Regine W et al. A randomized trial of direct decompressive surgical resection in the treatment of spinal cord compression caused by metastasis. *J Clin Oncol* 2003;21:237.
- 56 Olsen MA, Mayfield J, Laurysen C et al. Risk factors for surgical site infection in spinal surgery. *J Neurosurg* 2003;98(suppl 2):149-155.
- 57 Ghogawala Z, Mansfield FL, Borges LF. Spinal radiation before surgical decompression adversely affects outcomes of surgery for symptomatic metastatic spinal cord compression. *Spine* 2001;26:818-824.
- 58 McPhee IB, Williams RP, Swanson CE. Factors influencing wound healing after surgery for metastatic disease of the spine. *Spine* 1998;23:726-732; discussion 732-733.
- 59 Jaikumar S, Kim DH, Kam AC. History of minimally invasive spine surgery. *Neurosurgery* 2002;51(suppl 2):1-14.
- 60 McLain RF. Spinal cord decompression: an endoscopically assisted approach for metastatic tumors. *Spinal Cord* 2001;39:482-487.
- 61 Rosenthal D, Marquardt G, Lorenz R et al. Anterior decompression and stabilization using a microsurgical endoscopic technique for metastatic tumors of the thoracic spine. *J Neurosurg* 1996;84:565-572.
- 62 Han PP, Kenny K, Dickman CA. Thoracoscopic approaches to the thoracic spine: experience with 241 surgical procedures. *Neurosurgery* 2002;51(suppl 2):88-95.
- 63 Le Huec JC, Lesprit E, Guibaud JD et al. Minimally invasive endoscopic approach to the cervicothoracic junction for vertebral metastases: report of two cases. *Eur Spine J* 2001;10:421-426.
- 64 Huang TJ, Hsu RW, Liu HH et al. Video-assisted thoracoscopic surgery to the upper thoracic spine. *Surg Endosc* 1999;13:123-126.
- 65 Weill A, Chiras J, Simon JM et al. Spinal metastases: indications for and results of percutaneous injection of acrylic surgical cement. *Radiology* 1996;199:241-247.
- 66 Cotten A, Dewatre F, Cortet B et al. Percutaneous vertebroplasty for osteolytic metastases and myeloma: effects of the percentage of lesion filling and the leakage of methyl methacrylate at clinical follow-up. *Radiology* 1996;200:525-530.
- 67 Laredo JD, Le Gars L. Acrylic bone cement injection for the treatment of bone metastases. *Rev Rheum Engl Ed* 1997;64:145-146.
- 68 Levine SA, Perin LA, Hayes D et al. An evidence-based evaluation of percutaneous vertebroplasty. *Manag Care* 2000;9:56-60, 63.
- 69 Barr JD, Barr MS, Lemley TJ et al. Percutaneous vertebroplasty for pain relief and spinal stabilization. *Spine* 2000;25:923-928.
- 70 Fourny DR, Schomer DF, Nader R et al. Percutaneous vertebroplasty and kyphoplasty for painful vertebral body fractures in cancer patients. *J Neurosurg* 2003;98(suppl 1):21-30.
- 71 Kaemmerlen P, Thiesse P, Jonas P et al. Percutaneous injection of orthopedic cement in metastatic vertebral lesions. *N Engl J Med* 1989;321:121.
- 72 Tan BC, Khor TH. Radiation myelitis in carcinoma of the nasopharynx. *Clin Radiol* 1969;20:329-331.
- 73 Koehler PJ, Verbiest H, Jager J et al. Delayed radiation myelopathy: serial MR-imaging and pathology. *Clin Neurol Neurosurg* 1996;98:197-201.
- 74 Wara WM, Phillips TL, Shelton GE et al. Radiation tolerance of the spinal cord. *Cancer* 1975;35:1558-1562.
- 75 Hamilton AJ, Lulu BA, Fosmire H et al. Preliminary clinical experience with linear accelerator-based spinal stereotactic radiosurgery. *Neurosurgery* 1995;36:311-319.
- 76 Takacs I, Hamilton AJ. Extracranial stereotactic radiosurgery: applications for the spine and beyond. *Neurosurg Clin N Am* 1999;10:257-270.
- 77 Ryu S, Yin F, Rock J et al. Image-guided and intensity-modulated radiosurgery for patients with spinal metastasis. *Cancer* 2003;97:2013-2018.
- 78 Ryu SI, Kim DH, Martin DP et al. Image-guided spinal stereotactic radiosurgery. *Techn Neurosurg* 2003;8:56-64.
- 79 Ryu SI, Chang SD, Kim DH et al. Image-guided hypo-fractionated stereotactic radiosurgery to spinal lesions. *Neurosurgery* 2001;49:838-846.
- 80 Gertszten P, Ozhasoglu C, Burton S et al. Feasibility of frameless single-fraction stereotactic radiosurgery for spinal lesions. *Neurosurg Focus* 2001;13:Article 2.