

# Serum GFAP is a diagnostic marker for glioblastoma multiforme

C. S. Jung,<sup>1</sup> C. Foerch,<sup>2</sup> A. Schänzer,<sup>3</sup> A. Heck,<sup>2</sup> K. H. Plate,<sup>3</sup> V. Seifert,<sup>1</sup> H. Steinmetz,<sup>2</sup> A. Raabe<sup>1</sup> and M. Sitzer<sup>2</sup>

<sup>1</sup>Department of Neurosurgery, <sup>2</sup>Department of Neurology, <sup>3</sup>Institute of Neurology (Edinger Institute), Johann Wolfgang Goethe University, Frankfurt am Main, Germany

Correspondence to: Carla S. Jung, MD, Department of Neurosurgery, Ruprecht Karls University Heidelberg, Im Neuenheimer Feld 400, 69120 Heidelberg, Germany  
E-mail: carla.jung@med.uni-heidelberg.de

**A serum marker for malignant cerebral astrocytomas could improve both differential diagnosis and clinical management of brain tumour patients. To evaluate whether the serum concentration of glial fibrillary acidic protein (GFAP) may indicate glioblastoma multiforme (GBM) in patients with single supratentorial space-occupying lesions, we prospectively examined 50 consecutive patients with histologically proven GBM, World Health Organization (WHO) grade IV, 14 patients with anaplastic astrocytoma (WHO grade III), 4 patients with anaplastic oligodendroglioma, 13 patients with diffuse astrocytoma (WHO grade II), 17 patients with a single cerebral metastasis and 50 healthy controls. Serum was taken from the patients before tumour resection or stereotactic biopsy. Serum GFAP levels were determined using a commercially available ELISA test and were detectable in 40 out of the 50 GBM patients (median: 0.18 µg/l; range: 0–5.6 µg/l). The levels were significantly elevated compared with those of the non-GBM tumour patients and healthy controls (median: 0 µg/l; range: 0–0.024 µg/l;  $P < 0.0001$ , respectively). Non-GBM tumour patients and all healthy subjects showed zero serum GFAP levels. There was a significant correlation between tumour volume (Spearman Rho,  $CC = 0.47$ ; 95% confidence interval, 0.2–0.67;  $P < 0.001$ ), tumour necrosis volume ( $CC = 0.49$ ; 95% confidence interval, 0.2–0.72;  $P = 0.004$ ), the amount of necrotic GFAP positive cells ( $CC = 0.61$ ; 95% confidence interval, 0.29–0.81;  $P = 0.007$ ) and serum GFAP level among the GBM patients. A serum GFAP level of  $> 0.05$  µg/l was 76% sensitive and 100% specific for the diagnosis of GBM in patients with a single supratentorial mass lesion in this series. Therefore, it can be concluded that serum GFAP constitutes a diagnostic biomarker for GBM. Future studies should investigate whether serum GFAP could also be used to monitor therapeutic effects and whether it may have a prognostic value.**

**Keywords:** glioblastoma; GFAP; biomarker; serum

**Abbreviations:** GFAP = glial fibrillary acidic protein; GBM = glioblastoma multiforme; MRI = magnetic resonance images; CSF = cerebrospinal fluid; NSE = neuron-specific enolase; VEGF = vascular endothelial growth factor

Received January 30, 2007. Revised October 10, 2007. Accepted October 10, 2007. Advance Access publication November 12, 2007

## Introduction

Glioblastoma multiforme (GBM; WHO grade IV tumour) is the most malignant form of cerebral glioma and accounts for ~50% of such tumours (Kleihues *et al.*, 1993; Kleihues and Cavane, 2000). It can present as a high-grade lesion from the onset (primary or de novo GBM) (Zülch, 1986) or can evolve from a lower-grade precursor lesion, such as WHO grade II astrocytoma and WHO grade III anaplastic

astrocytoma (secondary or progressive GBM) (Kleihues and Ohgaki, 1999; Brat *et al.*, 2002).

Using brain imaging, the differential diagnosis of GBM includes metastases, abscesses or sometimes even immune-mediated demyelinating mass lesions (Voorhies *et al.*, 1980). Although brain imaging and clinical characteristics may suggest the diagnosis of a GBM, histopathological

**Table 1** Clinical and histological characteristics of  $n = 104$  patients with a solitary supratentorial mass lesions and  $n = 50$  healthy controls (normal subjects), including gender, age, tumour volume, type of surgery and dexamethasone treatment

| Histology           | <i>n</i> | Females (%) | Age (years $\pm$ SD) | Tumour volume (cm <sup>3</sup> $\pm$ SD) | Surgery                       | Dexamethasone (%) |
|---------------------|----------|-------------|----------------------|--|-------------------------------|-------------------|
| GBM                 | 50       | 42          | 63 $\pm$ 13          | 35.4 $\pm$ 24.8                          | 23 STX<br>20 TR<br>7 STX + TR | 62                |
| anapl. Oligo        | 4        | 75          | 36 $\pm$ 5           | 22.3 $\pm$ 14.6                          | 0 STX<br>3 TR<br>1 STX + TR   | 25                |
| Astro III           | 14       | 29          | 54 $\pm$ 18          | 30.9 $\pm$ 36.3                          | 9 STX<br>2 TR<br>3 STX + TR   | 21                |
| Astro II            | 13       | 46          | 46 $\pm$ 19          | 36.9 $\pm$ 36.7                          | 10 STX<br>2 TR<br>1 STX + TR  | 23                |
| single Metastasis   | 17       | 47          | 60 $\pm$ 14          | 21.8 $\pm$ 29.9                          | 7 STX<br>9 TR<br>1 STX + TR   | 59                |
| multiple Metastasis | 6        | 17          | 56 $\pm$ 16          | 94.9 $\pm$ 184.5                         | No surgery                    | 67                |
| Normal subjects     | 50       | 52          | 48 $\pm$ 16          | No lesion                                | No surgery                    | 0                 |

Because of a tendency towards smaller tumour volumes in the single brain metastasis group compared to the GBM group, six additional patients with multiple brain metastases were examined.

GBM = glioblastoma multiforme (WHO grade IV); anapl. Oligo = anaplastic Oligodendroglioma (WHO grade III), Astro III = anaplastic astrocytoma (WHO grade III), Astro II = diffuse astrocytoma (WHO grade II); STX = stereotactic biopsy; TR = tumour resection.

analysis of the tumour tissue is mandatory for a definite diagnosis. Despite recent progress in the combined use of surgical resection, radiation and chemotherapy, the prognosis of GBM is still poor, with a median survival time of 12.1–14.6 months after diagnosis (Stupp *et al.*, 2005).

Glial fibrillary acidic protein (GFAP), first described in 1971 by Eng *et al.*, is a member of the cytoskeletal protein family and is widely expressed in astroglial cells and in neural stem cells (Eng *et al.*, 1971, 2000; Doetsch, 2003). It is also expressed in astroglial tumours, such as astrocytoma and GBM (Jacque *et al.*, 1978; Hamaya *et al.*, 1985; Abaza *et al.*, 1998). We hypothesized that GFAP may be released from astroglial tumours, especially malignant gliomas, into the serum and could therefore be used as a diagnostic biomarker for GBM. On the basis of this hypothesis, we studied GFAP levels in the serum of GBM patients and various control groups.

## Patients and Methods

The study protocol was approved by the ethics review committee of the Medical Faculty of the Johann Wolfgang Goethe University in Frankfurt am Main, Germany. All patients and controls gave their written informed consent.

The study included 98 consecutive patients with an initial diagnosis of solitary supratentorial intracerebral mass lesion admitted for surgery at the Department of Neurosurgery at the above-mentioned university between July 2004 and July 2005. Fifty healthy subjects without intracerebral lesions or a history of head injury served as controls. Of the 98 patients, 61 underwent stereotactic biopsy and/or tumour resection ( $n = 45$ ).

Tumour specimens were examined neuropathologically and classified according to the WHO classification of tumours (Kleihues *et al.*, 1993).

## Patients and histopathological diagnoses

Fifty of the 98 patients had a GBM (age: 61  $\pm$  13 years; median: 60.5 years; range 26–84 years; 29 males and 21 females); 13 patients had a WHO grade II astrocytoma (age: 40  $\pm$  16 years; median: 37 years; range: 20–75 years; 7 males and 6 females) and 14 had a WHO grade III astrocytoma (age: 50  $\pm$  14 years; median: 52 years; range: 22–72 years; 10 males and 4 females); 4 patients had an anaplastic oligodendroglioma (age: 36  $\pm$  5 years; median: 38 years; range: 29–40 years; 1 male and 3 females); 17 patients had a single cerebral metastasis of a primary non-cerebral tumour (median: 60 years, range: 26–74 years; 9 males and 8 females). In the latter group, the primary tumours were identified as breast cancer in two patients, ovarian carcinoma in one patient, pulmonary adenocarcinoma in one patient, melanoma in one patient, renal cell carcinoma in one patient, rectal adenocarcinoma in another patient and remained unknown in 10 patients. The single brain metastasis group showed a tendency towards smaller tumour volumes compared to the GBM group (Table 1). Therefore, to exclude any effects of tumour volume on GFAP detectability we additionally included six patients with multiple brain metastases. Clinical data of the patients are presented in the Table 1.

## Normal subjects

We included 50 persons with neither a history of head injury nor signs or symptoms characteristic for an intracerebral lesion. These apparently healthy subjects were aged 49  $\pm$  16 years (median: 50 years, range: 18–78 years; 24 males and 26 females).

### Volumetric measurements

The tumour volume of each patient as well as the necrotic area within the GBM were estimated from preoperative, post-contrast T1-weighted magnetic resonance images (MRI) using a modified ellipsoid volume equation:  $(A \times B \times C)/2$ , with  $A$ ,  $B$  and  $C$  representing the three dimensions of the tumour and the three dimensions of the necrotic area, detectable as hypointense, non-contrast-enhancing area within the GBM (Kothari *et al.*, 1996). In addition, T2-weighted images and FLAIR-weighted images were used to verify the measurements and to further differentiate tumour from perifocal oedema. The MRI scans had been performed no more than 14 days before serum sampling.

### Sample collection and GFAP measurement

A single serum sample was taken from each subject at the time of admission, prior to any treatment, e.g. cranial surgery, radiation therapy or chemotherapy. Samples were centrifuged immediately and supernatants were stored at  $-70^{\circ}\text{C}$  until the levels of GFAP were assessed.

Serum GFAP levels were determined blind to the clinical data on the corresponding patients using a biotin-labelled antibody-based sandwich enzyme immunoassay for the quantitative measurement of human GFAP. GFAP-ELISA test conditions and quantification were as described by the manufacturer (BioVendor, Heidelberg, Germany). In short, samples, quality controls and calibrators were diluted 1:3 prior to analysis. Duplicates of 100  $\mu\text{l}$  samples and calibrators were then pipetted into the ELISA wells and incubated for 2 h at room temperature, followed by 1 h incubation with a biotin-labelled Anti-GFAP-antibody solution and 1 h of incubation with a Streptavidin-HRP conjugate. Between each step, 4 cycles of thorough washing (400  $\mu\text{l}$  washing solution per well) were performed. Finally, the plate was incubated for approximately 20 min at room temperature under avoidance of direct sunlight with the substrate solution of the kit. The colour development was stopped by adding the commercially available stopping solution of the kit. The absorbance was measured by reading the ELISA plate at 450 nm. The detection limit of the test, defined as the concentration of the mean of the absorbance of blanks (calibrator diluent) plus 3 SD of the absorbance of the blanks ( $A_{\text{blank}} + 3 \times \text{SD}_{\text{blank}}$ ), was measured and calculated as 0.012  $\mu\text{g/l}$  ( $n = 15$ ). All values below this detection limit were defined as 0  $\mu\text{g/l}$ .

### GFAP analysis in tumour tissue

GFAP expression after GFAP immunohistochemical staining of the tumour specimen was determined by two independent observers who were blinded to GFAP serum levels. GFAP expression was assessed in non-necrotic tumour areas of five separate microscopic fields of view under a magnification of  $40\times$  and was classified as the mean of the percentage of GFAP immunohistochemical positive tumour cells. GFAP expression was ranked as:  $<25$ , 25–50, 51–75 and  $>75\%$  GFAP positive tumour cells.  $\kappa$  statistics revealed a good interobserver agreement of  $\kappa = 0.86$ . Furthermore, on the assumption that the assessed GFAP expression of non-necrotic tumour areas is comparable to those in necrosis, the product of GFAP expression and tumour necrosis volume was determined as a measure for the amount of necrotic GFAP positive cells in GBM.

### Statistical analysis

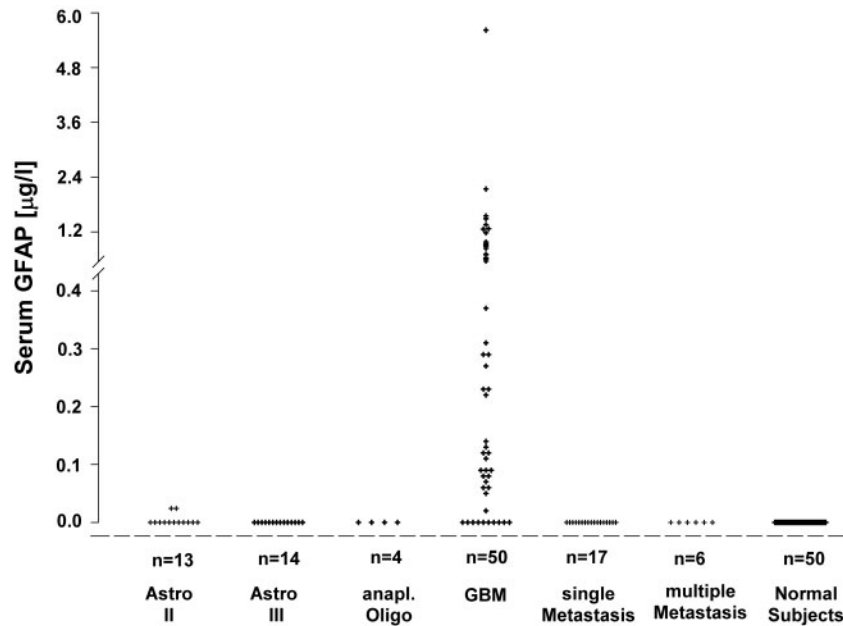
Data are presented as median and range. Statistical analysis of the data was performed using non-parametric tests. For comparisons, non-parametric correlation measures (Spearman correlation) were used. Statistical significance was defined as  $P < 0.05$ . Using receiver operating characteristic (ROC) curve analysis, a GFAP cut-off point was determined for which accuracy measures were derived from cross-tabulations.

### Results

In GBM patients, we found a median serum GFAP level of 0.18  $\mu\text{g/l}$  (range: 0–5.6  $\mu\text{g/l}$ ;  $n = 50$ ). This was significantly higher than in the non-GBM tumour patients (median: 0; range 0–0.024  $\mu\text{g/l}$ ;  $n = 54$ ) or in the normal subjects (median: 0; range 0–0  $\mu\text{g/l}$ ;  $n = 50$ ) ( $P < 0.001$  respectively; see Fig. 1). All normal subjects showed zero serum GFAP levels (detection limit: 0.012  $\mu\text{g/l}$ ; see Fig. 1). Two non-GBM tumour patients with a WHO grade II astrocytoma, both diagnosed via stereotactic biopsy, had serum GFAP levels of 0.024  $\mu\text{g/l}$ . While one patient had an extremely large and diffuse growing tumour, MR-spectroscopy scans of the other patient revealed retrospectively a small area within the tumour suspicious for a higher grade glioma, which might have been missed performing stereotactic biopsy. The remaining non-GBM-tumour patients with WHO grade II or III astrocytomas, anaplastic oligodendrogliomas as well as solitary and multiple cerebral metastases showed serum GFAP levels below the detection limit. Furthermore, in 10 GBM patients, serum GFAP was not detectable ( $\leq 0.012 \mu\text{g/l}$ ). Tumour volume and tumour necrosis volume were significantly smaller in these GBM patients ( $n = 10$ ;  $19.4 \pm 18.7 \text{ cm}^3$ ; median:  $8.9 \text{ cm}^3$  and  $2.0 \pm 4.5 \text{ cm}^3$ ; median:  $0.03 \text{ cm}^3$ , respectively) than in those GBM patients with detectable serum GFAP ( $n = 40$ ;  $38.4 \pm 24.4 \text{ cm}^3$ ; median:  $31 \text{ cm}^3$ ;  $P = 0.01$  and  $12.60 \pm 13.7 \text{ cm}^3$ ; median:  $5.2 \text{ cm}^3$ ;  $P = 0.0004$ , respectively). Tumour volume significantly correlated with tumour necrosis volume in GBM patients (Spearman Rho,  $\text{CC} = 0.82$ ; 95% confidence interval, 0.65–0.91;  $P < 0.0001$ ). Furthermore, there was a significant correlation between tumour volume and serum GFAP level as well as between tumour necrosis volume and serum GFAP in GBM patients (Spearman Rho,  $\text{CC} = 0.47$ ; 95% confidence interval, 0.2–0.67;  $P < 0.001$  and  $\text{CC} = 0.49$ ; 95% confidence interval, 0.2–0.72;  $P = 0.004$ , respectively). No significant associations emerged for age, gender or treatment with dexamethasone ( $P > 0.05$ , respectively).

The ROC analysis cut-off point of 0.05  $\mu\text{g/l}$  of serum GFAP afforded a sensitivity of 76% and a specificity of 100% for the differentiation of GBM patients from non-GBM tumour patients or healthy controls (area under the curve, 0.9;  $P < 0.001$ ). The positive and negative predictive values were 1.0 and 0.89, respectively.

Immunohistochemically, GFAP was not detectable in cerebral metastases. However, all glial tumours expressed



**Fig. 1** Frequency plot of serum GFAP values measured in patients with a solitary supratentorial mass lesion and normal subjects. Each point corresponds to a single GFAP value. GFAP values were significantly elevated in patients with GBM. GBM = glioblastoma multiforme (WHO grade IV); anapl. Oligo = anaplastic Oligodendroglioma (WHO grade III), Astro III = anaplastic astrocytoma (WHO grade III); Astro II = diffuse astrocytoma (WHO grade II); STX = stereotactic biopsy; TR = tumour resection.

immunohistochemically GFAP. Patients with astrocytoma grade III revealed GFAP expression of >50% and those with astrocytoma grade II of >25%. Oligodendroglial and oligoastroglial tumours expressed low amounts of GFAP (<25%). GFAP expression varied little within each non-GBM tumour group. However, GBM tumour tissue samples showed a strong variability in GFAP expression ranging from <25% in some patients to almost 100% in others. Although, there was no direct correlation between GFAP expression and serum GFAP levels ( $P=0.3$ ), it was evident, that GBM patients without tumour necrosis had, independent of their GFAP expression, serum GFAP levels below the detection limit. Whereas, those GBM patients with similar necrosis volumes and differing GFAP expressions showed with increasing GFAP expression a corresponding increase in serum GFAP level. The product of GFAP expression and tumour necrosis volume as a measure for the amount of necrotic GFAP positive cells in GBM patients was strongly correlated with GFAP serum levels (Spearman Rho,  $CC=0.61$ ; 95% confidence interval,  $0.29-0.81$ ;  $P=0.007$ ).

## Discussion

Our study shows that GFAP is detectable in the serum of many patients with GBM (WHO grade IV tumour). The serum GFAP levels of these patients were significantly higher than those of patients with WHO grade II or III astrocytomas or of patients with brain metastases. Furthermore, serum GFAP levels were correlated with the GBM volume and tumour necrosis volume measured from

MRI scans. In this sample, a serum GFAP level above  $0.05 \mu\text{g/l}$  provided a sensitivity of 76% and a specificity of 100% for the diagnosis of GBM. Serum GFAP therefore appears to be a promising new diagnostic biomarker.

Elevated GFAP levels also occur after head trauma, intracerebral haemorrhage and ischaemic stroke (Herrmann and Ehrenreich, 2003; Pelinka *et al.*, 2004; Foerch *et al.*, 2006), but these conditions were excluded from this study. In the past, other markers have been found in the cerebrospinal fluid (CSF) of glioma patients, including S100, neuron-specific enolase (NSE), recoverin (protein A) and vascular endothelial growth factor (VEGF) (Gronowitz *et al.*, 1984; Cochran and Wen, 1985; Taomoto *et al.*, 1987; Sampath *et al.*, 2004). However, the need for repeated CSF examinations limits their widespread use. Only a few potential markers have been detected in the serum of brain tumour patients, including recoverin, low-molecular weight caldesmon (l-CaD) and cathepsin D. Serum and tissue gene expression levels of cathepsin D were significantly higher in GBM patients than in low-grade astrocytoma patients, prompting the suggestion that cathepsin D could be used as a predictor of short survival (Fukuda *et al.*, 2005). Serum l-CaD and recoverin levels showed no significant difference between patients with low-grade and patients with high-grade gliomas, although, they were elevated compared with those of the healthy controls. Recoverin levels were particularly elevated in patients with recurrent GBM (Sampath *et al.*, 2004; Zheng *et al.*, 2005).

GFAP is highly specific for cells with astrocytic differentiation and is widely used as a reliable marker in the immunohistochemical diagnosis and differentiation of

brain tumours (Bonnin and Rubinstein, 1984). Whereas GFAP is consistently expressed, at least to some extent, in all gliomas including glioblastoma, it is usually not found in meningiomas, medulloblastomas and brain metastasis of carcinomas (Fischer *et al.*, 1989; Oh and Prayson, 1999). In our series, all glioblastomas, WHO grade II and III astrocytomas as well as oligoastroglial and oligodendroglial tumours, showed to some extent immunoreactivity for GFAP, whereas cerebral metastases were negative. Comparable to previous reports, the most uniform staining was seen in well-differentiated grade II astrocytomas, whereas GBM patients showed a strong variability in GFAP expression and distribution (Royds *et al.*, 1986 *acta neuropathol*). Although GFAP is immunohistochemically evident in low and high-grade glioma, it remains unclear why serum GFAP mainly indicates GBM. However, several pathophysiological mechanisms or their combination may explain increased GFAP levels in serum of GBM patients, including: (i) GFAP expression, (ii) tumour necrosis and/or (iii) disruption of the blood–brain-barrier (BBB).

As described previously (Gottschalk and Szymas, 1987), a high variability of GFAP expression in GBM tumour tissue was also observed in this study. However, GFAP expression was not directly correlated with GFAP serum levels. GFAP expression is believed to indicate the differentiation status of astrocytes. Some GBM, which show high cell proliferation, contain more undifferentiated astrocytes and do not express GFAP extensively. Others express GFAP at the same amounts as anaplastic astrocytomas (Herpers *et al.*, 1986), or even demonstrate increased expression of all GFAP isoforms (Blechingberg *et al.*, 2007). A decrease in GFAP expression has been associated with growth and malignancy of glial tumours (Rutka *et al.*, 1997) and was more prominent in high-grade than in low-grade gliomas (Chumbalkar *et al.*, 2005). *In vitro*, a reduced expression of GFAP in some glioblastoma cell lines was also associated with more aggressive and invasive potentials (Murphy *et al.*, 1998; Zhou and Skalli, 2000; Lee *et al.*, 2005). While some factors like TGF- $\alpha$  lead to decreased GFAP expression (Zhou and Skalli, 2000; Lee *et al.*, 2005), multiple other factors including glial growth factor (GGF) (Brookes *et al.*, 1980) and glial maturation factor (GMF) (Lim and Mitsunobu, 1974) were proven to influence and upregulate GFAP expression *in vitro* (Chiu and Goldman, 1985; Morrison *et al.*, 1985).

Although there were no significant differences in tumour volume between the GBM and non-GBM tumour patients (Table 1), we found a strong correlation between tumour volume and GFAP level in the GBM patients. Tumour volume therefore appears to influence the sensitivity of GFAP detection in GBM patients. Tumour volume was further correlated with tumour necrosis volume. Tumour necrosis, which is absent in low-grade glioma and present in GBM was significantly correlated with serum GFAP levels. Tumour necrosis might therefore explain elevated GFAP serum levels in patients with voluminous GBMs.

Furthermore, the product of GFAP expression in tissue samples and tumour necrosis as a measure for necrotic GFAP positive cells in GBM patients was strongly correlated with GFAP serum levels, emphasizing the direct and/or indirect influence of these two factors on GFAP detectability in serum.

Normal subjects and patients with WHO grade II or III astrocytomas showed serum GFAP levels below the cut-off point of 0.05  $\mu\text{g/l}$  and were comparable with the results of healthy blood donors (range:  $0.002 \pm 0.049 \mu\text{g/l}$ ) described by others (Missler *et al.*, 1999). Furthermore, in a small series of large, solitary, supratentorial meningiomas (tumour volume:  $39.3 \pm 33.4 \text{ cm}^3$ ; median:  $29 \text{ cm}^3$ ,  $n=6$ ) serum GFAP levels were also undetectable (data not shown), indicating that simple brain compression does not result in serum GFAP elevation.

GFAP has a relatively high molecular weight of 52 kDa (Yen *et al.*, 1976), which limits its transit through the BBB under physiological conditions. Similar to acute head trauma, intracerebral haemorrhage or brain infarction (Herrmann and Ehrenreich, 2003; Pelinka *et al.*, 2004; Foerch *et al.*, 2006), elevated serum GFAP concentrations in GBM patients are likely to reflect, both, GFAP leakage from glial cells (e.g. tumour necrosis) and a disruption of the BBB. In fact, both are among the diagnostic criteria defining GBM.

There are some limitations to this study that will require further research. First, the GFAP-ELISA test has not yet been standardized. Second, although our sample of 50 GBM patients, 54 non-GBM tumour patients and 50 healthy controls appears sufficient for an exploratory pilot study, its results require confirmation in larger cohorts. Finally, abscesses and immune-mediated space-occupying lesions were not included in this series. Consequently, our promising results regarding the specificity of serum GFAP may not apply to inflammatory conditions.

## Conclusion

Elevated serum GFAP concentrations of  $>0.05 \mu\text{g/l}$  appear to predict GBM in *de novo* brain tumour patients with a single supratentorial lesion. Furthermore, serum GFAP concentration was closely linked with glioblastoma tumour volume, tumour necrosis volume and the estimated amount of necrotic GFAP positive cells in 50 patients. This study opens up the possibility of using serum GFAP as a diagnostically and therapeutically relevant biomarker in the management of GBM patients.

## References

- Abaza MS, Shaban F, Narayan RK, Atassi MZ. Human glioma associated intermediate filament proteins: over-expression, co-localization and cross-reactivity. *Anticancer Res* 1998; 18: 1333–40.
- Blechingberg J, Holm IE, Nielsen KB, Jensen TH, Jorgensen AL, Nielsen AL. Identification and characterization of GFAPkappa, a novel glial fibrillary acidic protein isoform. *Glia* 2007; 55: 497–507.

- Bonnin JM, Rubinstein LJ. Immunohistochemistry of central nervous system tumors. Its contributions to neurosurgical diagnosis. *J Neurosurg* 1984; 60: 1121–33.
- Brat DJ, Castellano-Sanchez A, Kaur B, Van Meir EG. Genetic and biologic progression in astrocytomas and their relation to angiogenic dysregulation. *Adv Anat Pathol* 2002; 9: 24–36.
- Brockes JP, Lemke GE, Balzer DR Jr. Purification and preliminary characterization of a glial growth factor from the bovine pituitary. *J Biol Chem* 1980; 255: 8374–7.
- Chiu FC, Goldman JE. Regulation of glial fibrillary acidic protein (GFAP) expression in CNS development and in pathological states. *J Neuroimmunol* 1985; 8: 283–92.
- Chumbalkar VC, Subhashini C, Dhople VM, Sundaram CS, Jagannadham MV, Kumar KN, et al. Differential protein expression in human gliomas and molecular insights. *Proteomics* 2005; 5: 1167–77.
- Cochran AJ, Wen DR. S-100 protein as a marker for melanocytic and other tumours. *Pathology* 1985; 17: 340–5.
- Doetsch F. The glial identity of neural stem cells. *Nat Neurosci* 2003; 6: 1127–34.
- Eng LF, Ghirnikar RS, Lee YL. Glial fibrillary acidic protein: GFAP—thirty-one years (1969–2000). *Neurochem Res* 2000; 25: 1439–51.
- Eng LF, Vanderhaeghen JJ, Bignami A, Gerstl B. An acidic protein isolated from fibrous astrocytes. *Brain Res* 1971; 28: 351–4.
- Fischer W, Heller T, Herrmann E, Schreiber D. [A simple method for the isolation of GFAP and its use for the study of brain tumors]. *Zentralbl Allg Pathol* 1989; 135: 33–41.
- Foerch C, Curdt I, Yan B, Dvorak F, Hermans M, Berkefeld J, et al. Serum glial fibrillary acidic protein as a biomarker for intracerebral haemorrhage in patients with acute stroke. *J Neurol Neurosurg Psychiatry* 2006; 77: 181–4.
- Fukuda ME, Iwadata Y, Machida T, Hiwasa T, Nimura Y, Nagai Y, et al. Cathepsin D is a potential serum marker for poor prognosis in glioma patients. *Cancer Res* 2005; 65: 5190–4.
- Gottschalk J, Szymas J. [Significance of immunohistochemistry for neuro-oncology. VI. Occurrence, localization and distribution of glial fibrillary acid protein (GFAP) in 820 tumors]. *Zentralbl Allg Pathol* 1987; 133: 319–30.
- Gronowitz JS, Kallander CF, Hagberg H, Persson L. Deoxythymidine-kinase in cerebrospinal fluid: a new potential “marker” for brain tumours. *Acta Neurochir (Wien)* 1984; 73: 1–12.
- Hamaya K, Doi K, Tanaka T, Nishimoto A. The determination of glial fibrillary acidic protein for the diagnosis and histogenetic study of central nervous system tumors: a study of 152 cases. *Acta Med Okayama* 1985; 39: 453–62.
- Herpers MJ, Ramaekers FC, Aldeweireldt J, Moesker O, Slooff J. Co-expression of glial fibrillary acidic protein- and vimentin-type intermediate filaments in human astrocytomas. *Acta Neuropathol (Berl)* 1986; 70: 333–9.
- Herrmann M, Ehrenreich H. Brain derived proteins as markers of acute stroke: their relation to pathophysiology, outcome prediction and neuroprotective drug monitoring. *Restor Neurol Neurosci* 2003; 21: 177–90.
- Jacque CM, Vinner C, Kujas M, Raoul M, Racadot J, Baumann NA. Determination of glial fibrillary acidic protein (GFAP) in human brain tumors. *J Neurol Sci* 1978; 35: 147–55.
- Kleihues P, Burger PC, Scheithauer BW. The new WHO classification of brain tumours. *Brain Pathol* 1993; 3: 255–68.
- Kleihues P, Cavenee WK. World Health Organization: classification of tumours. Pathology and genetics of tumours of the nervous system. Lyon: IARC Press; 2000.
- Kleihues P, Ohgaki H. Primary and secondary glioblastomas: from concept to clinical diagnosis. *Neuro-oncol* 1999; 1: 44–51.
- Kothari RU, Brott T, Broderick JP, Barsan WG, Sauerbeck LR, Zuccarello M, et al. The ABCs of measuring intracerebral hemorrhage volumes. *Stroke* 1996; 27: 1304–5.
- Lee K, Jeon K, Kim JM, Kim VN, Choi DH, Kim SU, et al. Downregulation of GFAP, TSP-1, and p53 in human glioblastoma cell line, U373MG, by IE1 protein from human cytomegalovirus. *Glia* 2005; 51: 1–12.
- Lim R, Mitsunobu K. Brain cells in culture: morphological transformation by a protein. *Science* 1974; 185: 63–6.
- Missler U, Wiesmann M, Wittmann G, Magerkurth O, Hagenstrom H. Measurement of glial fibrillary acidic protein in human blood: analytical method and preliminary clinical results. *Clin Chem* 1999; 45: 138–41.
- Morrison RS, De Vellis J, Lee YL, Bradshaw RA, Eng LF. Hormones and growth factors induce the synthesis of glial fibrillary acidic protein in rat brain astrocytes. *J Neurosci Res* 1985; 14: 167–76.
- Murphy KG, Hatton JD, Hoi Sang U. Role of glial fibrillary acidic protein expression in the biology of human glioblastoma U-373MG cells. *J Neurosurg* 1998; 89: 997–1006.
- Oh D, Prayson RA. Evaluation of epithelial and keratin markers in glioblastoma multiforme: an immunohistochemical study. *Arch Pathol Lab Med* 1999; 123: 917–20.
- Pelinka LE, Kroepfl A, Schmidhammer R, Krenn M, Buchinger W, Redl H, et al. Glial fibrillary acidic protein in serum after traumatic brain injury and multiple trauma. *J Trauma* 2004; 57: 1006–12.
- Rutka JT, Murakami M, Dirks PB, Hubbard SL, Becker LE, Fukuyama K, et al. Role of glial filaments in cells and tumors of glial origin: a review. *J Neurosurg* 1997; 87: 420–30.
- Sampath P, Weaver CE, Sungarian A, Cortez S, Alderson L, Stopa EG. Cerebrospinal fluid (vascular endothelial growth factor) and serologic (recoverin) tumor markers for malignant glioma. *Cancer Control* 2004; 11: 174–80.
- Stupp R, Mason WP, van den Bent MJ, Weller M, Fisher B, Taphoorn MJB, et al. Radiotherapy plus concomitant and adjuvant temozolomide for glioblastoma. *N Engl J Med* 2005; 352: 987–96.
- Taomoto K, Kokunai T, Okuda T, Tamaki N, Matsumoto S, Hashimoto N. [The value of neuron specific enolase (NSE) in patients with brain tumors]. *No To Shinkei* 1987; 39: 169–73.
- Voorhies RM, Sundaresan N, Thaler HT. The single supratentorial lesion. An evaluation of preoperative diagnostic tests. *J Neurosurg* 1980; 53: 364–8.
- Yen SH, Dahl D, Schachner M, Shelanski ML. Biochemistry of the filaments of brain. *Proc Natl Acad Sci USA* 1976; 73: 529–33.
- Zheng PP, Hop WC, Sillevs Smitt PA, van den Bent MJ, Avezaat CJ, Luijckx TM, et al. Low-molecular weight caldesmon as a potential serum marker for glioma. *Clin Cancer Res* 2005; 11: 4388–92.
- Zhou R, Skalli O. TGF- $\alpha$  differentially regulates GFAP, vimentin, and nestin gene expression in U-373 MG glioblastoma cells: correlation with cell shape and motility. *Exp Cell Res* 2000; 254: 269–78.
- Zülch. Brain tumors. Their biology and pathology. Berlin: Springer; 1986.