

Response of Intracranial Metastases to Erlotinib Therapy

Brain metastases are a common occurrence in non-small-cell lung cancer (NSCLC). The standard treatment is radiation therapy with or without resection, but chemotherapy is only modestly pallia-

tive for recurrence within the brain. We describe a 60-year-old non-smoking Native American woman who presented with left-sided weakness due to a stage IV adenocarcinoma of the lung with multiple brain metastases. The patient received whole-brain radiotherapy (33 Gy in 11 fractions) with resolution of her symptoms, but deferred subsequent chemotherapy. Within 3 months, she became symptomatic again with vertigo, anorexia, and a decrease in her performance

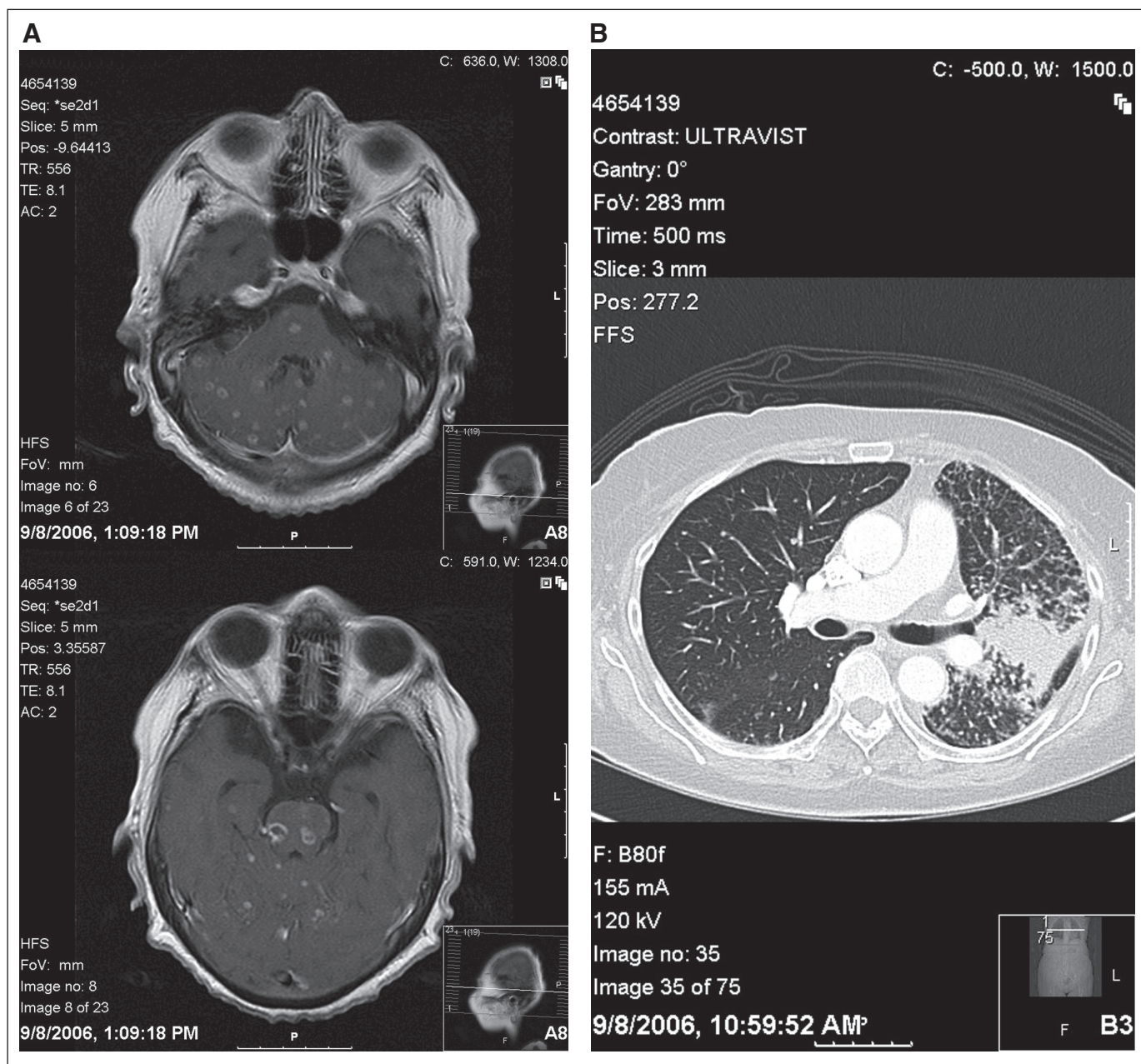


Fig 1.

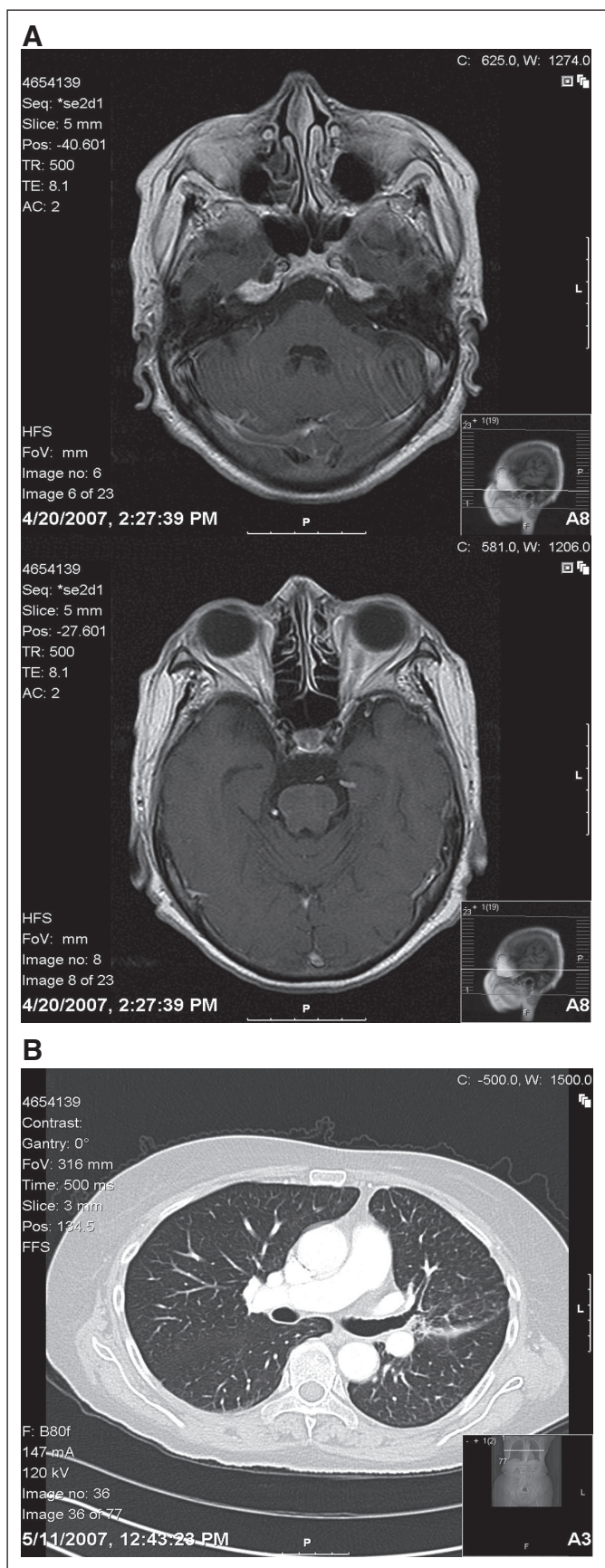


Fig 2.

status (PS). Magnetic resonance imaging (Fig 1A) revealed recurrent disease within the brain, and a computed tomography scan of the chest (Fig 1B) demonstrated progression of her disease. At this time the patient desired therapy but due to her poor PS (Karnofsky PS, 60) and comorbid disease, she was offered erlotinib 150 mg/d. Within the first month of therapy her symptoms resolved, and her Karnofsky PS improved to 90. A follow-up magnetic resonance imaging of the brain obtained after 8 months of erlotinib therapy (Fig 2A) demonstrated a complete resolution of the brain metastases, and a computed tomography scan of the chest obtained at that time revealed a partial remission of her primary disease (Fig 2B). She continues on erlotinib therapy at this time with only a minimal rash.

The development of brain metastases is usually associated with a poor outcome and shortened survival of 3 to 6 months; treatment is rarely curative. Such patients who receive standard platinum-based chemotherapy may respond to therapy, but these responses are often incomplete and of brief duration.<sup>1</sup> Gefitinib, an orally dosed tyrosine kinase inhibitor directed to the epidermal growth factor receptor, has previously demonstrated activity against brain metastases from NSCLC<sup>2,3</sup>; while it is structurally similar to erlotinib, there is no data demonstrating a survival benefit to gefitinib use, as there is with erlotinib. To date, there have only been two reports of responses of brain metastases from NSCLC in patients receiving erlotinib, although in one patient, the extracranial disease did not respond to erlotinib.<sup>4,5</sup> Because a significant number of patients with NSCLC develop brain metastases at some point in the course of their disease, the responses of such patients to epidermal growth factor receptor–targeted therapies are supportive of additional studies to further define the clinical benefit of erlotinib in this situation.

*M. Houman Fekrazad, Meera Ravindranathan, and  
Dennie V. Jones Jr*

Section of Thoracic Oncology, University of New Mexico Cancer Research and Treatment Center, Albuquerque, NM

© 2007 by American Society of Clinical Oncology

**AUTHORS' DISCLOSURES OF POTENTIAL CONFLICTS OF INTEREST**

Although all authors completed the disclosure declaration, the following author(s) indicated a financial or other interest that is relevant to the subject matter under consideration in this article. Certain relationships marked with a "U" are those for which no compensation was received; those relationships marked with a "C" were compensated. For a detailed description of the disclosure categories, or for more information about ASCO's conflict of interest policy, please refer to the Author Disclosure Declaration and the Disclosures of Potential Conflicts of Interest section in Information for Contributors.

**Employment or Leadership Position:** None **Consultant or Advisory Role:** Dennie V. Jones, Genentech Inc (C) **Stock Ownership:** None **Honoraria:** Meera Ravindranathan, Genentech; Dennie V. Jones, Genentech Inc **Research Funding:** Dennie V. Jones, Genentech Inc **Expert Testimony:** None **Other Remuneration:** None

**REFERENCES**

1. Postmus PE, Smit EF: Chemotherapy for brain metastases of lung cancer: A review. *Ann Oncol* 10:753-759, 1999
2. Hotta K, Kiura K, Ueoka H, et al: Effect of gefitinib ('Iressa', ZD1839) on brain metastases in patients with advanced non-small-cell lung cancer. *Lung Cancer* 46:255-261, 2004

3. Ceresoli GL, Cappuzzo F, Gregorc V, et al: Gefitinib in patients with brain metastases from non-small-cell lung cancer: A prospective trial. *Ann Oncol* 15:1042-1047, 2004

4. Lai CS, Boshoff C, Falzon M, Lee SM: Complete response to erlotinib treatment in brain metastases from recurrent NSCLC. *Thorax* 61:91, 2006

5. Popat S, Hughes S, Papadopoulos P, et al: Recurrent responses to non-small cell lung cancer brain metastases with erlotinib. *Lung Cancer* 56:135-137, 2007

DOI: 10.1200/JCO.2007.13.3751

## Metastatic Gastric Carcinoma in a 19-Year-Old Man

A 19-year-old marine was transferred from a military hospital with refractory shock and hypoxia. He had been well until 6 weeks before the transfer, when he began to have dry cough, febrile sense, lower back pain, and abdominal pain. He lost 15 kg over the following month. He was diagnosed with miliary tuberculosis on the basis of his symptoms and chest x-ray findings, and he received antituberculosis medication of isoniazid, rifampin, pyrazinamide, and ethambutol 7 days before the transfer. His dyspnea and weakness worsened despite medication, and his oxygen saturation was 90% while receiving oxygen supply via a facial mask (10 L/min), and systolic blood pressure dropped to 70 mmHg on the day of transfer. His abdomen was mildly distended without signs of peritoneal irritation. There were no palpable peripheral lymph nodes. The digital rectal examination was normal with no blood stains and irrigation of Levin tube revealed no signs of active bleeding. CBC revealed WBC of 20,680/mm<sup>3</sup> (69% neutrophils, 24% lymphocytes); hemoglobin of 5.4 g/dL; and platelets of 190,000/mm<sup>3</sup>. Serum lactate dehydrogenase level was 559U/L. Prothrombin time and activated partial thromboplastin time were prolonged, and D-dimer was elevated. Chest radiography revealed multiple miliary nodular opacities in the entire lung field (Fig 1A). A computed tomography scan, which was taken the day before transfer, showed multiple massive conglomerated lymph nodes in the bilateral hilar areas, anterior mediastinum, lesser curvature side of the stomach, left gastric, celiac trunk, and superior mesenteric arteries, small mesenteric root, aortocaval and para-aortic areas, and bilateral iliac chains (Fig 1B). The inferior vena cava was compressed by enlarged lymph nodes. Under the clinical impression of possible malignant lymphoma involving the abdominal lymph nodes and lungs, probably combined with bacterial sepsis, he was treated with empirical antibiotics, transfusion, intravenous dexamethasone, and mechanical ventilation. Despite transfusion of 27 pints of RBCs, together with platelet concentrates and fresh frozen plasma, his hemoglobin level was below 7 g/dL, and he showed rapidly progressive metabolic acidosis, disseminated intravascular coagulation, and refractory shock. He died 40 hours after admission. We performed an autopsy in order to uncover the cause of his death. On gross examination, we observed multiple conglomerated lymph nodes with extensive necrosis in the mediastinum and abdomen. There was an ulcerative lesion in the lesser curvature of upper body of the stomach, and a large amount of recent hematoma filled the lumen of the stomach and whole small intestine (Fig 2A). Microscopic examination revealed a 4.5 × 3.5 × 0.7 cm-sized poorly differentiated adenocarcinoma and a cancer invasion into the serosa (Fig 2B). There were disseminated metastatic adenocarcinomas in the lung parenchyma, peribronchial lymph nodes, bone marrow, and perirenal adipose tissue. By immunohistochemistry, cytokeratin and carcinoembryonic antigen were positive, and leukocyte common antigen was negative in the cancer cells (Figs 2C and 2D). No micro-organism was cultured in

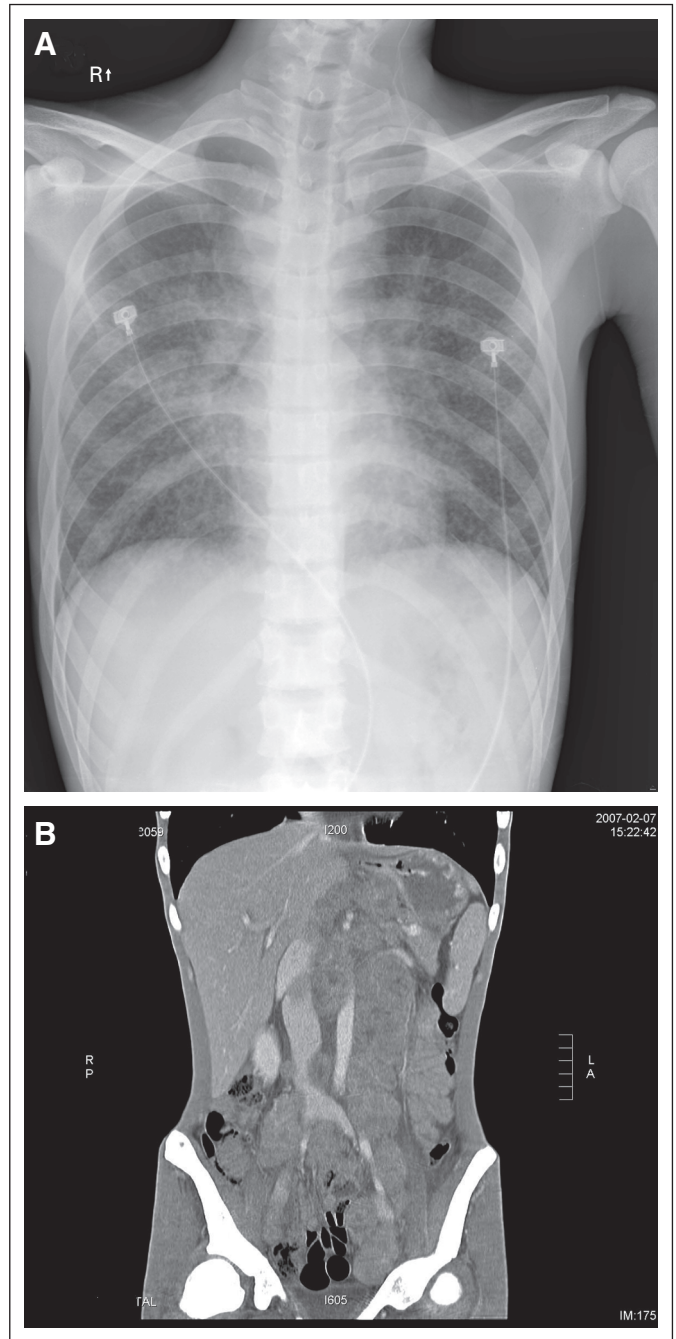


Fig 1.

blood and lung tissue specimens. Taken together, the cause of his death was advanced gastric carcinoma with multiple metastases, with the direct cause of death being multiorgan failure induced by massive gastrointestinal bleeding within 6 weeks of his initial presentation.