

# Usefulness and Limitations of Fluorine-18-Fluorodeoxyglucose Positron Emission Tomography for the Detection of Malignancy of Orbital Tumors

Junichi MIYAMOTO, Kazunori TATSUZAWA, Kei OWADA,  
Takuya KAWABE, Hiroyasu SASAJIMA, and Katsuyoshi MINEURA

Department of Neurosurgery, Kyoto Prefectural University Graduate School of Medicine, Kyoto

## Abstract

Fluorine-18-fluorodeoxyglucose positron emission tomography ( $^{18}\text{F}$ FDG PET) was assessed as a method for providing information about the malignancy of orbital tumors. Twelve patients with 13 orbital tumors underwent  $^{18}\text{F}$ FDG PET followed by biopsy or tumor removal via a transcranial approach. The accumulation ratio between the tumor and the contralateral normal tissue (T/N ratio) was calculated for 10 of the 13 lesions. The T/N ratio in benign lesions was compared with that in malignant tumors. Histological examination identified 7 lesions as malignant: anaplastic astrocytoma of the optic nerve in 1 patient, which recurred as glioblastoma of the optic nerve, malignant lymphoma of mucosa-associated lymphoid tissue type in 1 patient, malignant melanoma in 1 patient, adenoid cystic carcinoma in 2 patients, and adenocarcinoma (unknown origin) in 1 patient. The T/N ratio was  $1.06 \pm 0.03$  (mean  $\pm$  standard deviation) in benign tumors, and significantly higher at  $1.81 \pm 0.27$  in malignant tumors ( $p = 0.0027$ ). Both patterns of high and iso uptake of  $^{18}\text{F}$ FDG were found in orbital pseudotumor.  $^{18}\text{F}$ FDG PET can determine the malignancy of orbital tumors, but cannot distinguish malignant tumor from inflammatory disease such as pseudotumor.

Key words: orbital tumor, fluorine-18-fluorodeoxyglucose, positron emission tomography

## Introduction

Preoperative determination of the malignancy of orbital tumors may provide important indications about whether impaired visual acuity and residual visual acuity can be preserved, and intracranial advancement of the tumor prevented. Whole body fluorine-18-fluorodeoxyglucose positron emission tomography ( $^{18}\text{F}$ FDG PET) is useful to stage or monitor the disease in patients with malignant melanoma or malignant lymphoma.<sup>6,11,13-15</sup> This preliminary study investigated whether  $^{18}\text{F}$ FDG PET can provide significant information for preoperative decision making regarding the treatment of orbital tumors.

## Clinical Material and Methods

This study included 12 patients, 4 men and 8 women aged 17-72 years, with 13 orbital tumors (Table 1).

All patients had presented with some symptoms such as ocular pain, exophthalmos, progressive lump in the eyelid, or visual loss. Magnetic resonance (MR) imaging (Intera; Philips, Eindhoven, the Netherlands) had identified the orbital tumors. The patients subsequently underwent  $^{18}\text{F}$ FDG PET before surgery.

$^{18}\text{F}$ FDG PET was performed using a Headtome SET 120W (Shimadzu, Kyoto) to obtain five 12.5-mm thick slices with an in-plane resolution of 6.6 mm full width half-maximum, or a ECAT ACCEL (Siemens, Munich, Germany) to obtain 47 3.375-mm thick slices with an in-plane resolution of 6.2 mm full width half-maximum. Patients were intravenously injected with approximately 185 MBq (5 mCi) of  $^{18}\text{F}$ FDG, and transmission and emission scans were obtained after 40 minutes. The area of highest uptake of  $^{18}\text{F}$ FDG was enclosed within a region of interest. Circular regions of interest were placed manually referring to the corresponding MR image. The accumulation ratio between the tumor and contralateral normal tissue (T/N ratio) was cal-

**Table 1 Summary of the patients**

Case No.	Age (yrs)	Sex	Diagnosis	Symptoms	Size (cm)	[ <sup>18</sup> F]FDG uptake	T/N ratio	Surgery	Follow up (mos)	Outcome
1	56	F	adenoid cystic carcinoma	ocular pain	2	high	—	exenteration	29	PR
2	59	M	adenoid cystic carcinoma	exophthalmos	3	high	1.81	total	12	ST
3	69	F	adenocarcinoma	exophthalmos	4	high	1.84	exenteration	28	ST
4	51	M	anaplastic astrocytoma	exophthalmos	4	high	2.26	exenteration	24	death
			glioblastoma	exophthalmos	2	high	1.88	subtotal	24	death
5	64	F	malignant melanoma	loss of vision	2	high	1.43	exenteration	21	ST, liver metastasis
6	57	F	MALT lymphoma	exophthalmos	2	high	1.66	biopsy	10	death by other disease
7	17	F	fibrillary astrocytoma	loss of vision	2	iso	1.03	total	29	CR
8	35	M	cavernous angioma	exophthalmos	1.5	iso	1.10	total	20	CR
9	59	F	cavernous angioma	exophthalmos	3	iso	1.03	total	42	CR
10	72	F	neurinoma	exophthalmos	2	iso	1.08	total	53	CR
11	44	M	pseudotumor	loss of vision	2.5	iso	—	biopsy	44	PR
12	59	F	pseudotumor	lump in eyelid	2.5	high	—	partial	60	PG

CR: complete remission, exenteration: orbital exenteration, [<sup>18</sup>F]FDG: fluorine-18-fluorodeoxyglucose, MALT: mucosa-associated lymphoid tissue, partial: partial removal, PG: progressive disease, PR: partial remission, ST: stable disease, subtotal: subtotal removal, T/N ratio: tumor/normal ratio, total: total removal.

culated for 10 of the 13 lesions. The T/N ratio in benign tumors was compared with that in malignant tumors. The significance of differences was determined by Student's t test, and differences with  $p < 0.05$  were considered significant.

Biopsy or tumor removal was performed via a transcranial approach to remove the tumor or to confirm the histological diagnosis. The lesions suspected of malignancy based on preoperative [<sup>18</sup>F]FDG PET were expected to be removed as far as possible except for mucosa-associated lymphoid tissue (MALT) lymphoma. The lesions suspected to be benign were all symptomatic. The decision making regarding the range of removal depended on the intraoperative histological findings and the results of preoperative [<sup>18</sup>F]FDG PET. Diagnosis of all tumors was confirmed histologically. The follow-up period was 10–60 months (mean 30 months).

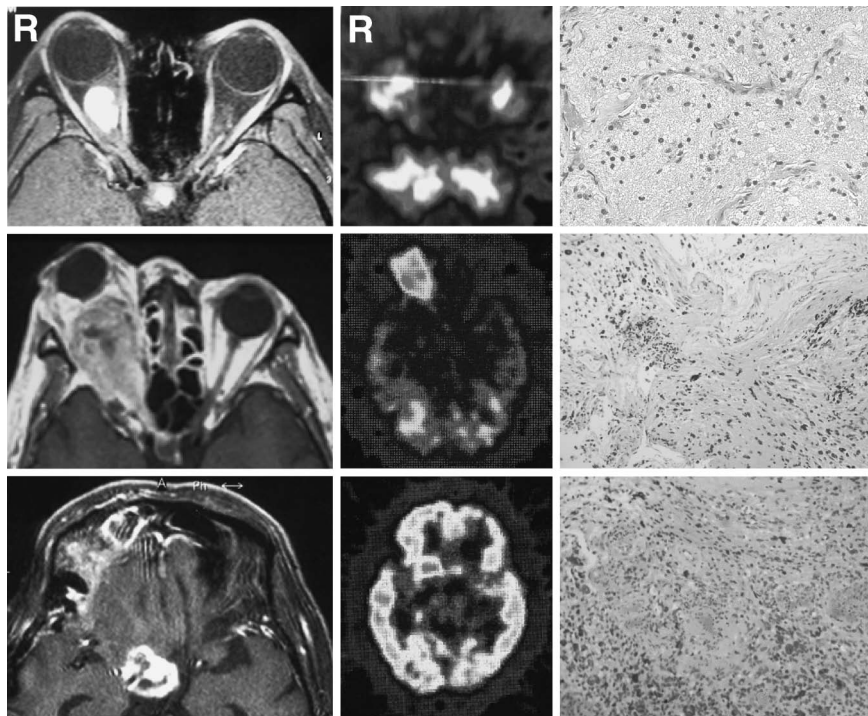
### Representative Cases

**Case 4:** A 51-year-old male presented with a 5-year history of progressive right exophthalmos and visual loss. MR imaging showed a right optic nerve tumor. [<sup>18</sup>F]FDG PET revealed high uptake of [<sup>18</sup>F]FDG in the lesion. The patient underwent tumor removal to relieve his exophthalmos, and adjuvant radiation therapy for the remaining tumor in the chiasm. The histological diagnosis was anaplastic astrocytoma

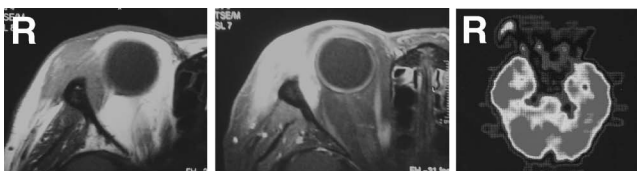
(Fig. 1 middle row). The tumor recurred as glioblastoma 6 months after the operation (Fig. 1 lower row). No [<sup>18</sup>F]FDG was accumulated in the remaining optic tract, so a second operation was performed to preserve the visual acuity of the remaining eye. Visual acuity remained stable for 1.5 years after the first operation, but the patient died after 2 years of liver dysfunction.<sup>10)</sup>

**Case 7:** A 17-year-old female presented with a 2-year history of progressive exophthalmos and visual loss. MR imaging showed a right optic nerve tumor with [<sup>18</sup>F]FDG accumulation similar to the normal side, indicating the lesion was benign. Therefore, the patient underwent tumor removal to relieve her exophthalmos after she lost useful visual acuity. The histological diagnosis was fibrillary astrocytoma (Fig. 1 upper row). She remained stable without tumor recurrence for 29 months after the operation.

**Case 12:** A 59-year-old female presented with a progressive lump in the right eyelid. MR imaging showed an intraorbital tumor with high [<sup>18</sup>F]FDG accumulation (Fig. 2). Tumor removal was planned through a transcranial approach, but the intraoperative histological findings indicated pseudotumor. Therefore, partial removal of the tumor was performed to relieve her symptoms, with postoperative administration of steroid agent. She showed frequent remissions and exacerbations during the postoperative 60 months.



**Fig. 1** Preoperative magnetic resonance (MR) images (left column; upper: fat suppression image, middle and lower: T<sub>1</sub>-weighted images with gadolinium), fluorine-18-fluorodeoxyglucose (<sup>18</sup>F)FDG positron emission tomography scans (center column), and photomicrographs (right column; hematoxylin and eosin stain, ×100) showing cases of fibrillary astrocytoma (Case 7, upper row), anaplastic astrocytoma (Case 4, middle row), and glioblastoma (Case 4, lower row) with a high level of [<sup>18</sup>F]FDG in anaplastic astrocytoma and glioblastoma, and similar level in fibrillary astrocytoma compared to the contralateral normal region. MR images in middle and lower rows are reprinted with permission from The Japan Neurosurgical Society.<sup>10)</sup>



**Fig. 2** Preoperative magnetic resonance images (left: T<sub>1</sub>-weighted image, center: fat suppression image with gadolinium) and fluorine-18-fluorodeoxyglucose positron emission tomography scan (right) showing the case of pseudotumor (Case 12).

## Results

Histological examination identified 7 lesions as malignant: anaplastic astrocytoma of the optic nerve in 1 patient, which recurred as glioblastoma of the optic nerve, malignant lymphoma of MALT type in 1 patient, malignant melanoma in 1 patient, adenoid cystic carcinoma in 2 patients, and adenocarcinoma

(unknown origin) in 1 patient. Six lesions were identified as benign: fibrillary astrocytoma in the optic nerve in 1 patient, cavernous angioma in 2 patients, neurinoma in 1 patient, and inflammatory pseudotumor in 2 patients.

The T/N ratio was  $1.06 \pm 0.03$  (mean  $\pm$  standard deviation,  $n = 4$ ) in benign tumors, and significantly higher at  $1.81 \pm 0.27$  ( $n = 6$ ) in malignant tumors ( $p = 0.0027$ ). The T/N ratio was 1.03 in fibrillary astrocytoma, 2.26 in anaplastic astrocytoma, and 1.88 in glioblastoma (Fig. 1).

## Discussion

This preliminary study demonstrated that accumulation of [<sup>18</sup>F]FDG in benign orbital tumors (fibrillary astrocytoma, cavernous angioma, neurinoma) was comparable to that in the contralateral normal tissue, whereas uptake of [<sup>18</sup>F]FDG was high in malignant orbital tumors (anaplastic astrocytoma, glioblastoma, MALT lymphoma, malignant melanoma, adenocarcinoma, adenoid cystic carcinoma) and

pseudotumor. [ $^{18}\text{F}$ ]FDG tends to accumulate in inflammatory diseases as well as malignant lesions.<sup>3,12</sup> Therefore, unexpectedly high uptake of [ $^{18}\text{F}$ ]FDG may indicate malignant or premalignant lesions.<sup>1</sup> Low grade lymphomas such as MALT lymphoma may also not accumulate [ $^{18}\text{F}$ ]FDG.<sup>12</sup> MALT lymphoma has also been reported to show increased [ $^{18}\text{F}$ ]FDG uptake.<sup>2,14</sup> Our findings indicated increased [ $^{18}\text{F}$ ]FDG uptake in orbital MALT lymphoma with T/N ratio of 1.66. However, [ $^{18}\text{F}$ ] FDG PET could not distinguish inflammatory lesion from malignant tumor.

[ $^{18}\text{F}$ ]FDG PET has several advantages for the detection of orbital tumor over conventional imaging such as computed tomography or MR imaging, including the ability to metabolically characterize tumors, early prediction of the response to chemotherapy, and evaluation of asymptomatic residual lesions.<sup>8</sup> On the other hand, current PET has low image resolution of 5 to 8 mm that may be too cumbersome to detect very small intraorbital tumors. Additionally, FDG PET may show a false negative in lesions with heterogeneous glucose consumption such as uveal melanoma or retinoblastoma.<sup>8</sup>

One of our patients with pseudotumor (Case 11) had received steroid agent for lymphocytic adenohypophysitis pointed out before. This patient showed equivalent [ $^{18}\text{F}$ ]FDG accumulation to the contralateral normal tissue, whereas the patient without preoperative administration of steroid agent (Case 12) showed high [ $^{18}\text{F}$ ]FDG accumulation. Steroid agent might have masked the clinical aggressiveness of the lesion. Therefore, [ $^{18}\text{F}$ ]FDG PET may reflect the clinical aggressiveness of the lesion.

Malignant glioma should be treated immediately to prevent development of the lesion whereas benign optic glioma needs careful consideration for surgical intervention. Surgical intervention for benign optic glioma, especially in young patient, is justified by blindness, posterior invasion, exophthalmos, and pituitary hypothalamus disturbance, because some tumors behave as non-neoplastic or self-limiting, and so have good prognosis.<sup>4,5,13</sup> Our patient with fibrillary astrocytoma presented with exophthalmos, and underwent surgery after she lost the visual acuity necessary for daily life. She had no evidence of neurofibromatosis type 1.  $^{11}\text{C}$ -methionine PET is a prognostic factor independent from [ $^{18}\text{F}$ ]FDG, and  $^{11}\text{C}$ -methionine uptake is correlated with cellular proliferation.<sup>9,11</sup>  $^{11}\text{C}$ -methionine is apparently superior to [ $^{18}\text{F}$ ]FDG for the detection of grade 3 glioma.<sup>7,8</sup> In this study, [ $^{18}\text{F}$ ]FDG PET could indicate the malignancy of orbital glioma, and provided important information about the timing of surgery or

the extent of the surgical removal. However, there was no correlation between the T/N ratio and the malignancy of optic glioma.

The present study involved a limited number of patients, so further research is required to more fully elucidate the usefulness of [ $^{18}\text{F}$ ]FDG PET in the treatment of the orbital tumors.

## Acknowledgments

This work was supported by Grants-in-Aid Nos. 12470296, 13470297, 13557121, 13877229, and 14370443 for Scientific Research from the Ministry of Education, Science, Sports and Culture, Japan.

The authors gratefully acknowledge the staff of the Cyclotron Unit, Nishijin Hospital, Kyoto for their cooperation.

## References

- 1) Agress H Jr, Cooper BZ: Detection of clinically unexpected malignant and premalignant tumors with whole-body FDG PET. Histopathologic comparison. *Radiology* 230: 417-422, 2003
- 2) Alinari L, Castellucci P, Elstrom R, Ambrosini V, Stefoni V, Nanni C, Berkowitz A, Tani M, Farsad M, Franchi R, Fanti S, Zinzani PL: 18F-FDG PET in mucosa-associated lymphoid tissue (MALT) lymphoma. *Leuk Lymphoma* 47: 2096-2101, 2006
- 3) Castellucci P, Zinzani P, Pourdehnad M, Alinari L, Nanni C, Farsad M, Battista G, Tani M, Stefoni V, Canini R, Monetti N, Rubello D, Alavi A, Franchi R, Fanti S: 18F-FDG PET in malignant lymphoma: significance of positive findings. *Eur J Nucl Med Mol Imaging* 32: 749-756, 2005
- 4) Defini R, Missori P, Tarantino R, Cippetta P, Cantore G: Primary benign tumors of the orbital cavity. Comparative data in a series of patients with optic nerve glioma, sheath meningioma, or neurinoma. *Surg Neurol* 45: 147-154, 1996
- 5) Dutton JJ: Gliomas of the anterior visual pathway. *Surv Ophthalmol* 38: 427-452, 1994
- 6) Holder WD Jr, White RL Jr, Zuger JH, Easton EJ Jr, Greene FL: Effectiveness of positron emission tomography for the detection of melanoma metastases. *Ann Surg* 227: 764-771, 1998
- 7) Kaschten B, Stevenaert A, Sadzot B, Deprez M, Deguelde C, Del Fiore G, Luxen A, Reznik M: Preoperative evaluation of 54 gliomas by PET with fluorine-18-fluorodeoxyglucose and/or carbon-11-methionine. *J Nucl Med* 39: 775-785, 1998
- 8) Katherine AL, Juri RB: Preliminary study of positron emission tomography in the detection and management of orbital malignancy. *Ophthalmol Plast Reconstr Surg* 22: 361-365, 2006
- 9) Kim S, Chung JK, Im SH, Jeong JM, Lee DS, Kim DG, Jung HW, Lee MC:  $^{11}\text{C}$ -methionine PET as a prognostic marker in patients with glioma: comparison

with 18F-FDG PET. *Eur J Nucl Med Mol Imaging* 32: 52-59, 2005

- 10) Miyamoto J, Sasajima H, Owada K, Mineura K: Surgical decision for adult optic glioma based on [<sup>18</sup>F]fluorodeoxyglucose positron emission tomography study. Case report. *Neurol Med Chir (Tokyo)* 46: 500-503, 2006
- 11) Nakamura H, Kuratsu J: [MRI & PET imaging in malignant brain tumors]. *No Shinkei Geka Journal* 15: 672-679, 2006 (Jpn, with Eng abstract)
- 12) O'Doherty MJ, Macdonald EA, Barrington SF, Mikhaeel NG, Schey S: Positron emission tomography in the management of lymphomas. *Clin Oncol (R Coll Radiol)* 14: 415-426, 2002
- 13) Parsa CF, Hoyt CS, Lesser RL, Weinstein JM, Strother CM, Muci-Mendoza R, Ramella M, Manor RS, Fletcher WA, Repka MX, Garrity JA, Ebner RN, Monteiro ML, McFadzean RM, Rubtsova IV, Hoyt WF: Spontaneous regression of optic gliomas: thirteen cases documented by serial neuroimaging. *Arch Ophthalmol* 119: 516-529, 2001
- 14) Roe RH, Finger PT, Kurli M, Tena LB, Iacob CE: Whole-body positron emission tomography/computed tomography imaging and staging of orbital lymphoma. *Ophthalmology* 113: 1854-1858, 2006
- 15) Steinert HC, Huch Boni RA, Buck A, Boni R, Berthold T, Marincek B, Burg G, von Schulthess GK: Malignant melanoma: staging with whole-body positron emission tomography and 2-[F-18]-fluoro-2-deoxy-D-glucose. *Radiology* 195: 705-709, 1995

---

Address reprint requests to: Junichi Miyamoto, M.D.,  
Department of Neurosurgery, Kyoto Prefectural University Graduate School of Medicine, Kawaramachi-Hirokoji, Kamigyo-ku, Kyoto 602-8566, Japan.  
e-mail: miyapoo850@yahoo.co.jp

### Commentary

This well documented paper illustrates the use of fluorine-18 FDG PET in orbital pathology. The authors describe their experience, making clear that this technique has both false positive and false negative errors. To my eyes, the false positive error (namely a positive fluorine-18 FDG PET for a pseudotumor) is particularly risky, and must be kept in mind. It means that the decision whether to operate or not on a particular orbital mass cannot be taken on the basis of this examination. Despite this, I think that fluorine-18 FDG PET can play a significant role in the management of orbital tumors, particularly for adjuvant postoperative treatment once the histological diagnosis has been achieved by surgical removal/biopsy. Clinical judgment and experience are still the basis of any surgical decision, and complementary examinations may only support it.

Alessandro DUCATI, M.D.  
Ordinario di Neurochirurgia  
Universita' di Torino  
Torino, Italy