

# NEUROLOGY

**Bevacizumab for recurrent malignant gliomas: Efficacy, toxicity, and patterns of recurrence**

A. D. Norden, G. S. Young, K. Setayesh, A. Muzikansky, R. Klufas, G. L. Ross, A. S. Ciampa, L. G. Ebbeling, B. Levy, J. Drappatz, S. Kesari and P. Y. Wen

*Neurology* 2008;70;779-787

DOI: 10.1212/01.wnl.0000304121.57857.38

**This information is current as of June 17, 2010**

The online version of this article, along with updated information and services, is located on the World Wide Web at:

<http://www.neurology.org/cgi/content/full/70/10/779>

*Neurology*® is the official journal of the American Academy of Neurology. Published continuously since 1951, it is now a weekly with 48 issues per year. Copyright © 2008 by AAN Enterprises, Inc. All rights reserved. Print ISSN: 0028-3878. Online ISSN: 1526-632X.



# Bevacizumab for recurrent malignant gliomas

## Efficacy, toxicity, and patterns of recurrence



A.D. Norden, MD\*  
G.S. Young, MD\*  
K. Setayesh, MA  
A. Muzikansky, MA  
R. Klufas, MD  
G.L. Ross, MD  
A.S. Ciampa, NP  
L.G. Ebbeling, BA  
B. Levy, BA  
J. Drappatz, MD  
S. Kesari, MD, PhD  
P.Y. Wen, MD

Address correspondence and reprint requests to Dr. A.D. Norden, Dana-Farber/Brigham and Women's Cancer Center and Harvard Medical School, SW430B, 44 Binney St., Boston, MA 02115  
anorden@partners.org

### ABSTRACT

**Background:** Bevacizumab, a humanized monoclonal antibody against vascular endothelial growth factor, may have activity in recurrent malignant gliomas. At recurrence some patients appear to develop nonenhancing infiltrating disease rather than enhancing tumor.

**Methods:** We retrospectively reviewed 55 consecutive patients with recurrent malignant gliomas who received bevacizumab and chemotherapy to determine efficacy, toxicity, and patterns of recurrence. Using a blinded, standardized imaging review and quantitative volumetric analysis, the recurrence patterns of patients treated with bevacizumab were compared to recurrence patterns of 19 patients treated with chemotherapy alone.

**Results:** A total of 2.3% of patients had a complete response, 31.8% partial response, 29.5% minimal response, and 29.5% had stable disease. Median time to radiographic progression was 19.3 weeks. Six-month progression-free survival (PFS) was 42% for patients with glioblastoma and 32% for patients with anaplastic glioma. In 23 patients who progressed on their initial therapy, bevacizumab was continued and the concurrent chemotherapy agent changed. In no case did the change produce a radiographic response, but two patients had prolonged PFS of 20 and 31 weeks. Recurrence pattern analysis identified a significant increase in the volume of infiltrative tumor relative to enhancing tumor in bevacizumab responders.

**Conclusions:** Combination therapy with bevacizumab and chemotherapy is well-tolerated and active against recurrent malignant gliomas. At recurrence, continuing bevacizumab and changing the chemotherapy agent provided long-term disease control only in a small subset of patients. Bevacizumab may alter the recurrence pattern of malignant gliomas by suppressing enhancing tumor recurrence more effectively than it suppresses nonenhancing, infiltrative tumor growth.

**Neurology**® 2008;70:779-787

### GLOSSARY

**AA** = anaplastic astrocytoma; **AG** = anaplastic glioma; **CR** = complete response; **GBM** = glioblastoma; **EIAED** = enzyme-inducing antiepileptic drug; **FLAIR** = fluid-attenuated inversion recovery; **KPS** = Karnofsky Performance Status; **MR** = minimal response; **PFS** = progression-free survival; **PR** = partial response; **rFPR** = relative FLAIR progression ratio; **rNTR** = relative nonenhancing tumor ratio; **T1W** = T1-weighted; **VEGF** = vascular endothelial growth factor.

Despite recent therapeutic advances, malignant gliomas are associated with a strikingly poor prognosis. Median survival is 14.6 months among patients with newly diagnosed glioblastoma (GBM) who receive optimal therapy with surgery, radiation, and chemotherapy.<sup>1</sup> For patients with anaplastic astrocytoma (AA), median survival is in the range of 2 to 3 years.<sup>2,3</sup> Recurrent malignant glioma confers a dismal prognosis, with median survival of 25 weeks for patients with GBM and 47 weeks for patients with AA. Less than 15% of recurrent tumors show a radiographic response to chemotherapy, and the 6-month progression-free survival (6M-PFS) for GBM is only 15 to 21%.<sup>4</sup> There is a clear need for more effective therapies.

\*These authors contributed equally to this work.

From the Division of Cancer Neurology (A.D.N., A.S.C., L.G.E., B.L., J.D., S.K., P.Y.W.), Department of Neurology, Brigham and Women's Hospital and Center For Neuro-Oncology, Dana-Farber/Brigham and Women's Cancer Center and Harvard Medical School; Brigham and Women's Hospital Department of Radiology and Harvard Medical School (G.S.Y., K.S., R.K., G.L.R.); and Massachusetts General Hospital Biostatistics Center (A.M.), Boston.

Supported by the Amos E. Wasgatt Brain Tumor Research Fund.

**Disclosure:** P.Y. Wen receives research support from Genentech, Inc. The other authors report no conflicts of interest.

As the molecular pathogenesis of malignant gliomas is elucidated, novel therapeutic targets are emerging. Vascular endothelial growth factor (VEGF) is a critical mediator of new blood vessel formation, or angiogenesis, within gliomas.<sup>5,6</sup> Robust angiogenesis is required for the growth of many human cancers,<sup>7,8</sup> including malignant gliomas.<sup>9</sup> VEGF secreted by glioma cells acts by paracrine mechanisms upon endothelial cells in the vicinity of the tumor, resulting in endothelial cell proliferation, survival, and migration.<sup>10</sup> The level of VEGF expression in gliomas correlates with blood vessel density, degree of malignancy, and prognosis.<sup>11,12</sup>

Bevacizumab is a humanized monoclonal antibody against VEGF that has proven efficacy against metastatic colon cancer<sup>13</sup> and nonsmall cell lung cancer<sup>14</sup> when administered in conjunction with traditional chemotherapeutics. The published experience with bevacizumab and chemotherapy for recurrent malignant gliomas is encouraging, with radiographic response rates of at least 50%<sup>15-17</sup> and median PFS of 24 weeks.<sup>17</sup> In the first reported cohort of 29 patients with recurrent malignant gliomas treated with bevacizumab and irinotecan, there were 3 complete responses (CRs) and 16 partial responses (PRs).<sup>15</sup> Among 14 evaluable patients treated with bevacizumab and a variety of chemotherapeutic agents, 7 PRs and 3 patients with stable disease were observed.<sup>16</sup> More recently, 32 patients treated with bevacizumab and irinotecan had an overall response rate of 63%.<sup>18</sup> 6M-PFS was 30% for patients with GBM and 56% for patients with anaplastic glioma (AG). This compares favorably with the results from the MD Anderson database of 8 negative trials in which the 6M-PFS for GBM was 15% and 31% for AG.<sup>4</sup> There is also evidence that VEGF receptor inhibitors may have activity.<sup>19</sup> In a recent phase II study of the pan-VEGF receptor inhibitor AZD2171 in recurrent GBMs, the radiographic response rate was approximately 50%, and 6M-PFS was 27%.<sup>19,20</sup>

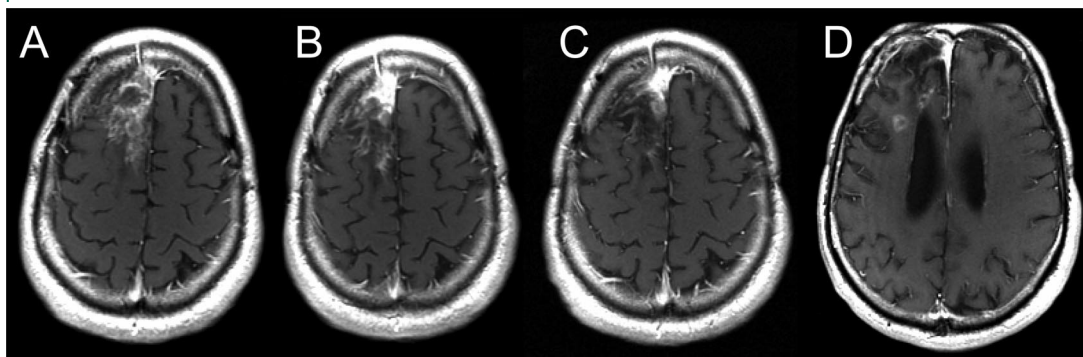
In our initial experience treating patients with malignant glioma with bevacizumab,

a larger than expected number of patients developed diffuse infiltrating disease at the time of tumor progression. This appeared as diffuse hyperintensity on T2-weighted fluid-attenuated inversion recovery (FLAIR) MRI sequences, rather than abnormal gadolinium enhancement. Since recurrence within 2 to 4 cm of the tumor margin is observed in the majority of patients treated with radiation and cytotoxic chemotherapy,<sup>21,22</sup> we hypothesized that bevacizumab treatment effectively controls local tumor growth but either fails to control or actually promotes distant and diffuse recurrences. A plausible mechanism for this hypothesis comes from animal model data which suggest that VEGF-induced angiogenesis blockade facilitates co-option of the normal vasculature and tumor invasion.<sup>23,24</sup>

We sought to confirm the subjective impression of increased infiltrative disease using volumetric MRI measurements. If bevacizumab treatment promotes diffuse tumor infiltration, bevacizumab-treated patients with recurrent malignant gliomas should have larger volumes of FLAIR hyperintense, non-enhancing tumor than control patients treated with cytotoxic chemotherapy alone. Since bevacizumab appears to control local tumor growth, bevacizumab-treated patients would be expected to have smaller volumes of local enhancing tumor compared with controls. In addition, if increased infiltrative disease is a result of the anti-angiogenic effect of bevacizumab, nonenhancing tumor infiltration should be even more apparent in patients with bevacizumab who respond to treatment than nonresponders. To test these hypotheses, we reviewed our experience with bevacizumab in combination with conventional chemotherapy for heavily pretreated patients with recurrent malignant gliomas. We designed a blinded, standardized imaging review to allow an unbiased comparison of recurrence patterns in bevacizumab-treated patients to patients treated with traditional cytotoxic chemotherapy alone.

**METHODS** We performed a retrospective chart review of 55 consecutive patients with histologic diagnoses of malignant gliomas who were treated with bevacizumab (Avastin)

**Figure 1** Distant recurrence in a patient with recurrent malignant glioma treated with bevacizumab and irinotecan



Post-gadolinium T1-weighted MRI scan before treatment with bevacizumab and irinotecan (A). After 4 weeks of treatment, there is reduction in the intensity of enhancement (B). After 5 months of treatment, the intensity and size of enhancement has reduced sufficiently to achieve a partial response (C). After 7 months of treatment, a new area of enhancement inferior to the original tumor has appeared, consistent with a distant recurrence (D).

and a conventional chemotherapy agent between June 2005 and March 2007. All patients had prior treatment with radiotherapy and temozolomide, and most with at least one additional chemotherapeutic. There was no limit on the number of prior therapies. Except for one patient who received 5 mg/kg, patients received bevacizumab 10 mg/kg every 2 weeks. A total of 47 patients received irinotecan (125 mg/m<sup>2</sup> every 2 weeks for patients not on enzyme-inducing antiepileptic drugs [EIAEDs] and 340 mg/m<sup>2</sup> every 2 weeks for patients on EIAEDs), 6 patients received carboplatin (AUC of 5–6), one patient received carmustine (200 mg/m<sup>2</sup> every 6 weeks), and one patient received temozolomide (150 to 200 mg/m<sup>2</sup> for 5 days every 4 weeks). Adverse events were graded based on the Common Terminology Criteria for Adverse Events v3.0. The Kaplan-Meier method was used to estimate survival functions, and statistical comparisons between groups were evaluated with the log-rank test.

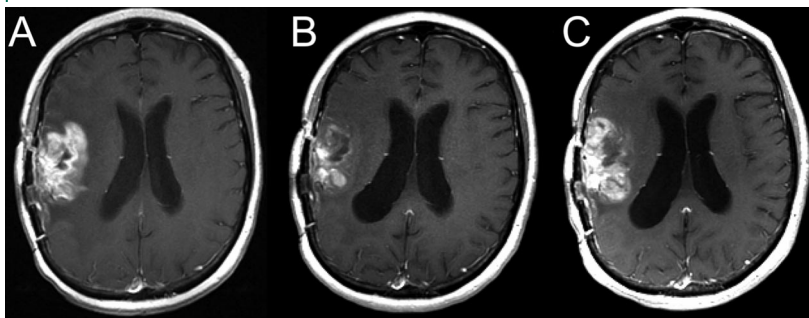
To determine the pattern of recurrence in patients treated with conventional cytotoxic chemotherapy, we evaluated 19 patients enrolled in three phase II clinical trials of cytotoxic chemotherapy for recurrent malignant gliomas. Control patients were selected on the basis of available MRI scan data, as described below. Seven patients were enrolled in a phase II trial of temozolomide (150 mg/m<sup>2</sup>/day for 5 days every 4 weeks) and irinotecan (200 mg/m<sup>2</sup> every 2 weeks for patients not on EIAEDs and 500 mg/m<sup>2</sup> for patients on EIAEDs) (North American Brain Tumor Consortium protocol 99-07). Eleven patients were enrolled in a phase II trial of gimatecan (1 mg/m<sup>2</sup>/day for 5 days every 4 weeks) (Dana-Farber Cancer Institute protocol 05-291). One patient was enrolled in a phase II trial of edotecarin (13 to 15 mg/m<sup>2</sup> every 3 weeks) (Dana-Farber Cancer Institute protocol 03-205).

Subjects were included in the imaging analysis if acceptable digital MRI data could be retrieved for scans performed within 2 weeks prior to initiating therapy and at least every 8 weeks thereafter until progression. Interpretable FLAIR and post-gadolinium T1-weighted (T1W) sequences were required for each time point. By these criteria, 44 bevacizumab-treated patients were included and 11 patients were excluded. In 26 cases, T1W and FLAIR images were reviewed independently by three neuroradiologists to detect evidence of distant tumor recurrence and to qualitatively assess interval changes and recurrence patterns. The neurora-

diologists were blind to patient identity, scan date, and treatment. In 18 cases, scans were reviewed by one author. Using a standard approach, the largest cross-sectional and perpendicular diameters of enhancing tumor on each gadolinium-enhanced T1W image were measured. These measurements were multiplied to determine the largest cross-sectional tumor area. In order to quantitatively assess diffuse tumor recurrence, similar measurements of nonenhancing tumor were made on FLAIR sequences. Radiographic response was defined by the Macdonald Criteria, in which CR represents complete disappearance of all measurable disease, PR represents a 50% or greater decrease in largest cross-sectional tumor area, and progressive disease represents a 25% or greater increase in largest cross-sectional tumor area or appearance of a new lesion.<sup>25</sup> We defined minimal response (MR) as a 25 to 49% decrease in largest cross-sectional tumor area. All other conditions were classified as stable disease. Stability or improvement on FLAIR sequences was required for classification as a response (CR, PR, or MR). Additionally, a subject must have been taking the same or decreased dose of corticosteroids and have had a stable or improved neurologic examination. When progressive disease was detected, scans were classified on the basis of recurrence pattern. Scans found to have new foci of enhancement distant from the original area of enhancing tumor were classified as distant recurrence (figure 1). When increased enhancement developed in contiguity with the original tumor mass, the scan was classified as local recurrence (figure 2). If the local tumor mass remained stable but there was at least a 25% increase in area of abnormal FLAIR hyperintensity, the scan was classified as diffuse recurrence (figure 3). The significance of the difference in recurrence patterns between control and bevacizumab-treated patients was evaluated using Fisher exact test.

In addition, quantitative volumetric analysis using offline post-processing software (ITK-Snap) was performed under the supervision of the principal neuroradiologist by manually segmenting areas of abnormal enhancement and FLAIR hyperintensity. Cystic and necrotic portions of tumor were excluded, and regions of heterogeneous enhancement considered likely to be tumor were included in the segmentation volumes. Total volumes were calculated by multiplying voxel size by the number of pixels in the segmented region of

**Figure 2** Local recurrence in a patient with recurrent malignant glioma treated with bevacizumab and irinotecan

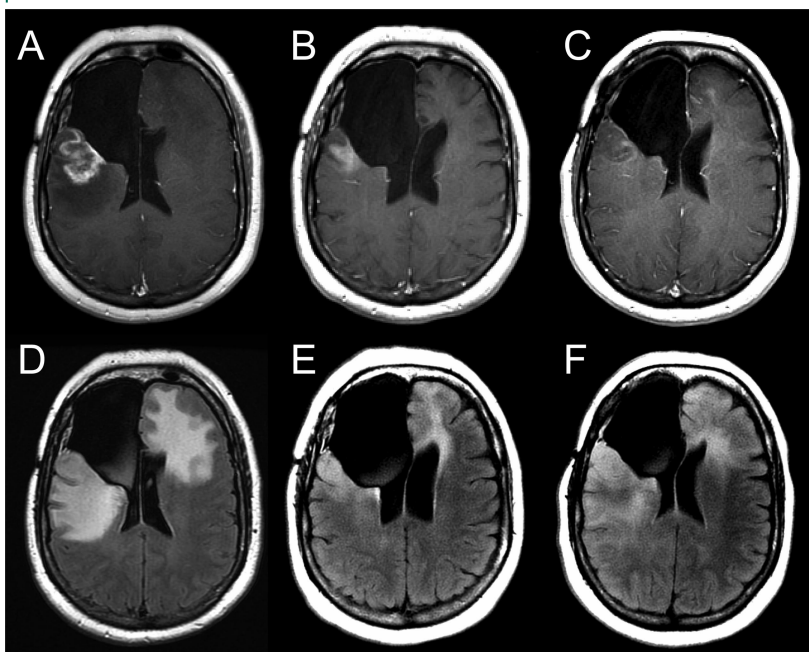


Post-gadolinium T1-weighted MRI scan before treatment with bevacizumab and irinotecan (A). After 4 weeks of treatment, there is reduction in the size and intensity of enhancement sufficient to achieve a minor response (B). After 5 months of treatment, the size and intensity of enhancement at the location of the original abnormality has increased substantially, consistent with a local recurrence (C).

interest using MRicro and MATLAB software to produce estimates of total volume of abnormal enhancement and FLAIR hyperintensity.

In order to quantitatively assess the hypothesis that bevacizumab alters the pattern of recurrence, we calculated a relative nonenhancing tumor ratio (rNTR), defined as the ratio of the volume of abnormal FLAIR hyperintensity (infiltrative tumor) to the volume of abnormal gadolinium enhancement for each patient in the control and bevacizumab groups. rNTR calculations were based on the progression MRI available for each patient.

**Figure 3** Diffuse recurrence in a patient with recurrent malignant glioma treated with bevacizumab and irinotecan



Post-gadolinium T1-weighted (A) and FLAIR (D) MRI scans before treatment with bevacizumab and irinotecan. After 6 weeks of treatment, there is reduction in the size and intensity of enhancement sufficient to achieve a partial response (B). Abnormal FLAIR hyperintensity is proportionately reduced (E). After 6 months of treatment with bevacizumab and irinotecan, there has been further reduction in enhancement (C), yet the extent of abnormal FLAIR hyperintensity has increased markedly, suggesting nonenhancing tumor infiltration (F).

We also calculated a relative FLAIR progression ratio (rFPR), defined as the ratio of the volume of abnormal FLAIR hyperintensity at the time of progression to the volume of abnormal FLAIR hyperintensity on the baseline study. Wilcoxon two-sample tests were used to evaluate the significance of rNTR and rFPR differences between the following patient groups, as defined by consensus interpretations using Macdonald Criteria: bevacizumab responders, bevacizumab nonresponders, control responders, and control nonresponders. Single-tailed tests were used because the chief study hypothesis predicted the direction of rNTR and rFPR differences.

**RESULTS Patient population.** We studied 55 patients (32 men, 23 women) (table 1). Thirty-three had GBM, 21 had AG, and 1 had a high-grade glioma. Median age was 50 years (range 23 to 71), and median Karnofsky Performance Status (KPS) was 80 (range 50 to 100). The median number of prior chemotherapy treatments was 2 (range 0 to 6). Fourteen patients had prior therapy with anti-angiogenic agents including thalidomide, lenalidomide, imatinib, enzastaurin, sorafenib, or AZD2171. Median follow-up time was 27.6 weeks.

**Response assessment.** One patient (2.3%) achieved CR. A total of 31.8% of patients achieved PR and 29.5% MR. A total of 29.5% had stable disease. Only 3 patients (6.8%) had progressive disease at the first follow-up MRI. The median time to radiographic progression was 19.3 weeks. Overall 6M-PFS was 39% and 6M-OS 65%. Median PFS was 23.9 weeks (95% CI: 17.7, 28.3 weeks) and median OS 35.7 weeks (95% CI: 27.7, 61.4 weeks). For GBM patients, 6M-PFS was 42% and for AG patients 32% ( $p = 0.81$ ). Among patients who achieved radiographic response, 6M-PFS was 52%. For nonresponders, 6M-PFS was 19% ( $p = 0.11$ ). Patients who had been previously treated with anti-angiogenic therapies had a 6M-PFS of 40%, while patients who had received only cytotoxic chemotherapy had a 6M-PFS of 39% ( $p = 0.89$ ). With bevacizumab treatment, steroid dose decreased in 33% of patients, remained stable in 53%, and increased in 14%.

**Treatment at progression.** In 23 patients who progressed on their initial therapy, bevacizumab was continued and the concurrent chemotherapy agent changed. In 17 cases, irinotecan was changed to carboplatin. In one case each, irinotecan was changed to etoposide, lomustine, or carmustine. Carboplatin was changed to erlotinib in one case and to etoposide in another. In a single case, carmustine was changed to irinotecan. In seven cases, the chemotherapy agent was changed

<b>Table 1</b> Patient characteristics	
Characteristics	No. (%) of patients (n = 55)
Age, y	
Median	50
Range	23-71
Sex	
Male	32 (58)
Female	23 (42)
Histology	
Glioblastoma	33 (60)
Anaplastic glioma	21 (38)
High-grade glioma*	1 (2)
Primary or secondary†	
Primary	45 (82)
Secondary	10 (18)
Karnofsky score	
Median	80
Range	50-100
No. of relapses	
Median	2
Range	0-7
No. of prior regimens‡	
Median	2
Range	0-6
Concurrent chemotherapy	
Irinotecan	47 (85)
Carboplatin§	5 (9)
Carboplatin + erlotinib	1 (2)
Carmustine	1 (2)
Temozolomide	1 (2)
Prior anti-angiogenic agents	
Yes	14 (25)
No	41 (75)

\*This tumor could not be further characterized on histopathologic grounds.

†Primary tumors were thought to have arisen de novo, whereas secondary tumors were known to have evolved from lower grade tumors.

‡Radiotherapy with concurrent temozolomide did not count as a prior regimen.

§One patient had an allergic reaction after months of therapy that required a change from carboplatin to etoposide.

a second time, and in two cases, a third time. Third and fourth line chemotherapy options included carmustine, lomustine, carboplatin, etoposide, temozolomide, and erlotinib with either carboplatin or sirolimus. In no case did the change from one chemotherapy agent to another produce a radiographic response. Among the 23 patients whose chemotherapy was changed while the patients remained on bevacizumab, the median

time to radiographic progression was only 7 weeks. However, in 2 cases, patients achieved prolonged clinical stability after a change in the chemotherapy agent. One patient who was changed from irinotecan to carboplatin and then temozolomide was stable for 31 weeks from the time of the first chemotherapy change. Another patient who was changed from irinotecan to carmustine and then carboplatin was stable for 20 weeks. In both cases, chemotherapy was changed because the clinician detected possible radiographic progression at the point of care. On quantitative review, no radiographic progression had occurred.

**Anticoagulation and bevacizumab.** Eleven patients received anticoagulation during treatment with bevacizumab for venous thromboembolic disease. Most patients received low-molecular weight heparin. One patient who developed heparin-induced thrombocytopenia received fondaparinux, and one patient who had a pulmonary embolism before initiating bevacizumab therapy received warfarin. Apart from one patient who had epistaxis, no bleeding was observed among the anticoagulated patients.

**Toxicity.** Common adverse effects such as bone marrow suppression and nausea were attributable to the concurrently administered chemotherapy agent rather than to bevacizumab (table 2). Fatigue was frequently reported as well. Nine patients experienced hemorrhage, and all of these events were Grade 1 or 2, primarily epistaxis or other mucosal bleeding. Two patients developed asymptomatic brain hemorrhages that were detected on routine neuroimaging. One patient experienced spontaneous Grade 4 colon perforation that necessitated emergent surgery. Grade 1 proteinuria was detected in a single patient. Five Grade 3 or 4 thromboembolic complications occurred. Four patients were found to have pulmonary emboli, and one developed a superior mesenteric vein thrombosis. There were two cases of impaired craniotomy wound healing.

**Progression patterns.** Blind reading and Macdonald Criteria measurements of 26 bevacizumab-treated patients demonstrated 16 local recurrences, 4 diffuse recurrences, and 4 distant recurrences (table 3). The remaining 2 patients did not have radiographic evidence of progression at the time of publication. Among the 19 control patients, 13 experienced local recurrence, 3 diffuse, and one distant. Two patients did not experience radiographic progression. The likelihood of diffuse or distant recurrence was higher in bevacizumab-

Category	Adverse effect	Grade	No. of patients (n = 55)
Cardiovascular	Hypertension	1	4
		2	1
Gastrointestinal	Colon perforation	4	1
Hemorrhage	Brain hemorrhage	1	2
		2	1
	Oral cavity bleeding	1	1
		Vaginal bleeding	1
Renal	Proteinuria	1	1
Vascular	Phlebitis	2	1
	Deep venous thrombosis*	3	1
	Pulmonary embolism	4	4
Other	Impaired wound healing	2	1

\*Superior mesenteric vein thrombosis.

treated patients than in controls (31% vs 21%,  $p = 0.48$ ). The majority of diffuse or distant recurrences in bevacizumab-treated patients (6/8, 75%) occurred in subjects who achieved at least a minor radiographic response.

**Volumetric analysis.** The average rNTR was higher in the bevacizumab group than the control group (5.3 vs 4.7,  $p = 0.10$ ). The rNTR was also higher among bevacizumab responders than bevacizumab nonresponders (7.1 vs 2.4,  $p = 0.02$ ; figure 4) and higher among bevacizumab responders than conventional chemotherapy responders (7.1 vs 3.5,  $p = 0.48$ ). A small subgroup (3 of 26) of the bevacizumab responders had strikingly elevated rNTR of greater than 20 (23.8, 22.1,  $\infty$ ). A single control patient had an rNTR greater than 10 (18.3), but no conventional chemotherapy patient or bevacizumab nonresponder had an rNTR greater than 20. rFPR values were similar for the bevacizumab and control groups (1.9 vs 2.1,  $p = 0.43$ ) and for bevacizumab responders and nonresponders (1.8 vs 1.9,  $p = 0.08$ ).

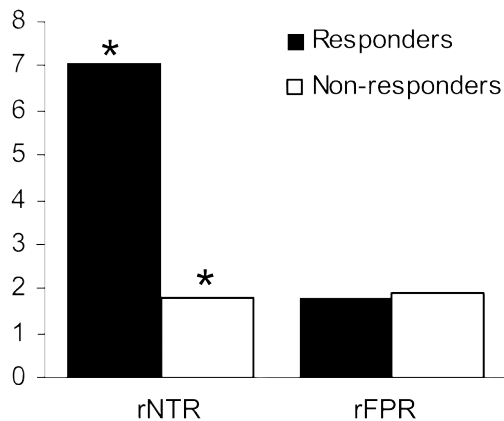
Recurrence pattern	No. of bevacizumab-treated patients (%) (n = 26)	No. of control patients (%) (n = 19)
Local	16 (62)	13 (68)
Diffuse	4 (15)	3 (16)
Distant	4 (15)	1 (5)
No progression	2 (8)	2 (11)

**DISCUSSION** These data confirm that combination therapy with bevacizumab and chemotherapy is active against recurrent malignant gliomas, even in the setting of extensive pretreatment. Because the prognosis associated with recurrent malignant gliomas is exceedingly poor, a treatment that produces disease stabilization may provide substantial benefit. We found a radiographic response rate of 34.1% (CR + PR) and a radiographic disease control rate (CR + PR + MR + stable disease) of 93.2%. This compares favorably to historical data from 375 patients with recurrent malignant gliomas enrolled in phase II clinical trials in which radiographic response rate was 14% and the radiographic disease control rate was 39%.<sup>4</sup> The patients in this study were heavily pretreated (median of 2 prior therapies; range 0 to 6), and 14 patients had received previous treatment with anti-angiogenic therapies. Additionally, patients had a KPS score as low as 50, which would have excluded them from most malignant glioma clinical trials. Despite these factors, our data are comparable to results from a recent phase II clinical trial of bevacizumab with irinotecan chemotherapy for recurrent malignant glioma which found a radiographic response rate of 63% and 6M-PFS of 38%.<sup>18</sup>

At recurrence, continuing bevacizumab and changing the chemotherapy agent provided long-term disease control only in 2 patients (9.5%) who remained progression-free for 20 to 31 weeks. In these patients, however, the PFS was longer than is typically observed in patients with recurrent malignant gliomas. This suggests a possible synergistic effect between chemotherapy and bevacizumab that may be specific to the chemotherapy agent. At present, the optimal chemotherapy agent to combine with bevacizumab is unclear. A recently completed multicenter randomized phase II trial of bevacizumab with or without irinotecan for recurrent malignant gliomas will determine whether the combination is more effective than bevacizumab alone.

Overall, bevacizumab therapy was well-tolerated. Most side effects were attributable to the concurrently administered chemotherapy agent. The extent to which bevacizumab contributed to fatigue is difficult to determine because fatigue is common among patients with malignant gliomas. Despite concerns about serious or life-threatening bleeding in patients treated with bevacizumab,<sup>26</sup> we observed only minor hemorrhages. Two patients experienced asymptomatic intratumoral hemorrhages that were detected on routine MRI scans. Bleeding was not problematic

**Figure 4** Relative nonenhancing tumor ratio (rNTR) and relative fluid-attenuated inversion recovery (FLAIR) progression ratio (rFPR) for bevacizumab-treated patients



rNTR, defined as the ratio of the volume of abnormal FLAIR hyperintensity to the volume of abnormal gadolinium enhancement, is greater among radiographic responders than nonresponders (\* $p = 0.02$ ). rFPR, defined as the ratio of the abnormal FLAIR hyperintensity volume at the time of progression to the abnormal FLAIR hyperintensity volume on the baseline MRI, does not differ based on radiographic response.

among 11 patients who received anticoagulant medications, which suggests that such medications may be used safely in patients with malignant gliomas during bevacizumab therapy. Five thromboembolic complications occurred during therapy. Because patients with malignant gliomas are at high risk for thromboembolism regardless of therapy,<sup>27</sup> the additional risk conferred by bevacizumab is unclear.

An important advantage of bevacizumab may be its ability to decrease peritumoral edema and function as a corticosteroid-sparing agent. In this study, 33% of patients had reduction in their steroid dose after receiving bevacizumab, potentially reducing steroid-related complications. Our findings are consistent with the results of a recent phase II trial of AZD2171, an oral pan VEGF receptor tyrosine kinase inhibitor, for recurrent GBM. AZD2171 treatment resulted in a rapid and sustained anti-edema effect that was associated with reduced steroid dose in 11 of 11 patients.<sup>19</sup>

Preclinical data suggest that glioma cells may co-opt existing cerebral vasculature as an alternative to angiogenesis.<sup>6</sup> This mechanism appears to be particularly important when VEGF-mediated angiogenesis is blocked. In a murine model, treatment with the VEGF receptor antibody DC101 promoted satellite tumor formation with invasion along cerebral blood vessels.<sup>23</sup> Similar findings have been observed in rat gliomas treated with an

anti-VEGF antibody.<sup>24</sup> If this phenomenon occurs in humans, it could represent an important limitation to anti-angiogenic therapy.<sup>28</sup> In patients who have been treated with bevacizumab and chemotherapy, we have observed cases in which the volume and intensity of contrast enhancement remain nearly stable while the volume and degree of abnormal FLAIR hyperintensity increase substantially (figure 3). In this study we were unable to demonstrate a significant difference in the pattern of recurrence between bevacizumab-treated and control patients, although there was a trend toward more diffuse or distant recurrences in the bevacizumab group, particularly among subjects who achieved at least a minor radiographic response. The failure to detect a difference in recurrence patterns between the two groups may be due in part to the relatively small number of patients in this study. In addition, abnormal FLAIR hyperintensity may reflect not only infiltrating tumor, but also peritumoral edema.<sup>29</sup> Since bevacizumab reduces peritumoral edema, abnormal FLAIR hyperintensity in the bevacizumab-treated group may primarily reflect infiltrating tumor, while abnormal FLAIR hyperintensity in the chemotherapy-treated group likely reflects a combination of infiltrating tumor and peritumoral edema. This phenomenon may have reduced the difference in abnormal FLAIR hyperintensity between the groups. Definitive differentiation between infiltrating tumor, edema, gliosis, and other causes of abnormal FLAIR hyperintensity such as treatment-related leukoencephalopathy in bevacizumab-treated patients will require histopathologic analysis that may only be possible in an autopsy study. However, because increased abnormal FLAIR hyperintensity after bevacizumab treatment is often associated with clinical worsening that is not highly steroid-responsive, it most likely reflects infiltrating tumor. It is also possible that the addition of chemotherapy to the bevacizumab-treated group may have reduced the extent of tumor infiltration. The difference between the two groups may have been more evident if bevacizumab alone was used in the treatment group.

A quantitative volumetric analysis was used to calculate rNTR and rFPR for patients in both groups. Although there was not a significant difference between rNTR values for all bevacizumab-treated and control patients, a trend toward increased rNTR in bevacizumab-treated patients was detected. This suggests that there may be a greater relative volume of nonenhancing tumor in bevacizumab-treated patients. Intriguingly, the

rNTR was significantly greater in bevacizumab responders than nonresponders, and there was a trend toward elevated rNTR in bevacizumab responders compared to control responders.

The observation that rNTR is higher among bevacizumab responders than nonresponders or control responders raises the possibility that bevacizumab's pro-invasion effect is directly related to its anti-angiogenic effect. The absence of a measurable difference in the rFPR data between bevacizumab responders and nonresponders implies that nonenhancing, infiltrative tumor progresses at a similar rate in the two groups. Therefore, the difference in rNTR between the bevacizumab responders and nonresponders is likely due to differences in the volume of abnormal gadolinium enhancement (ratio denominator). Taken together, our results suggest that the apparent promotion of diffuse recurrence by bevacizumab therapy represents a combination of increased suppression of local enhancing tumor recurrence with decreased suppression of nonenhancing, infiltrative tumor progression. An alternative explanation is that bevacizumab therapy results in a significant reduction in tumor capillary permeability without producing a true anti-tumor effect. By this mechanism, enhancing tumor on MRI scans could be converted into nonenhancing tumor, thus giving the false impression of increased infiltrative tumor.  $K^{\text{trans}}$  is a surrogate marker of vascular permeability that can be obtained from dynamic contrast-enhanced MRI. In a recent study, AZD2171 treatment resulted in prolonged  $K^{\text{trans}}$  suppression.<sup>19</sup> Though anti-angiogenic therapies produce dramatic radiographic changes in malignant glioma patients, a definitive demonstration of potent anti-tumor efficacy remains to be published. Larger, prospective studies are needed to address this issue.

It is intriguing that a small number of bevacizumab responders (3/16, 18.8%) had markedly elevated rNTR, substantially greater than other patients in the study. These patients may be members of a distinct subgroup of patients with malignant glioma who are at high risk for nonenhancing tumor progression during anti-angiogenic therapy. Correlation with tumor genotypes may identify a molecular substrate that explains this observation. Such correlations are critically important in that they may elucidate novel therapeutic targets and suggest genotypic subgroups that warrant anti-invasion or other specific therapies.

Our study was limited by small patient numbers and by its retrospective nature. Additionally, some of the patients had received previous anti-

angiogenic therapy. This may have reduced the likelihood of detecting increased invasion during bevacizumab therapy since tumor cells in these patients may have assumed a maximally invasive phenotype prior to initiation of bevacizumab. Even without previous exposure to anti-angiogenic therapy, gliomas become increasingly infiltrative with more advanced stages of disease.<sup>30</sup> In addition, segmentation of nonenhancing signal abnormality on FLAIR MRI sequences is challenging because the distinction between normal brain tissue and areas of abnormal FLAIR hyperintensity may be subtle, and threshold and window-level selection are subjective. Since scans were reviewed in a blinded fashion that eliminates any systematic bias, this seems unlikely to account for our results. The failure to detect a significant difference between all patients treated with bevacizumab and all patients treated with conventional chemotherapy is likely due to small sample size with dilution of the effect observed in responders by inclusion of nonresponders. A larger, prospective volumetric MRI study of progression patterns with histopathologic correlation in bevacizumab-treated patients with malignant gliomas is indicated.

Received July 2, 2007. Accepted in final form September 18, 2007.

## REFERENCES

1. Stupp R, Mason WP, van den Bent MJ, et al. Radiotherapy plus concomitant and adjuvant temozolomide for glioblastoma. *N Engl J Med* 2005;352:987–996.
2. Curran WJ, Jr., Scott CB, Horton J, et al. Recursive partitioning analysis of prognostic factors in three Radiation Therapy Oncology Group malignant glioma trials. *J Natl Cancer Inst* 1993;85:704–710.
3. Prados MD, Seiferheld W, Sandler HM, et al. Phase III randomized study of radiotherapy plus procarbazine, lomustine, and vincristine with or without BUdR for treatment of anaplastic astrocytoma: final report of RTOG 9404. *Int J Radiat Oncol Biol Phys* 2004;58:1147–1152.
4. Wong ET, Hess KR, Gleason MJ, et al. Outcomes and prognostic factors in recurrent glioma patients enrolled onto phase II clinical trials. *J Clin Oncol* 1999;17:2572–2578.
5. Shweiki D, Itin A, Soffer D, Keshet E. Vascular endothelial growth factor induced by hypoxia may mediate hypoxia-initiated angiogenesis. *Nature* 1992;359:843–845.
6. Holash J, Maisonpierre PC, Compton D, et al. Vessel cooption, regression, and growth in tumors mediated by angiopoietins and VEGF. *Science* 1999;284:1994–1998.
7. Folkman J. Tumor angiogenesis: therapeutic implications. *N Engl J Med* 1971;285:1182–1186.
8. Folkman J. Angiogenesis *Annu Rev Med* 2006;57:1–18.

9. Purow B, Fine HA. Antiangiogenic therapy for primary and metastatic brain tumors. *Hematol Oncol Clin North Am* 2004;18:1161–1181.
10. Millauer B, Shawver LK, Plate KH, Risau W, Ullrich A. Glioblastoma growth inhibited in vivo by a dominant-negative Flk-1 mutant. *Nature* 1994;367:576–579.
11. Chaudhry IH, O'Donovan DG, Brenchley PE, Reid H, Roberts IS. Vascular endothelial growth factor expression correlates with tumour grade and vascularity in gliomas. *Histopathology* 2001;39:409–415.
12. Zhou YH, Tan F, Hess KR, Yung WK. The expression of PAX6, PTEN, vascular endothelial growth factor, and epidermal growth factor receptor in gliomas: relationship to tumor grade and survival *Clin Cancer Res* 2003;9:3369–3375.
13. Hurwitz H, Fehrenbacher L, Novotny W, et al. Bevacizumab plus irinotecan, fluorouracil, and leucovorin for metastatic colorectal cancer. *N Engl J Med* 2004;350:2335–2342.
14. Sandler A, Gray R, Perry MC, et al. Paclitaxel-carboplatin alone or with bevacizumab for nonsmall-cell lung cancer. *N Engl J Med* 2006;355:2542–2550.
15. Stark Vance V. Bevacizumab (Avastin®) and CPT-11 (Camptosar®) in the Treatment of Relapsed Malignant Glioma. *Neuro-oncol* 2005;7:369.
16. Pope WB, Lai A, Nghiemphu P, Mischel P, Cloughesy TF. MRI in patients with high-grade gliomas treated with bevacizumab and chemotherapy. *Neurology* 2006;66:1258–1260.
17. Vredenburgh JJ, Desjardins A, Herndon JE, et al. Bevacizumab, a monoclonal antibody to vascular endothelial growth factor (VEGF), and irinotecan for treatment of malignant gliomas. *J Clin Oncol* 2006;24:1506.
18. Vredenburgh JJ, Desjardins A, Herndon JE, 2nd, et al. Phase II trial of bevacizumab and irinotecan in recurrent malignant glioma. *Clin Cancer Res* 2007;13:1253–1259.
19. Batchelor TT, Sorensen AG, di Tomaso E, et al. AZD2171, a pan-VEGF receptor tyrosine kinase inhibitor, normalizes tumor vasculature and alleviates edema in glioblastoma patients. *Cancer Cell* 2007;11:83–95.
20. Batchelor T, Sorensen AG, Ancukiewicz M, et al. A phase II trial of AZD2171 (cediranib), an oral pan-VEGF receptor tyrosine kinase inhibitor, in patients with recurrent glioblastoma. *J Clin Oncol* 2007;25:2001.
21. Gaspar LE, Fisher BJ, Macdonald DR, et al. Supratentorial malignant glioma: patterns of recurrence and implications for external beam local treatment. *Int J Radiat Oncol Biol Phys* 1992;24:55–57.
22. Hochberg FH, Pruitt A. Assumptions in the radiotherapy of glioblastoma. *Neurology* 1980;30:907–911.
23. Kunkel P, Ulbricht U, Bohlen P, et al. Inhibition of glioma angiogenesis and growth in vivo by systemic treatment with a monoclonal antibody against vascular endothelial growth factor receptor-2. *Cancer Res* 2001;61:6624–6628.
24. Rubenstein JL, Kim J, Ozawa T, et al. Anti-VEGF antibody treatment of glioblastoma prolongs survival but results in increased vascular cooption. *Neoplasia* 2000;2:306–314.
25. Macdonald DR, Cascino TL, Schold SC, Jr., Cairncross JG. Response criteria for phase II studies of supratentorial malignant glioma. *J Clin Oncol* 1990;8:1277–1280.
26. Gordon MS, Margolin K, Talpaz M, et al. Phase I safety and pharmacokinetic study of recombinant human anti-vascular endothelial growth factor in patients with advanced cancer. *J Clin Oncol* 2001;19:843–850.
27. Marras LC, Geerts WH, Perry JR. The risk of venous thromboembolism is increased throughout the course of malignant glioma: an evidence-based review. *Cancer* 2000;89:640–646.
28. Lamszus K, Kunkel P, Westphal M. Invasion as limitation to anti-angiogenic glioma therapy. *Acta Neurochir Suppl* 2003;88:169–177.
29. Kelly PJ, Dumas-Duport C, Kispert DB, Kall BA, Scheithauer BW, Illig JJ. Imaging-based stereotaxic serial biopsies in untreated intracranial glial neoplasms. *J Neurosurg* 1987;66:865–874.
30. Giese A, Bjerkvig R, Berens ME, Westphal M. Cost of migration: invasion of malignant gliomas and implications for treatment. *J Clin Oncol* 2003;21:1624–1636.

**Bevacizumab for recurrent malignant gliomas: Efficacy, toxicity, and patterns of recurrence**

A. D. Norden, G. S. Young, K. Setayesh, A. Muzikansky, R. Klufas, G. L. Ross, A. S. Ciampa, L. G. Ebbeling, B. Levy, J. Drappatz, S. Kesari and P. Y. Wen  
*Neurology* 2008;70;779-787

DOI: 10.1212/01.wnl.0000304121.57857.38

**This information is current as of June 17, 2010**

<b>Updated Information &amp; Services</b>	including high-resolution figures, can be found at: <a href="http://www.neurology.org/cgi/content/full/70/10/779">http://www.neurology.org/cgi/content/full/70/10/779</a>
<b>Subspecialty Collections</b>	This article, along with others on similar topics, appears in the following collection(s): <b>MRI</b> <a href="http://www.neurology.org/cgi/collection/mri">http://www.neurology.org/cgi/collection/mri</a> <b>Volumetric MRI</b> <a href="http://www.neurology.org/cgi/collection/volumetric_mri">http://www.neurology.org/cgi/collection/volumetric_mri</a> <b>Primary brain tumor</b> <a href="http://www.neurology.org/cgi/collection/primary_brain_tumor">http://www.neurology.org/cgi/collection/primary_brain_tumor</a> <b>Chemotherapy-tumor</b> <a href="http://www.neurology.org/cgi/collection/chemotherapytumor">http://www.neurology.org/cgi/collection/chemotherapytumor</a>
<b>Permissions &amp; Licensing</b>	Information about reproducing this article in parts (figures, tables) or in its entirety can be found online at: <a href="http://www.neurology.org/misc/Permissions.shtml">http://www.neurology.org/misc/Permissions.shtml</a>
<b>Reprints</b>	Information about ordering reprints can be found online: <a href="http://www.neurology.org/misc/reprints.shtml">http://www.neurology.org/misc/reprints.shtml</a>

