

Treatment and Prognosis of Brain Metastases From Gynecological Cancers

Kazuhiko OGAWA, Yoshihiko YOSHII*, Yoichi AOKI**, Yutaka NAGAI**,
Yukihiro TSUCHIDA*, Takafumi TOITA, Yasumasa KAKINOHANA,
Wakana TAMAKI, Shiro IRAHA, Genki ADACHI, Makoto HIRAKAWA**,
Kazuya KAMIYAMA**, Morihiko INAMINE**,
Akio HYODO*, and Sadayuki MURAYAMA

Departments of Radiology, *Neurosurgery, and **Obstetrics and Gynecology,
University of the Ryukyus School of Medicine, Okinawa

Abstract

Brain metastases from gynecological cancers were retrospectively investigated in 18 patients who were treated between 1985 and 2006. Six patients received surgical resection followed by radiotherapy, and 12 patients received only radiotherapy. The median survival for all patients was 4.1 months (range 0.7–48.2 months), and the actuarial survival rates were 11% at both 12 months and 24 months. Univariate analysis showed that treatment modality, extracranial disease status, total radiation dose, number of brain metastases, and Karnofsky performance status (KPS) all had statistically significant impacts on survival. Two patients survived for more than 2 years, and both had single brain metastasis, inactive extracranial disease, 90–100% KPS, and were treated with surgical resection followed by radiotherapy. Improvements in neurological symptoms were observed in 10 of the 12 patients treated with palliative radiotherapy, with median duration of 3.1 months (range 1.5–4.5 months). The prognoses for patients with brain metastases from gynecological cancers were generally poor, although selected patients may survive longer with intensive brain tumor treatment. Palliative radiotherapy was effective in improving the quality of the remaining life for patients with unfavorable prognoses.

Key words: radiation therapy, brain metastasis, gynecological neoplasm, uterine cervical cancer, endometrial cancer, ovarian cancer

Introduction

Brain metastases develop in approximately 10–30% of cancer patients and the prognoses of these patients have historically been poor. The most common primary tumors responsible for brain metastases are lung, breast, and unknown primary tumors, and melanoma.⁴¹⁾ In contrast, brain metastases originating from gynecological malignancies are extremely rare, with the exception of choriocarcinoma, and the incidence of brain metastases in clinical series for all gynecological cancers is approximately 1%.^{36,41)}

Recently, advances in neuroimaging, such as computed tomography (CT) and magnetic resonance (MR) imaging, have allowed careful monitoring of cancer patients, which together with the increased

survival of patients, has led to more frequent and earlier detection of brain metastases. Therefore, clinical reports of brain metastases from gynecological cancers have increased gradually.^{19,32)}

The present study evaluated our experience with brain metastases from gynecological cancers to identify the treatments and factors that influence the prognosis of these patients.

Materials and Methods

A retrospective review of the medical records of 2729 patients with gynecological cancer treated at the University of the Ryukyus Hospital between 1985 and 2006 identified 18 patients (0.7%) with documented brain metastases from gynecological cancers. The brain metastases were diagnosed by CT with contrast medium or, more recently, CT and/or MR imaging. Six of the 18 patients had histo-

logical confirmation of the diagnosis after undergoing surgical resection of the brain lesion. All patients underwent primary medical evaluation including detailed history, review of symptoms, and physical examination before a treatment plan was formulated, and follow-up information was obtained from the patients' records or from communications with the patients or their physicians.

Six of the 18 patients were treated with surgical resection followed by radiotherapy (S + RT group), and the remaining 12 patients were treated with radiotherapy (RT group). Radiotherapy used a 4-MV, 6-MV, or 10-MV linear accelerator to administer daily fractions of 2–3 Gy 5 days per week. Stereotactic radiosurgery was not applied. Fifteen patients received whole brain radiotherapy (WBRT) of 5–50 Gy (median dose 30 Gy), and three patients received WBRT (40 Gy in 20 fractions) followed by local boost using the appropriate technique (dose range 50–60 Gy). The doses were 30–60 Gy (median 50 Gy) for the S + RT group and 5–50 Gy (median 30 Gy) for the RT group. Corticosteroids in individualized doses were given during radiotherapy. Three patients then received systemic chemotherapy using cisplatin with or without 5-fluorouracil or a combination of adriamycin and cyclophosphamide.

In this study, statistical analysis examined the following potential prognostic factors affecting survival: age (<65 years or ≥65 years), Karnofsky performance status (KPS; ≥70% or <70%), primary histology (squamous cell carcinoma or others), initial International Federation of Gynecology and Obstetrics (FIGO) stage, extracranial disease status (active or inactive), number of brain metastases (single or multiple), greatest dimension of brain metastases (<4 cm or ≥4 cm), interval between diagnosis of primary tumor and brain metastases (<2 years or ≥2 years), treatment modality for brain metastases (S + RT or RT), total radiation dose (<50 Gy or ≥50 Gy), primary tumor site (ovary or others), and use of

chemotherapy (yes or no). Patients were considered to have no evidence of active extracranial disease if there were no metastases outside the brain and the primary tumor was controlled. The term *controlled primary tumor* referred to a primary tumor in complete remission after surgical resection, radical radiotherapy/radiochemotherapy, or a combination of these treatments.

A recursive partitioning analysis (RPA) of three Radiation Therapy Oncology Group (RTOG) studies used the following classification: Class 1, patients with KPS ≥70, age <65 years with controlled primary disease and no evidence of extracranial metastases; Class 3, patients with KPS <70; and Class 2, all remaining patients who did not fit into Class 1 or 3.¹⁴⁾ To ascertain whether this scoring system is also applicable to patients with brain metastases from gynecological cancers, our patients were grouped into these three classes for analysis.

All data were updated to December 2006. Overall survival rate was calculated according to the Kaplan-Meier method¹⁸⁾ and survival was measured from the date of diagnosis of brain metastases until the date of last follow up or until death. Differences between groups were estimated using the log-rank test.²⁷⁾ A probability level of 0.05 was chosen for statistical significance. Statistical analysis was performed using the SPSS software package (version 11.0; SPSS Inc., Chicago, Ill., U.S.A.).

Results

Table 1 indicates the incidence rates of brain metastases from gynecological cancers according to the primary tumor site. In total, 0.7% of the patients with gynecological malignancies treated in our institutions developed brain metastases. The incidence of brain metastases from ovarian cancer (2.1%) was higher than those from other primaries (0.4–0.7%).

The patients were aged 38–74 years (median 53

Table 1 Incidences and median survival of patients with brain metastases (BM) from gynecological cancers

Primary site	Previous reports			Current study		
	Reference No.	Incidences of BM (%)	Median survivals (mos)	Patients with BM/total patients	Incidence of BM (%)	Median survival (range) (mos)
Ovary	4, 10–19	0.3–2.2	1.3–19.5	7/335	2.1	7.3 (0.9–48.2)
Uterine cervix	20–24	0.4–1.2	3.0–7.8	7/1716	0.4	2.8 (0.7–28.4)
Uterine corpus	25–30	0.3–0.9	1.0–5.3	4/556	0.7	4.3 (3.1–4.9)
All sites included*	31	1.8	7.3	18/2729	0.7	4.1 (0.7–48.2)

*Other sites include vagina, vulva, and fallopian tube.

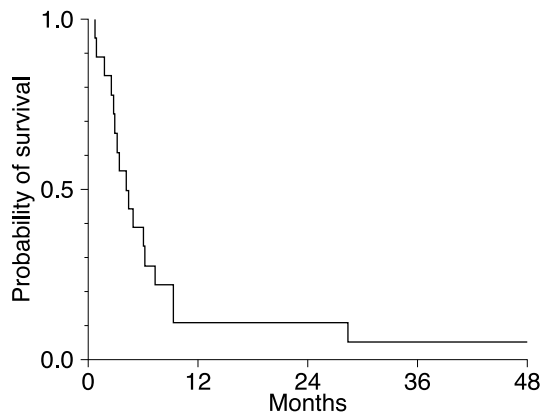


Fig. 1 Actuarial overall survival curves for the 18 patients with brain metastases from gynecological cancers.

years) at the time of initial diagnosis of gynecological cancers. All patients had histologic confirmation of their primary lesion. Seven patients had squamous cell carcinoma, and 11 had adenocarcinoma. At the time of initial primary treatment, 11 patients had clinical FIGO stage I-II tumors, and seven had stage III-IV tumors.

The patients were aged 42–74 years (median 55 years) at the time brain metastases appeared, and KPS was 30–100% (median 60%). The signs and symptoms were headache in eight patients, motor weakness in seven, seizures in two, and cerebellar dysfunction, disorientation, speech disturbance, and diplopia in one each. All patients underwent chest radiography, chest CT, and abdominal CT. Sixteen of the 18 patients underwent radionuclide bone scintigraphy. Extracranial disease status was active in 14 patients; three had recurrent extracranial metastases, and 11 had both uncontrolled primary tumor and extracranial metastases. The interval between the diagnoses of primary tumor and appearance of brain metastases was 0–78 months (median 16 months). Five patients had single brain metastasis, and six had brain metastases with largest dimension ≥ 4 cm.

The median survival was 4.1 months (range 0.7–48.2 months). The actuarial overall survival rates were 11% at both 12 months and 24 months (Fig. 1). The median survival was 9.3 months (range 4.9–48.2 months) for patients in the S + RT group and 2.9 months (range 0.7–6.2 months) for patients in the RT group. Univariate analysis showed that treatment modality, KPS, extracranial disease status, number of brain metastases, and total radiation dose all had statistically significant impacts on sur-

Table 2 Univariate analysis of various potential prognostic factors for survival in patients with brain metastases (BM) from gynecological cancers

Variable	No. of patients	Overall survival at 1 yr	p Value
Treatment modality			
S + RT	6	33	0.0005
RT	12	0	
Extracranial disease			
active	14	0	0.0011
inactive	4	25	
Total radiation dose			
< 50 Gy	14	0	0.013
≥ 50 Gy	4	50	
No. of BM			
single	5	40	0.019
multiple	13	0	
KPS			
< 70%	10	0	0.021
$\geq 70%$	8	25	
Primary tumor site			
ovary	7	14	0.065
others	11	9	
Primary tumor histology			
squamous cell carcinoma	7	14	0.25
adenocarcinoma	11	9	
Age			
< 65 yrs	12	17	0.29
≥ 65 yrs	6	0	
Use of chemotherapy			
yes	3	27	0.40
no	15	7	
Initial FIGO stage			
stages I-II	11	9	0.42
stages III-IV	7	14	
Interval from primary Dx to BM Dx			
< 2 yrs	12	8	0.60
≥ 2 yrs	6	17	
Greatest dimension of BM			
< 4 cm	12	8	0.83
≥ 4 cm	6	17	

Dx: diagnosis, FIGO: International Federation of Gynecology and Obstetrics, KPS: Karnofsky performance status, RT: radiotherapy, S: surgery.

vival (Table 2). No significant differences in survival were seen with respect to other factors.

Two patients survived for more than 2 years. Both patients had single brain metastasis, inactive extracranial disease, 90–100% KPS, and were treated with S + RT. No late complications, such as mental deterioration, were observed during follow up in either patient. One patient died of recurrent brain metastasis after 48.2 months, and the other patient died of recurrent extracranial metastasis after 28.4 months.

The median survival was 22.4 months for the three patients in RPA class I, 4.9 months for the six patients in RPA class II, and 2.8 months for the nine patients in RPA class III. There were statistically significant differences in survival between these groups ($p = 0.001$).

Ten of the 12 patients treated with palliative radiotherapy showed improvements in neurological symptoms, including headache, motor weakness, seizures, and cerebellar dysfunction, with duration of 1.5–4.5 months (median 3.1 months). Six of these 12 patients died of brain metastases accompanied by deterioration of neurological symptoms, and the other six patients died of pneumonia without deterioration of neurological symptoms.

Discussion

In the current study, 0.7% of the patients with gynecological cancers treated in our institutions developed brain metastases. The incidence of brain metastases from ovarian cancer (2.1%) was higher than those from other primaries (0.4–0.7%). This is consistent with other studies with the reported rates of 0.3–2.2% for ovarian cancer and 0.6–0.9% for other cancers.^{1,6–13,16,17,19–21,23–26,31,34,35,37,38} Clearly, brain metastases from gynecological malignancies are rare, but recent reports suggest an increasing incidence of brain metastases, especially in patients with ovarian cancer.^{19,32} The use of effective combination chemotherapy, especially regimens containing cisplatin for ovarian cancer, may increase survival, providing time for occult brain metastases to become overt. Another explanation for the possible increase in brain metastases is the availability of better imaging techniques for diagnosis.³² Further studies are required to monitor whether incidence rates among these patients will continue to increase in the future.

The primary mechanism of spread to the brain is dissemination to the lungs, then to the brain via the pulmonary vasculature.⁴¹ Brain metastases from gynecological cancers are usually found in association with widely disseminated disease.^{1,19,29,31} Our study found that 14 of 18 patients had active extracranial diseases at diagnosis of brain metastases. These results indicate that patients with brain metastases usually have disseminated systemic diseases at the time of clinical appearance of brain metastases.

Brain metastases are a major detrimental event in the natural history of most malignancies. In the majority of patients, the treatment of brain metastases is a palliative measure, because the primary disease is often advanced, and the general condition of these patients often is poor. Despite numerous

studies designed to improve treatment outcome, the median survival is only 3–6 months.^{4,33,41} In the present study, the median survival was 4.1 months, and actuarial survival was 11% at both 12 months and 24 months. Therefore, our results also indicated that the prognoses of patients with brain metastases from gynecological cancers were generally poor, like those from non-gynecological sites.

Achieving local tumor control in the brain is now known to improve the survival of selected patients. Two randomized trials that excluded patients with multiple brain metastases showed that surgical resection plus radiotherapy was significantly better than only radiotherapy.^{30,39} Stereotactic radiosurgery also provided local control equivalent to surgery and facilitated the treatment of patients with surgically inaccessible or multiple lesions.^{2,5} In our study, both patients who survived for more than 2 years were treated with S + RT. Both patients had inactive extracranial disease, and also had KPS of 90–100%. The median survival for the three patients in RPA class I (all treated with S + RT) was 22.4 months, which was comparable with the 14.8 months in the previous S + RT study.³ The median survival of 4.9 months for the six patients in RPA class II (2 treated with S + RT) and that of 2.8 months for the nine patients in class III (1 treated with S + RT) were comparable with the 3.8–4.2 months and 2.3 months, respectively, in the previous studies.^{14,15} Brain metastases from ovarian cancer are responsive to chemotherapy.^{28,40} Therefore, multimodal treatments may provide better results in selected patients who may profit from effective local tumor control in the brain, than in all patients with brain metastases from gynecological cancers.

The present study also indicated that for patients with unfavorable prognoses, palliative radiotherapy was effective in improving the quality of remaining life, as in patients with other primaries. WBRT is effective for the palliation of symptoms resulting from intracranial metastases.²² The result of the first two RTOG metastatic brain studies, which mainly incorporated patients with metastatic lung and breast cancer, suggested that the administration of WBRT could improve neurologic function in 50% of patients, and 70% to 80% of patients spent their remaining lives in an improved or stable neurologic state.⁴ Symptomatic response was obtained in 23 of 32 patients with brain metastases from ovarian cancer.¹¹ All of 15 ovarian cancer patients with brain metastases who received radiotherapy showed improvement in neurological symptoms.³⁴ The present study, which included ovarian cancer, uterine cervical cancer, and uterine corpus cancer, observed improvements of neurological function in 10 of 18

patients after treatment.

The present study indicates that the prognoses for patients with brain metastases from gynecological cancers are generally poor, although selected patients may survive longer with intensive brain tumor treatment. Palliative radiotherapy is recommended for patients with unfavorable prognoses. However, this retrospective study included a relatively small number of patients, so further studies are necessary to confirm our results.

References

- 1) Aalders JG, Abeler V, Kolstad P: Recurrent adenocarcinoma of the endometrium: a clinical and histopathological study of 379 patients. *Gynecol Oncol* 17: 85-103, 1984
- 2) Adler JR, Cox RS, Kaplan I, Martin DP: Stereotactic radiosurgical treatment of brain metastases. *J Neurosurg* 76: 444-449, 1992
- 3) Agboola O, Benoit B, Cross P, Da Silva V, Esche B, Lesiuk H, Gonsalves C: Prognostic factors derived from recursive partition analysis (RPA) of Radiation Therapy Oncology Group (RTOG) brain metastases trials applied to surgically resected and irradiated brain metastatic cases. *Int J Radiat Oncol Biol Phys* 42: 155-159, 1998
- 4) Borgelt B, Gelber R, Kramer S, Brady LW, Chang CH, Davis LW, Perez CA, Hendrickson FR: The palliation of brain metastases: final results of the first two studies by the Radiation Therapy Oncology Group. *Int J Radiat Oncol Biol Phys* 6: 1-9, 1980
- 5) Breneman JC, Warnick RE, Albright RE Jr, Kukiatinant N, Shaw J, Armin D, Tew J Jr: Stereotactic radiosurgery for the treatment of brain metastases. Results of a single institution series. *Cancer* 79: 551-557, 1997
- 6) Bruzzone M, Campora E, Chiara S, Giudici S, Merlini L, Simoni C, Mammoliti S, Rubagotti A, Rosso R: Cerebral metastases secondary to ovarian cancer: still an unusual event. *Gynecol Oncol* 49: 37-40, 1993
- 7) Chen PG, Lee SY, Barnett GH, Vogelbaum MA, Saxton JP, Flemming PA, Suh JH: Use of the Radiation Therapy Oncology Group recursive partitioning analysis classification system and predictors of survival in 19 women with brain metastases from ovarian carcinoma. *Cancer* 104: 2174-2180, 2005
- 8) Cohen ZR, Suki D, Weinberg JS, Marmor E, Lang FF, Gershenson DM, Sawaya R: Brain metastases in patients with ovarian carcinoma: prognostic factors and outcome. *J Neurooncol* 66: 313-325, 2004
- 9) Cormio G, Lissoni A, Losa G, Zanetta G, Pellegrino A, Mangioni C: Brain metastases from endometrial carcinoma. *Gynecol Oncol* 61: 40-43, 1996
- 10) Cormio G, Pellegrino A, Landoni F, Regallo M, Zenetta G, Colombo A, Mangioni C: Brain metastases from cervical carcinoma. *Tumori* 82: 394-396, 1996
- 11) Corn BW, Greven KM, Randall ME, Wolfson AH, Kim RY, Lanciano RM: The efficacy of cranial irradiation in ovarian cancer metastatic to the brain: analysis of 32 cases. *Obstet Gynecol* 86: 955-959, 1995
- 12) Dauplat J, Nieberg RK, Hacker NF: Central nervous system metastases in epithelial ovarian carcinoma. *Cancer* 60: 2559-2562, 1987
- 13) De Porre PM, Subandono Tjokrowardojo AJ: Brain metastases of endometrial carcinoma. Case report and review of literature. *Strahlenther Onkol* 168: 100-101, 1992
- 14) Gaspar L, Scott C, Rotman M, Asbell S, Phillips T, Wasserman T, McKenna WG, Byhardt R: Recursive partitioning analysis (RPA) of prognostic factors in three Radiation Therapy Oncology Group (RTOG) brain metastases trials. *Int J Radiat Oncol Biol Phys* 37: 745-751, 1997
- 15) Gaspar LE, Scott C, Murray K, Curran W: Validation of the RTOG recursive partitioning analysis (RPA) classification for brain metastases. *Int J Radiat Oncol Biol Phys* 47: 1001-1006, 2000
- 16) Gien LT, Kwon JS, D'Souza DP, Radwan JS, Hammond JA, Sugimoto AK, Carey MS: Brain metastases from endometrial carcinoma: a retrospective study. *Gynecol Oncol* 93: 524-528, 2004
- 17) Ikeda S, Yamada T, Katsumata N, Hida K, Tanemura K, Tsunematu R, Ohmi K, Sonoda T, Ikeda H, Nomura K: Cerebral metastasis in patients with uterine cervical cancer. *Jpn J Clin Oncol* 28: 27-29, 1998
- 18) Kaplan EL, Meier P: Nonparametric estimation from incomplete observations. *J Am Stat Assoc* 53: 457-481, 1958
- 19) Kolomainen DF, Larkin JM, Badran M, A'Hern RP, King DM, Fisher C, Bridges JE, Blake PR, Barton DP, Shepherd JH, Kaye SB, Gore ME: Epithelial ovarian cancer metastasizing to the brain: a late manifestation of the disease with an increasing incidence. *J Clin Oncol* 20: 982-986, 2002
- 20) Kottke-Marchant K, Estes ML, Nuzez C: Early brain metastases in endometrial carcinoma. *Gynecol Oncol* 41: 67-73, 1991
- 21) Kumar L, Tanwar RK, Singh SP: Intracranial metastases from carcinoma cervix and review of literature. *Gynecol Oncol* 46: 391-392, 1992
- 22) Kurtz JM, Gelber R, Brady LW, Carella RJ, Cooper JS: The palliation of brain metastases in a favorable patient population: a randomized clinical trial by the Radiation Therapy Oncology Group. *Int J Radiat Oncol Biol Phys* 7: 891-895, 1981
- 23) Larson DM, Copeland LJ, Moser RP, Malone JM Jr, Gershenson DM, Wharton JT: Central nervous system metastases in epithelial ovarian carcinoma. *Obstet Gynecol* 68: 746-750, 1986
- 24) Mahmoud-Ahmed AS, Kupelian PA, Reddy CA, Suh JH: Brain metastases from gynecological cancers: factors that affect overall survival. *Technol Cancer Res Treat* 1: 305-310, 2002
- 25) Mahmoud-Ahmed AS, Suh JH, Barnett GH, Webster KD, Belinson JL, Kennedy AW: The effect of radiation therapy on brain metastases from endometrial

- carcinoma: a retrospective study. *Gynecol Oncol* 83: 305–309, 2001
- 26) Mahmoud-Ahmed AS, Suh JH, Barnett GH, Webster KD, Kennedy AW: Tumor distribution and survival in six patients with brain metastases from cervical carcinoma. *Gynecol Oncol* 81: 196–200, 2001
 - 27) Mantel N: Evaluation of survival data and two new rank order statistics arising in its consideration. *Cancer Chemother Rep* 50: 163–170, 1966
 - 28) Melichar B, Urminska H, Kohlova T, Nova M, Cesak T: Brain metastases of epithelial ovarian carcinoma responding to cisplatin and gemcitabine combination chemotherapy: a case report and review of the literature. *Gynecol Oncol* 94: 267–276, 2004
 - 29) Ogawa K, Toita T, Kakinohana Y, Kamata M, Moromizato H, Nagai Y, Higashi M, Kanazawa K, Yoshii Y: Palliative radiation therapy for brain metastases from endometrial carcinoma: report of two cases. *Jpn J Clin Oncol* 29: 498–503, 1999
 - 30) Patchell RA, Tibbs PA, Walsh JW, Dempsey RJ, Murayama Y, Kryscio RJ, Markesbery WR, Macdonald JS, Young B: A randomized trial of surgery in the treatment of single brain metastases to the brain. *N Engl J Med* 322: 494–500, 1990
 - 31) Pectasides D, Aravantinos G, Fountzilas G, Kalofonos C, Efstathiou E, Karina M, Pavlidis N, Farmarkis D, Economopoulos T, Dimopoulos MA: Brain metastases from epithelial ovarian cancer. The Hellenic Cooperative Oncology Group (HeCOG) experience and review of the literature. *Anticancer Res* 25: 3553–3558, 2005
 - 32) Pectasides D, Pectasides M, Economopoulos T: Brain metastases from epithelial ovarian cancer: a review of the literature. *Oncologist* 11: 252–260, 2006
 - 33) Phillips TL, Scott CB, Leibel SA, Rotman M, Weigensberg IJ: Results of a randomized comparison of radiotherapy and bromodeoxyuridine with radiotherapy alone for brain metastases: report of RTOG trial 89-05. *Int J Radiat Oncol Biol Phys* 33: 339–348, 1995
 - 34) Rodriguez GC, Soper JT, Berchuck A, Oleson J, Dodge R, Montana G, Clarke-Pearson DL: Improved palliation of cerebral metastases in epithelial ovarian cancer using a combined modality approach including radiation therapy, chemotherapy, and surgery. *J Clin Oncol* 10: 1553–1560, 1992
 - 35) Saphner T, Gallion HH, Van Nagell JR, Kryscio R, Patchell RA: Neurologic complications of cervical cancer. A review of 2261 cases. *Cancer* 64: 1147–1151, 1989
 - 36) Smith SC, Koh WJ: Palliative radiation therapy for gynaecological malignancies. *Best Pract Res Clin Obstet Gynaecol* 15: 265–278, 2001
 - 37) Sood A, Kumar L, Sood R, Sandhu MS: Epithelial ovarian carcinoma metastatic to the central nervous system: a report on two cases with review of literature. *Gynecol Oncol* 62: 113–118, 1996
 - 38) Tay SK, Rajesh H: Brain metastases from epithelial ovarian cancer. *Int J Gynecol Cancer* 15: 824–829, 2005
 - 39) Vecht CJ, Haaxma-Reiche H, Noordijk EM, Padberg GW, Voormolen JH, Hoekstra FH, Tans JT, Lambooi N, Metsaars JA, Wattendorff AR, Brand R, Hermans J: Treatment of single brain metastasis: radiotherapy alone or combined with neurosurgery? *Ann Neurol* 33: 583–590, 1993
 - 40) Watanabe A, Shimada M, Kigawa J, Iba T, Oishi T, Kanamori Y, Terakawa N: The benefit of chemotherapy in a patient with multiple brain metastases and meningitis carcinomatosa from ovarian cancer. *Int J Clin Oncol* 10: 69–71, 2005
 - 41) Wen PY, Black PM, Loeffler JS: Treatment of metastatic cancer: metastatic brain tumor, in Devita VT Jr, Hellman S, Rosenberg SA (eds): *Cancer: Principles and Practice of Oncology*, ed 6. Philadelphia, Lippincott-Raven, 2001, pp 2655–2670

Address reprint requests to: Kazuhiko Ogawa, M.D., Department of Radiology, University of the Ryukyus School of Medicine, 207 Uehara, Nishihara-cho, Nakagami-gun, Okinawa 903-0215, Japan.
e-mail: kogawa@med.u-ryukyu.ac.jp

Commentary

In a scientifically sound, retrospective study of 2729 patients with gynecological cancer, the authors report on 18 patients who developed brain metastases. This subgroup had a remarkably poor prognosis (median survival about 4 months) despite treatment modalities (i.e., surgical resection and radiation or radiation alone). In the 2 patients who survived for more than 2 years, both had a single brain metastasis, inactive extracranial disease, and high Karnofsky performance scores. The authors noted that palliative radiotherapy was effective in improving quality of remaining life in patients with an unfavorable prognosis.

We recommend that the authors and readers consider the use of intraoperative radiation implants in select patients with single brain metastasis for local tumor control.¹⁾ In our experience, we believe that this radiation protocol is preferred versus whole brain radiation therapy for reducing the potential for long-term radiation induced toxicity. As the authors report on their experience for a small group of patients with brain metastases from gynecological cancer, they recommend further study.

Reference

- 1) Dagnew E, Kanski J, McDermott MW, Sneed PK, McPherson C, Breneman JC, Warnick RE: Management of newly diagnosed single brain metastasis using resec-

tion and permanent iodine-125 seeds without initial whole-brain radiotherapy: a two institution experience. *Neurosurg Focus* 22 (3): E3, 2007

John M. TEW, Jr., M.D.
Medical Director
The Neuroscience Institute:
University of Cincinnati College of Medicine
and the Mayfield Clinic
Cincinnati, Ohio, U.S.A.

This paper is a retrospective review from records of 18 cases with brain metastases from gynecological cancers. The authors demonstrated that treatment modality, extracranial disease status, total radiation

dose, number of brain metastases, and KPS had significant impacts on survival. These factors have been shown both in other and their own material to be significant prognostic factors for brain metastasis. These new data could be helpful for our clinical practice in the future. However, because brain metastases from gynecological cancers are very rare, more randomized trials are needed in the future.

Ruxiang XU, M.D.
Department of Neurosurgery
Neuromedicine Research Institute
Zhujiang Hospital of Southern Medical University
Guangzhou, P.R.C.