

## Solitary Metastasis of Bronchogenic Adenocarcinoma to the Internal Auditory Canal: A Case Report

We report a patient with an isolated metastasis to the internal auditory canal (IAC) of bronchogenic adenocarcinoma. A 58-yr-old man who had received 6-cycle of chemotherapy under diagnosis of non-small cell lung carcinoma (T4N2M0) two years ago was referred to our department with vertigo, right-sided facial paralysis and right-sided hearing loss. A provisional diagnosis of vestibular schwannoma or meningioma involving right IAC was made from magnetic resonance imaging. The patient underwent a translabyrinthine removal of the tumor. Histopathological study of the resected lesion showed a poorly differentiated adenocarcinoma compatible with bronchogenic origin. The patient died 9 months after surgery from extensive brain metastasis despite postoperative radiation therapy. In patients with a previous history of treatment of malignancy elsewhere in the body, the possibility of IAC metastasis must be considered when an IAC lesion is detected.

Key Words : *Neoplasm Metastasis; Internal Auditory Canal; Adenocarcinoma; Lung Neoplasms*

Ki-Hong Chang, Chang Eun Song,  
Jae-Hyun Seo, and Sang-Won Yeo

Department of Otolaryngology-HNS, Collage of  
Medicine, The Catholic University of Korea, Seoul,  
Korea

Received : 17 December 2007

Accepted : 22 May 2008

### Address for correspondence

Ki-Hong Chang, M.D.

Department of Otolaryngology, St. Mary's Hospital,  
The Catholic University of Korea, 62 Yeouido-dong,  
Yeongdeungpo-gu, Seoul 150-713, Korea  
Tel : +82.2-3779-1061, Fax : +82.2-786-1149  
E-mail : khchang@catholic.ac.kr

### INTRODUCTION

While bronchogenic adenocarcinoma metastasizes to the temporal bone not uncommonly, isolated metastasis to the internal auditory canal (IAC) is extremely rare. We recently experienced a patient with solitary metastasis of bronchogenic adenocarcinoma to the IAC.

### CASE REPORT

A 58-yr-old man was referred to our department with a week of right-sided facial paralysis (House-Brackmann grade III) accompanied by three months' history of vertigo with right-sided hearing loss. No other neurological symptoms were observed. His audiogram showed a total loss of hearing on the right ear and normal hearing on the left side. A canal paresis in the right ear was noted on electronystagmography. Electroneurography revealed 78% of facial nerve degeneration on the eighth day of facial palsy.

Two years ago, the patient had received 6-cycle of chemotherapy under diagnosis of non-small cell lung carcinoma (T4N2M0) at other hospital. During the last 2 yr of office follow-up, no sign of tumor recurrence was found. One month before visiting our hospital, magnetic resonance imaging (MRI) of the brain showed no evidence of brain parenchymal metastasis or abnormal enhancing lesion.

MRI scan with gadolinium contrast taken at our hospital showed an enhancing lesion involving right IAC and cister-

nal segment with dural thickening (Fig. 1). Computed tomography (CT) of temporal bone showed no abnormality.

A provisional diagnosis of vestibular schwannoma or meningioma involving right IAC was made, although the possibility of metastasis was considered.

The patient underwent a translabyrinthine removal of the tumor. The operative finding demonstrated a lobulated, soft, pinkish mass confined to the IAC, where it did not involve both the seventh and eighth cranial nerves directly but enclose them. Adhesion between the tumor and cranial nerves was not severe. So it is not difficult to resect the tumor from the nerves with anatomical preservation of facial nerve. The vestibular nerves were removed with tumor mass together. The facial palsy did not aggravated postoperatively.

Histopathological study of the resected lesion showed a poorly differentiated adenocarcinoma compatible with bronchogenic origin (Fig. 2) based on immunohistochemical staining result that was positive for cytokeratin 7 (CK-7) and thyroid transcription factor 1 (TTF-1), but negative for cytokeratin 20 (CK-20) (Fig. 3).

A thorough metastatic work up was completely negative. A month later, the patient received 3,000 cGy of external beam radiation therapy to the right inner ear. The patient refused adjuvant chemotherapy.

Five months after surgery, despite the absence of evident recurrence on chest CT, follow-up brain MRI scan revealed newly found metastases in the left IAC, left cerebellum, and right superior parietal gyrus with adjacent pachymeningeal enhancement.

The patient died 9 months after surgery of complication associated with extensive brain metastasis.

## DISCUSSION

The most common tumor occupying the IAC and cerebellopontine angle is vestibular schwannoma, followed by meningioma, epidermoid cyst, glomus jugulare tumors, and facial and trigeminal neuroma (1). Primary metastasis to the IAC is rarely reported, representing 0.7% of the CPA tumors.

The most frequent site of temporal bone metastasis is the petrous apex (30%) followed by the tegmen tympani (25%) (2). Gloria-Cruz et al. (3), in a study of 415 temporal bones of 212 autopsies of patients with primary non-disseminated malignant neoplasms, found 76 temporal bones (18.3%) metastasis, of which 27.6% had IAC involvement, although

in only 2 cases the IAC was the sole site of metastasis.

In a review of 14 cases of metastases to the cerebellopontine angle (CPA) evidenced by magnetic resonance study, the primary tumors most often metastasizing to the CPA were lung carcinoma, breast carcinoma, melanoma, prostatic carcinoma, squamous cell carcinoma of the nasopharynx, and non-Hodgkin's lymphoma (4).

There are five distinct routes of tumor spread from the primary tumor to the temporal bone: 1) hematogenous spread, 2) cerebrospinal fluid (CSF) dissemination, 3) direct extension, 4) leptomeningeal extension, and 5) leukemic infiltration (5). The exact mechanism of spread of the malignancy to the IAC is not certain but possible spread route of our case is that tumor cells seed into the CSF and disseminate through the subarachnoid space into the IAC.

The MRI features of the IAC metastasis were similar to those of a schwannoma except for the presence of thick linear and extranodular contrast enhancement, not seen in the purely intracanalicular schwannomas (6). Contrast enhancement along the porus could suggest meningeal infiltration.

Metastatic lesion of the IAC must be treated more aggressively than other IAC tumors. Once metastasis is suspected,

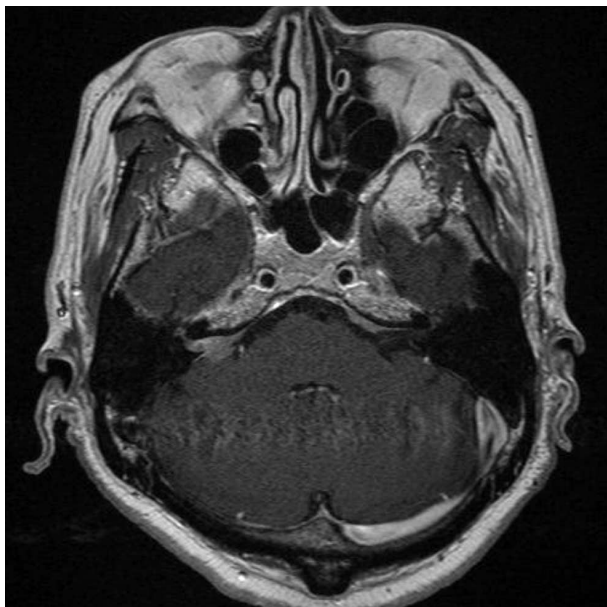


Fig. 1. Gadolinium-enhanced T1-weighted axial MRI scan showing a space-occupying lesion involving right IAC and cisternal segment with dural thickening.

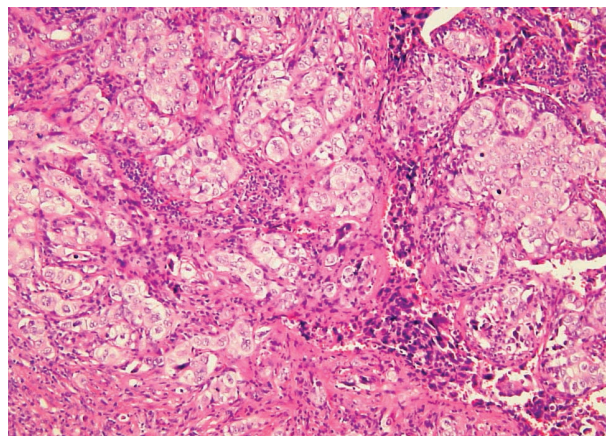


Fig. 2. Histologic section from the excised specimen of the IAC mass showing poorly differentiated adenocarcinoma (H&E,  $\times 100$ ).

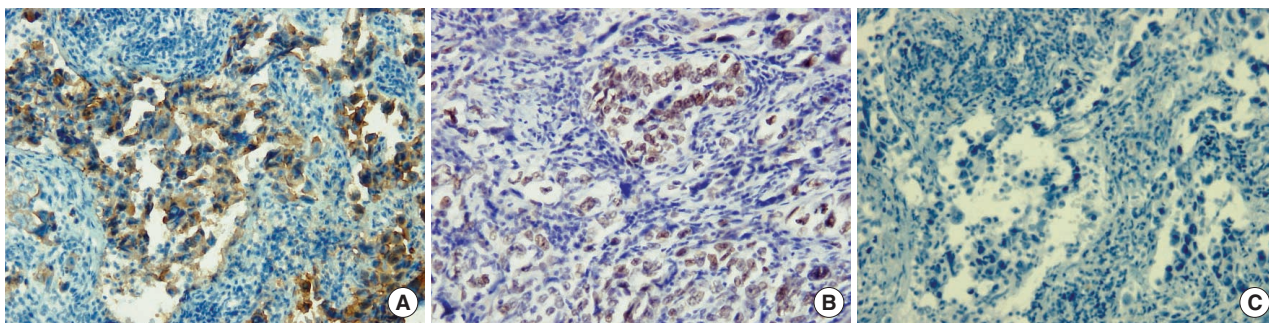


Fig. 3. Result of the immunohistochemical staining for the IAC mass. (A) Positive immunostaining for CK-7. (B) Positive immunostaining for TTF-1. (C) Negative immunostaining for CK-20 ( $\times 200$ ).

the adequate treatment, which consists in a multidisciplinary approach with surgery, radiotherapy and chemotherapy, should be promoted. In the literature, several cases of the IAC metastasis were reported, most of which died within 1 yr after diagnosis because of extensive brain metastasis (7-10). Considered retrospectively, our patient should have received adjuvant concurrent chemoradiation therapy including whole brain radiation rather than narrow field radiation, with aims to destroy left-over malignant cells that might have been present after surgical excision.

This case is peculiar and somewhat differs from previously reported cases of malignant metastasis to the IAC in two aspects: 1) solitary IAC metastasis without other distant metastasis at the time of diagnosis, 2) metachronous metastasis. Our patient died of extensive brain metastasis despite surgical excision and postoperative radiotherapy. We suggest surgical excision and adjuvant concurrent chemoradiation therapy with careful follow up as the proper therapeutic approach in such patients. In patients with a previous history of treatment of malignancy elsewhere in the body, the possibility of IAC metastasis must be considered when an IAC lesion is detected.

## REFERENCES

1. Moffat DA, Saunders JE, McElveen JT Jr, McFerran DJ, Hardy DG. *Unusual cerebello-pontine angle tumors. J Laryngol Otol* 1993; 107: 1087-98.
2. Belal A Jr. *Metastatic tumours of the temporal bone-a histopathological report. J Laryngol Otol* 1985; 99: 839-46.
3. Gloria-Cruz TI, Schachern PA, Paparella MM, Adams GL, Fulton SE. *Metastases to temporal bones from primary nonsystemic malignant neoplasms. Arch Otolaryngol Head Neck Surg* 2000; 126: 209-14.
4. Yuh WT, Mayr-Yuh NA, Koci TM, Simon JH, Nelson KL, Zyroff J, Jinkins JR. *Metastatic lesions involving the cerebellopontine angle. AJNR Am J Neuroradiol* 1993; 14: 99-106.
5. Cureoglu S, Tulunay O, Ferlito A, Schachern PA, Paparella MM, Rinaldo A. *Otologic manifestations of metastatic tumors to the temporal bone. Acta Otolaryngol* 2004; 124: 1117-23.
6. Krainik A, Cyna-Gorse F, Bouccara D, Cazals-Hatem D, Vilgrain V, Denys A, Rey A, Sterkers O, Menu Y. *MRI of unusual lesions in the internal auditory canal. Neuroradiology* 2001; 43: 52-7.
7. Moloy PJ, del Junco R, Porter RW, Brackmann DE. *Metastasis from an unknown primary presenting as a tumor in the internal auditory meatus. Am J Otol* 1989; 10: 297-300.
8. Marques E, Brandis A, Samii M, Tatagiba M. *Late metastasis of breast adenocarcinoma into internal auditory canal and cerebellopontine angle: case report. Arq Neuropsiquiatr* 2002; 60: 639-42.
9. Suryanarayanan R, Dezso A, Ramsden RT, Gillespie JE. *Metastatic carcinoma mimicking a facial nerve schwannoma: the role of computerized tomography in diagnosis. J Laryngol Otol* 2005; 119: 1010-2.
10. Schrock A, Laffers W, Bootz F. *Solitary metastasis of lung carcinoma to the internal auditory canal. Am J Otolaryngol* 2006; 27: 214-6.

1. Moffat DA, Saunders JE, McElveen JT Jr, McFerran DJ, Hardy DG.