

## Neoplasm

# Lipoglioblastoma: a lipidized glioma radiologically and histologically mimicking adipose tissue

Michael W. Johnson MD, PhD<sup>a</sup>, Doris Lin MD<sup>b</sup>, Bassam N. Smir MD<sup>c</sup>, Peter C. Burger MD<sup>a,\*</sup>

<sup>a</sup>Department of Pathology, Johns Hopkins University School of Medicine, Baltimore, MD 21287, USA

<sup>b</sup>Department of Radiology and Radiological Science, Johns Hopkins University School of Medicine, Baltimore, MD 21287, USA

<sup>c</sup>Greensboro Pathology Associates, PA Greensboro, NC 27415-3508, USA

Received 30 June 2009; accepted 16 July 2009

### Abstract

**Background:** We report the case of a man with glioblastoma containing a component radiologically and histologically mimicking adipose tissue.

**Case Description:** A 48-year-old man recently complaining of headaches and difficulty with speech presented with a cystic peripherally enhancing left temporoparietal mass with focal intrinsically (precontrast) bright nodules in fluid attenuated inversion recovery and T1-weighted images similar to adipose tissue. Histologically, the enhancing component was classic glioblastoma, whereas the bright nodules comprised tumor cells that in aggregate closely resembled adipose tissue.

**Conclusions:** The case illustrates the extent to which lipidized central nervous system tumors of glial origin, or components thereof, can radiologically and histologically resemble adipose tissue. However, immunohistochemical staining and electron microscopy can eliminate diagnostic confusion.

© 2010 Elsevier Inc. All rights reserved.

### Keywords:

Glioblastoma; Lipidization; Lipoglioblastoma; Lipoastrocytoma; Adipose tissue

## 1. Introduction

The CNS tumors are sometimes lipidized—for example pleomorphic xanthoastrocytoma (PXA)—but only rarely to the extent that the affected areas resemble adipose tissue histologically. Even less common are tumors wherein the adipose tissue is extensive enough to become apparent grossly on MRI. We report a glioblastoma, with lipidization that resembled adipose tissue both radiologically and histologically.

## 2. Case history

A 48-year-old man presented with a 2-week headache and speech difficulties. Magnetic resonance imaging demonstrated a  $5 \times 4 \times 3$  cm solid and cystic/necrotic ring-enhancing mass in the left temporoparietal region (Fig. 1A). Within the solid enhancing component were several distinct well-circumscribed nodules that were hyperintense on both precontrast T1-weighted images and T2 FLAIR-weighted images. A gross total excision was achieved. The patient died 15 months after the surgery despite radiotherapy and chemotherapy.

## 3. Results

Most of the solid tumor consisted of solid sheets of mitotically active pleomorphic cells with angular nuclei with coarse chromatin typical of high-grade astrocytomas (Fig. 2A). There was extensive vascular proliferation (Fig. 2B) and focal necrosis (Fig. 2C). Less cellular, but mitotically active, infiltrating areas were also present.

*Abbreviations:* CNS, central nervous system; EMA, epithelial membrane antigen; FLAIR, fluid attenuated inversion recovery; GBM, glioblastoma; GFAP, glial fibrillary acidic protein; MRI, magnetic resonance imaging; PXA, pleomorphic xanthoastrocytoma

\* Corresponding author. Department of Pathology, Baltimore, MD 21287, USA. Tel.: +1 410 955 8378; fax: +1 410 614 9310.

E-mail address: [pburger@jhmi.edu](mailto:pburger@jhmi.edu) (P.C. Burger).

1878-8750/\$ - see front matter © 2010 Elsevier Inc. All rights reserved.  
doi:10.1016/j.wneu.2009.07.036

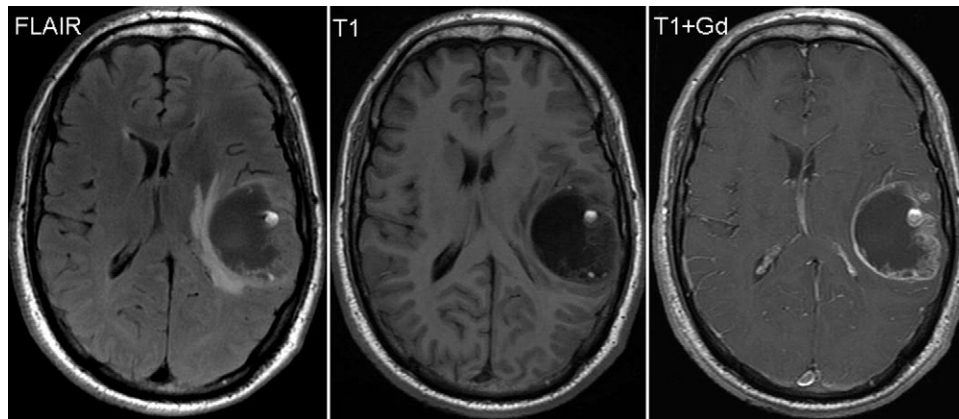


Fig. 1. Axial MRI (FLAIR, T1-weighted, and postcontrast T1-weighted) shows a large ring-enhancing mass in the superior left temporoparietal lobe, with thickened soft tissue in the posterior-lateral margin demonstrating irregular and nodular enhancement (T1 + gadolinium). Note also small nodular areas, isointense to adipose tissue, within the solid portion of the mass that are hyperintense on FLAIR and T1-weighted images.

Corresponding to the T1-precontrast, bright nodules was rarefied tissue indistinguishable at low and high magnification from adipose tissue, with its small dark nuclei flattened against the margins of the cells. The nodules were all well circumscribed, with sharp borders between lipidized and nonlipidized zones. Only the narrowest transition zone separated these 2 components (Fig. 3A and B). There was no spindled component to suggest gliosarcoma. The tumor in general and “adipocytes,” in

particular, were strongly positive for GFAP, the latter in a rim pattern (Fig. 3D). The tumor, including the lipidized component, was negative for synaptophysin.

#### 4. Discussion

Fat accumulation in CNS neoplasms usually takes the form of small cytoplasmic droplets that create a bubbly or

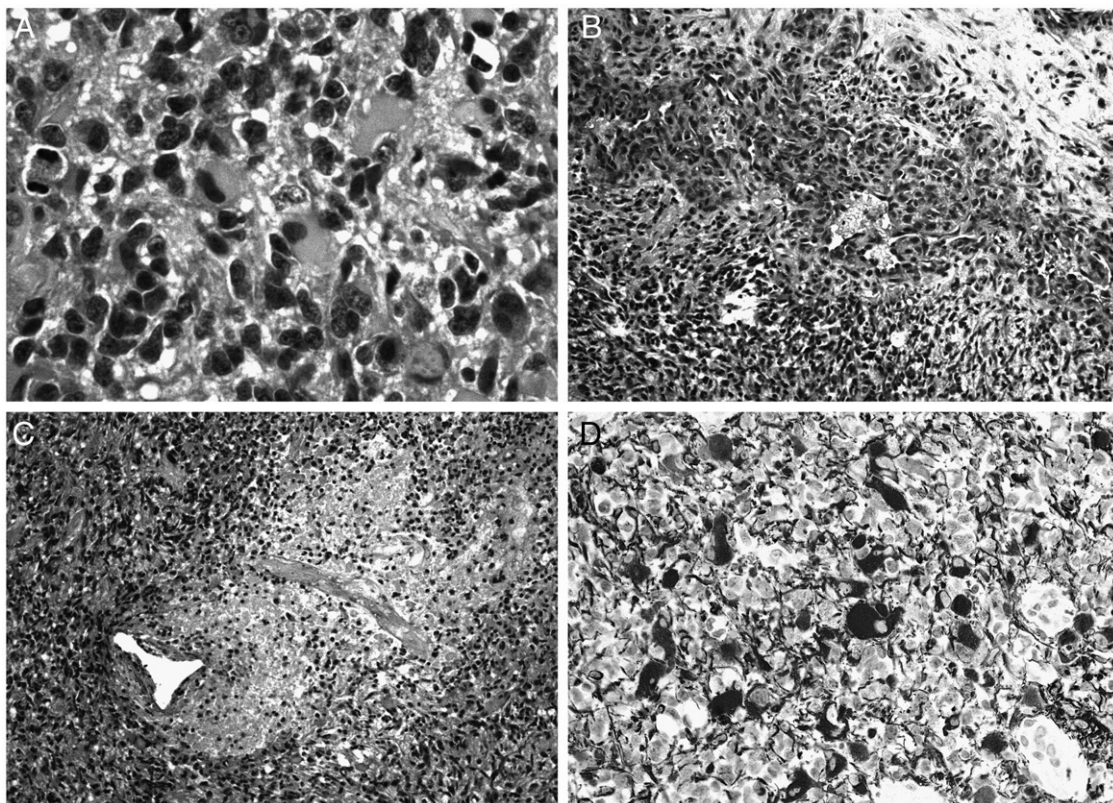


Fig. 2. Glioblastoma. Much of the tumor, corresponding to the enhancing nodule on MRI, is classically glioblastoma with mitotically active pleomorphic cells (A), vascular proliferation (B), and tumor necrosis (C). D: The tumor cells are GFAP-positive.

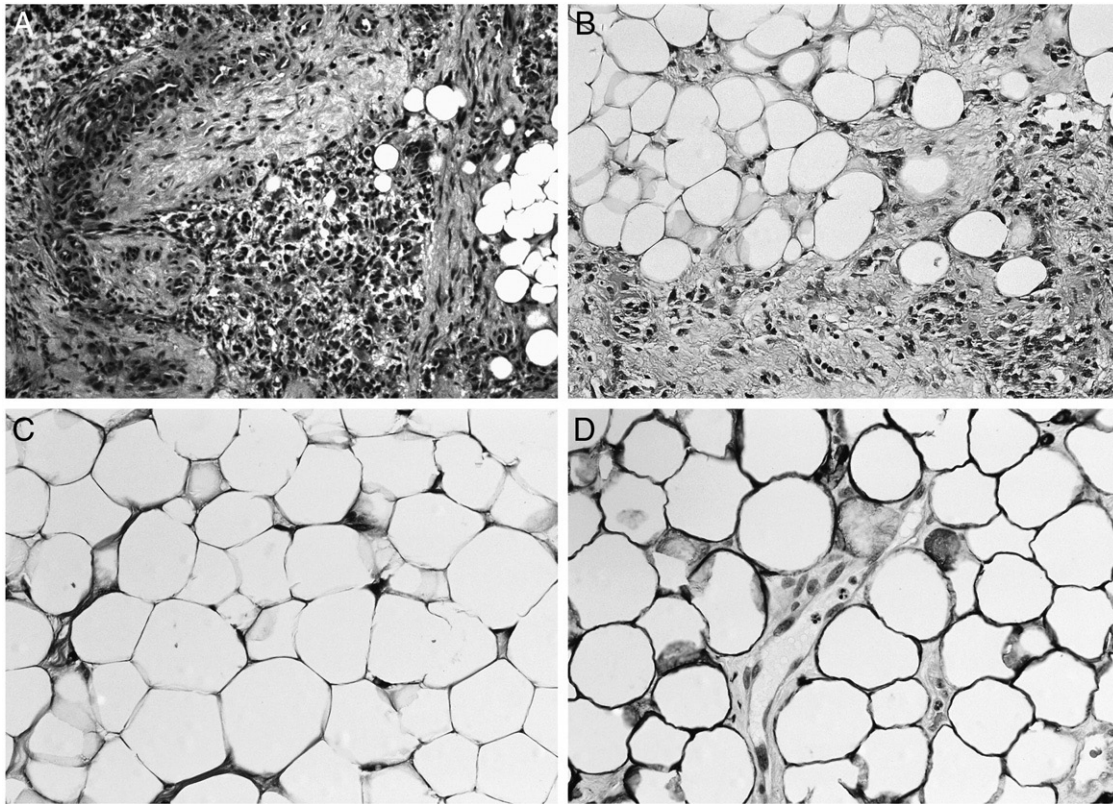


Fig. 3. Glioblastoma mimicking adipose tissue. A and B: The solid pleomorphic tumor with vascular proliferation merges into what appears to be mature adipose tissue. C: The adipocyte-like cells have large central lipid droplets that are lost in processing. D: Despite their resemblance to adipocytes, these cells, like the other tumor cells, are GFAP-positive.

xanthomatous appearance as in the iconic lipidized CNS tumor, PXA [8]. Large clear vacuoles suggesting fat droplets are not infrequently encountered in other CNS tumors as well, but confirmatory fat stains on frozen sections are rarely done. Nevertheless, one suspects that the vacuities must have been lipid and that the incidence of lipidization of CNS tumors is greater than is realized.

Cytoplasmic vacuoles known to represent lipid enliven the lipid-rich glioblastomas [7,9] including epithelioid [14] and giant-cell variants [10]. More impressive are tumor cells so lipid-laden that they resemble adipocytes individually or to adipose tissue in aggregate, sometimes even macroscopically [12]. Such tumors include rare, otherwise typical, glioblastomas [12], ependymomas (“lipomatous”) [15,16], astrocytomas (“lipoastrocytoma,” “astrolipoma,” “astrocytoma with extensive lipidization”) [4,18], neurocytomas (“liponeurocytoma”) [2,3,5], primitive neuroectodermal tumors (“lipomatous”) [6], and meningiomas (“lipomatous”) [1,11,13]. Gliosarcomas rarely have a liposarcomatous component [17].

Lipidization in CNS tumors is usually an unexpected histologic finding but may be so prominent, as in the present case, as to be apparent preoperatively on MRI [3,4,6,13,15,18]. The same tissue may be present at the microscopic level but not abundant and concentrated enough to be recognized radiologically [12]. The present case

therefore is one of the former, wherein a lipidized component is evident, both histologically and radiologically.

The nature of lipidized CNS tumor cells may be apparent by the context and transition forms between obvious tumor cells and the lipid-laden variants, electron microscopy, or immunohistochemistry. Electron microscopy identifies tell-tale structures such as desmosomes in meningiomas or reveals a unit membrane that encircles the lipid in adipocytes but not in lipidized tumor cells [13]. Immunohistochemistry is helpful if lipidized cells are immunoreactive for GFAP, EMA, or synaptophysin, for gliomas, meningiomas, and neurocytomas, respectively.

Although there is little doubt about the glioblastomatous nature of the present case as well as others with classic features of “GBM,” molecular studies in a series of 3 cases found changes consistent with high-grade astrocytoma, for example, gain of chromosome 7 and losses of chromosomes 9 and 10 [12].

## References

- [1] Colnat-Coulbois S, Kremer S, Weinbreck N, et al. Lipomatous meningioma: report of 2 cases and review of the literature. *Surg Neurol* 2008;69:398-402.
- [2] Elshihabi S, Husain M, Linskey M. Lipomatous medulloblastoma: a rare adult tumor variant with a uniquely favorable prognosis. *Surg Neurol* 2003;60:566-70.

- [3] Fung KM, Fang W, Norton RE, et al. Cerebellar central liponeurocytoma. *Ultrastruct Pathol* 2003;27:109-14.
- [4] Giangaspero F, Kaulich K, Cencacchi G, et al. Lipoastrocytoma: a rare low-grade astrocytoma variant of pediatric age. *Acta Neuropathol* 2002;103:152-6.
- [5] Horstmann S, Perry A, Reifenberger G, et al. Genetic and expression profiles of cerebellar liponeurocytomas. *Brain Pathol* 2004;14:281-9.
- [6] Ishizawa K, Kan-nuki S, Kumagai H, et al. Lipomatous primitive neuroectodermal tumor with a glioblastoma component: a case report. *Acta Neuropathol* 2002;103:193-8.
- [7] Kepes JJ. Astrocytomas: old and newly recognized variants, their spectrum of morphology and antigen expression. *Can J Neurol Sci* 1987;14:109-21.
- [8] Kepes JJ. Pleomorphic xanthoastrocytoma: the birth of a diagnosis and a concept. *Brain Pathol* 1993;28:1111-4.
- [9] Kepes JJ, Rubinstein LJ. Malignant gliomas with heavily lipidized (foamy) tumor cells: a report of three cases with immunoperoxidase study. *Cancer* 1981;47:2451-9.
- [10] Kroh H, Matyja E, Marchel A, et al. Heavily lipidized, calcified giant cell glioblastoma in an 8-year-old patient, associated with neurofibromatosis type 1 (NF1): report of a case with long-term survival. *Clin Neuropathol* 2004;23:286-91.
- [11] Matyja E, Naganska E, Zabek M, et al. Meningioma with the unique coexistence of secretory and lipomatous components: a case report with immunohistochemical and ultrastructural study. *Clin Neuropathol* 2005;24:257-61.
- [12] Rickert CH, Riemenschneider MD, Schachenmayr W, et al. Glioblastoma with adipocyte-like tumor cell differentiation-histological and molecular features of a rare differentiation pattern. *Brain Pathol* 2009;19:431-8.
- [13] Roncaroli F, Scheithauer BW, Laeng RH, et al. Lipomatous meningioma: a clinicopathologic study of 18 cases with special reference to the issue of metaplasia. *Am J Surg Pathol* 2001;25:769-75.
- [14] Rosenblum MK, Erlandson RA, Budzilovich GN. The lipid-rich epithelioid glioblastoma. *Am J Surg Pathol* 1991;15:925-34.
- [15] Ruchoux MM, Kepes JJ, Dhellemmes P, et al. Lipomatous differentiation in ependymomas: a report of three cases and comparison with similar changes reported in other central nervous system neoplasms of neuroectodermal origin. *Am J Surg Pathol* 1993;22:338-46.
- [16] Sharma MC, Arora R, Lakhtakia R, et al. Ependymoma with extensive lipidization mimicking adipose tissue: a report of five cases. *Pathol Oncol Res* 2000;6:136-40.
- [17] Vlodavsky E, Konstantinescu M, Soustiel JF. Gliosarcoma with liposarcomatous differentiation. The new member of the lipid-containing brain tumors family. *Arch Pathol Lab Med* 2006;130:381-4.
- [18] Walter A, Dingemans KP, Weinstein HC, et al. Cerebellar astrocytoma with extensive lipidization mimicking adipose tissue. *Acta Neuropathol* 1994;88:485-9.

WWW.WORLDNEUROSURGERY.COM

World Neurosurgery - Home

http://www.worldneurosurgery.org/

BabyZone.com www.artcame...layer\_2.jpg Reviews & R...s and Music USC Credit ...n - Welcome Your Cart | FontShop eTrac - USC...line Services

A FORUM FOR SIX CONTINENTS

**WORLD NEUROSURGERY**

OFFICIAL JOURNAL OF THE WORLD FEDERATION OF NEUROSURGICAL SOCIETIES

Register or Login:  Password:  SIGN IN  Auto-Login [Reminded]

Search  This Periodical for  GC

Advanced Search - MEDLINE - My Recent Searches - My Saved Searches - Search Tips

JOURNAL HOME

CURRENT ISSUE

SEARCH THIS JOURNAL

JOURNAL INFORMATION

- Aims and Scope
- Editorial Board
- Author Information
- Contact Information
- Society Information
- Pricing Information

SUBSCRIBE TO JOURNAL

ONLINE SUBMISSION

CAREER OPPORTUNITIES


RSS

More periodicals:

FIND A PERIODICAL

FIND A PORTAL

GO TO PRODUCT CATALOG




**Current Issue**

January 2010 | Vol. 73, No. 1

[VIEW CURRENT ISSUE](#)

[SEARCH THIS JOURNAL](#)

**EDITORIAL**




Meet the Editor, Dr. Michael Apuzzo, and learn of the [origins and evolution of this new title in neurosurgery](#). Understand the mission of the [World Federation of Neurosurgical Societies](#).

"*World Neurosurgery* is a publication designed to not only convey high level peer reviewed clinical and laboratory neuroscience, but to address issues of political, social, economic, educational and cultural relevance as they affect the management and treatment of neurosurgical diseases regionally and globally. It will chronicle events, places, people, our times, and literature, internationally."

—Michael L.J. Apuzzo, Editor-in-Chief

**CALL FOR PAPERS**



[Submit your manuscript at: www.elsevier.com/locate/neurosurgery](#)

**WELCOME TO WORLD NEUROSURGERY**

Full-text articles are available with the first issue, January 2010, and access to this content is currently open to all.

**RECEIVE FREE EMAIL ALERTS**

Register or login to sign up now to receive each issue's table of contents via email as it becomes available.

[Add Table of Contents Alert](#)

Copyright © 2010 Elsevier, Inc. All rights reserved | Privacy Policy | Terms & Conditions | Feedback | About Us | Help | Contact Us |  
The content on this site is intended for health professionals.