

The Role of Intra-cerebrospinal Fluid Treatment and Prophylaxis in Patients With Solid Tumors

Riccardo Soffiatti,^a Wallace Akerley,^b Randy L. Jensen,^c Joachim Bischoff,^d
and Anne Constanze Regierer^e

Metastasis to the central nervous system (CNS), including neoplastic meningitis (NM), is a devastating complication of systemic cancer. With the improved survival of cancer patients, the incidence of CNS metastasis is rising, especially among those with breast or lung carcinoma. New therapies that effectively treat these primary tumors outside of the CNS have underscored the significance of CNS metastases; they have become a significant clinical issue and a therapeutic challenge. This review discusses clinical situations in which treatment or chemoprophylaxis of CNS metastases and NM from breast or lung cancer may play an important role. Potential clinical trials to assess these assumptions also will be proposed.

Semin Oncol 36 (Suppl 2):S55-S68 © 2009 Elsevier Inc. All rights reserved.

It is estimated that in 2008, there were more than 1.4 million new cases of cancer in the United States, with 565,650 deaths.¹ Between 1973 and 2003, Barnholtz-Sloan and colleagues reported a 9.6% incidence of central nervous system (CNS) metastases among 16,210 patients diagnosed with solid tumors in the Metropolitan Detroit Cancer Surveillance System.² Lung cancer was reported to be the solid tumor that relapsed to the CNS most frequently (19.9%), followed by melanoma (6.9%), renal (6.5%), breast (5.1%), and colorectal cancers (1.8%).

Neoplastic meningitis (NM) is a devastating form of CNS metastasis characterized by the invasion of the leptomeninges and cerebrospinal fluid (CSF) by malignant cells.³ NM is associated with rapid and progressive neurological deterioration, and median survival in un-

treated patients with NM is only a few weeks.⁴ The actual overall incidence of NM is difficult to establish, but it has been estimated to be between 6% and 21% in patients with solid tumors.⁵ The main solid tumors to invade the leptomeninges are breast and lung cancer, which account for 12% to 50% and 10% to 26%, respectively, of cases of NM.⁶⁻⁸ Many cases go unrecognized. The chance of developing NM also may increase in certain situations, such as surgical resection of brain metastases located in the posterior fossa.⁹⁻¹²

As detailed elsewhere in this supplement, the diagnosis of NM relies on either positive CSF cytology, abnormal magnetic resonance imaging (MRI), or clinical findings in the appropriate circumstances (eg, raised protein and cranial nerve palsy). Since the presentation of NM is protean, it is important to have a high clinical suspicion in the presence of vague neurological symptoms. Failure to evaluate is common because of unrecognized symptoms and a perception that there are no available therapies.

Overall, the occurrence of CNS metastases, including NM, has been increasing.⁵ This is due to a number of factors. First, the development of improved treatments for primary breast and lung cancers provides more effective control of systemic disease and results in longer survival.¹³ However, because of the relative inability of systemic chemotherapy to penetrate the blood-brain barrier (BBB), a sanctuary site for metastatic cells is created in the CNS.⁵ For example, a retrospective study by Clayton and colleagues demonstrated that 25% of patients with breast cancer (n = 93) treated with trastuzumab developed brain metastases, and suggested that although trastuzumab promoted

^aDepartments of Neuroscience and Oncology, University and San Giovanni Battista Hospital, Torino, Italy.

^bDepartment of Internal Medicine, Division of Medical Oncology, Huntsman Cancer Institute, University of Utah, Salt Lake City, UT.

^cDepartment of Neurosurgery, Huntsman Cancer Institute, University of Utah Health Science Center, Salt Lake City, UT.

^dOtto-von-Guericke-University, University Hospital for Gynecology and Obstetrics, Magdeburg, Germany.

^eDepartment of Medical Oncology, Charité-Universitaetsmedizin Berlin, Berlin, Germany.

STATEMENT OF CONFLICT OF INTEREST: The authors have nothing to disclose.

Address correspondence to Riccardo Soffiatti, MD, Division of Neuro-Oncology, University of Torino and San Giovanni Battista Hospital, 15 Via Cherasco, Torino, 10126, Italy. E-mail: riccardo.soffiatti@unito.it

0270-9295/09/\$ - see front matter

© 2009 Elsevier Inc. All rights reserved.

doi:10.1053/j.seminoncol.2009.05.007

long-term survival, it did not penetrate the CSF in sufficient quantities, creating a metastatic sanctuary site.¹⁴ A 2-year study of patients with small cell lung cancer (SCLC) in the Netherlands reported a 2% incidence of NM at the time of primary cancer diagnosis.¹⁵ Despite combination chemotherapy consisting of cyclophosphamide, doxorubicin, and etoposide, the 2-year cumulative incidence of NM on follow-up was 10%,¹⁵ suggesting that the CSF may have acted as a sanctuary site for metastasized cells. Further, nine of 21 (43%) patients with metastatic adenocarcinoma of the lung responding to an epidermal growth factor receptor (EGFR) inhibitor developed brain metastases, even though the majority demonstrated control of extracranial disease.¹⁶ Second, an increased awareness of this complication and improved diagnostic modalities have resulted in increased detection of CNS metastases.⁵ For some patients, CNS involvement may be the only cause of decreased quality of life (QoL) and the main threat to survival.

Although the treatment of NM is palliative, treatment may improve time to neurological progression and QoL. Conventional treatment for patients with brain metastases is whole-brain radiation therapy (WBRT).¹⁷ Although WBRT may relieve symptoms, survival averages only a few months.¹⁷ For patients with limited or no systemic disease and good neurological status, the combination of surgery or radiosurgery and WBRT results in improved outcome (eg, improved local control and delayed intracranial recurrence) compared with either treatment alone.¹⁷⁻¹⁹

Systemic chemotherapies (eg, methotrexate [MTX]) given at high doses to overcome the BBB have shown some activity in treating NM but may lead to substantial systemic toxicity.^{20,21} Intra-CSF chemotherapies circumvent the BBB and treat the entire neuroaxis while minimizing systemic toxicity. Agents that are most commonly used in clinical practice for intrathecal administration are MTX, cytarabine, thiotepe, and sustained-release cytarabine (liposomal cytarabine).²² MTX and cytarabine are indicated for the treatment of lymphomatous and leukemic meningitis, and liposomal cytarabine is indicated for the treatment of lymphomatous meningitis. However, none of these agents is approved by the US Food and Drug Administration for the treatment of NM from solid tumors.

Few clinical trials assessing the efficacy of intra-CSF therapy for patients with solid-tumor leptomeningeal metastases have been conducted, and only three are prospective, randomized trials (Table 1).^{8,23-30} However, a retrospective review of medical records from 126 patients with cytologically confirmed NM from solid tumors demonstrated that intra-CSF chemotherapy was a significant predictive factor of survival ($P = .01$).⁴ Some studies also indicate that NM from breast or lung cancer may respond to intra-CSF therapy,^{25,29} and long-term survival has been observed occasionally in

patients with breast cancer and leptomeningeal metastases (ie, >112 weeks).^{8,23,25} Still, the benefits of chemotherapy in NM from solid tumors are not yet clear.³⁰⁻³²

The increased frequency of CNS metastases, including NM, is a significant clinical issue and a therapeutic challenge both with regard to treatment and prevention. CNS prophylaxis in subpopulations at high risk of CNS metastases, and/or better screening and early diagnosis and treatment, may improve clinical outcome, including QoL. This underscores the need to identify patients most at risk of developing CNS metastases.

The purpose of this review is both practical and forward-looking. We will first examine clinical situations in which treatment or chemoprophylaxis of CNS metastases from breast carcinoma or lung cancer may play an important role. Next, we will present important considerations for preventing CNS metastases in the surgical resection setting. We will conclude with a potential trial proposal and discuss the assumptions presented.

NM AS A COMPLICATION OF BREAST CANCER

In 2008, more than 182,000 women in the United States were expected to be diagnosed with breast cancer.¹ Historically, 5% to 16% of women with breast cancer develop CNS metastases,^{2,33,34} although twice as many cases (30%) have been reported in autopsy series.³⁵ Among solid tumors, breast cancer is the most common tumor to invade the leptomeninges.^{7,36} The incidence of NM in patients with breast cancer is approximately 3% to 8%.³³ However, the incidence has been reported to be 19% upon autopsy analysis.³⁵

While the advent of improved primary chemotherapies has led to increased survival and a consequent increase in the incidence of CNS metastases, patients with otherwise stable extracranial disease may warrant monitoring and prophylaxis of CNS relapse. The role of intra-CSF chemotherapy for CNS disease in breast cancer is unclear. Critical issues to consider include: (1) the need to determine the capacity of intra-CSF chemotherapy to improve the clinical outcome of patients with breast cancer and clinically diagnosed NM with or without CNS metastases (does it work?); (2) whether patients with breast cancer and CNS metastases should receive chemoprophylaxis to curtail the risk of developing subsequent NM (can it be prevented?); (3) the identification of a subgroup of patients who may benefit from intensive NM screening but for whom intra-CSF chemoprophylaxis may not be justified (are there subgroups who are at special risk?); and (4) the use of risk factors in patients with breast cancer (defined by clinical profile or tumor biology or systemic treatment) to identify patients for whom intra-CSF prophylaxis may be beneficial enough to be investigated in a clinical trial.

Table 1. Efficacy of Intrathecal Therapies for the Treatment of Solid Tumors

First Author, Year	Study Description	Treatments	Response	Median Survival	Primary Tumor Data
Yap, 1982 ²³	N = 40 Breast, n = 40	WBRT + MTX	65% Negative CSF cytology + normalization of CSF biochemistry + improvement of neurological status	Responders: 6 mo Non-responders: 1 mo	
Wasserstrom, 1982 ⁸	N = 90 Breast, n = 46 Lung, n = 23	MTX	50% Stabilization/improvement of neurological symptoms \geq 1 mo	5.8 mo (1-29)	Survival: Breast: median 7.2 mo (1-29) Lung: median 4 mo (1-10) Other: 1-12
Ongerboer de Visser, 1983 ²⁴	N = 33 NR Breast, n = 33 Prospective, NR	MTX/Ommaya RT/MTX/lumbar Untreated		6 mo (0.5-28) 1 mo (0.25-7) 2 mo (0.25-3)	
Hitchins, 1987 ²⁵	N = 44 R Breast (n = 11) SCLC (n = 13)	MTX MTX + AraC	61% 45% (P = NS) Improved clinical status + negative CSF cytology + normalization of CSF biochemistry for \geq 4 wk	Responders: 18 wk Non-responders: 7 wk (P <.05)	Response rate: Breast: 36% SCLC: 69% ACUP: 50% Survival: Breast: median 9 wk (59 for responders) (1-112) SCLC: median 8 wk (1-26) ACUP: median 8 wk (1-39)
Grossman, 1993 ²⁶	R N = 52 Breast, n = 25* Lung, n = 12	MTX Thiotepa	0% Normal neurologic examination + negative CSF cytology (lumbar and ventricular) + no meningeal masses + normal CSF biochemistry	15.9 wk 14.1 wk	Survival: Breast: median 15 wk (one patient >110 wk) Lung: median 8 wk Other solid tumors: median 17 wk
Glantz, 1999 ²⁷	N = 61 R Breast, n = 22 Lung, n = 10 Other, n = 29	Liposomal AraC MTX	26% 20% (P = NS) Negative cytology at all previously >0 sites (lumbar and ventricular) + stable or improved neurological condition	105 days 78 days (P = NS)	Response: Breast: liposomal AraC: 2/11, MTX: 0/11 SCLC: liposomal AraC: 0/2, MTX: 2/2 NSCLC: liposomal AraC: 0/3, MTX: 1/3 Other: liposomal AraC: 6/15, MTX: 3/14 One patient with breast cancer treated with liposomal AraC survived 465 days
Jaeckle, 2002 ²⁸	N = 110 Breast, n = 38 Lung, n = 18	Liposomal AraC	27% Negative cytology at all previously >0 sites (lumbar and ventricular) + stable or improved neurological condition	95 days (7-791+)	
Kim, 2003 ²⁹	N = 50 NR Breast (n = 13) Lung (n = 33) Other	MTX MTX+ hydrocortisone + AraC	13.8% 38.5% (P = .036) Negative cytology from lumbar CSF	10.4 wk 18.6 wk P = .029	Response: Breast: 36% SCLC: 80%
Boogerd, 2004 ³⁰	N = 35 Breast, n = 35	MTX + RT (if necessary) RT but no IT treatment	59% 67% Stable or improved neurological condition	18.3 wk 30.3 wk (P = NS)	

Abbreviations: ACUP, adenocarcinoma unknown primary; AraC, cytarabine; CSF, cerebrospinal fluid; IT, intrathecal; MTX, methotrexate; NR, non-randomized; NSCLC, non-small cell lung cancer; NS, not significant; R, randomized; RT, radiation therapy; SCLC, small cell lung cancer; WBRT, whole brain radiation therapy.

*Study included individuals with lymphomatous meningitis. More patients randomized to MTX (61%) v thiotepa (33%) had breast cancer and were without evidence of systemic cancer. Radiation was administered to mass lesions or symptomatic sites.

Intra-CSF Chemotherapy: Improving Clinical Outcome for Breast Cancer Patients With NM

Intra-CSF administration of 20 mg MTX combined with WBRT (30 Gy) resulted in a 65% response rate (>50% reduction in tumor cell count and/or complete normalization of the CSF) among 40 patients with breast cancer and NM.²³ The median survival time for patients who responded to therapy was 6 months, compared with 1 month for non-responders ($P = .001$).²³ Thirty-one percent of patients died from progressive systemic disease while their NM was in remission. Four patients remained alive and in remission at 26 to 70+ weeks.²³ Combination therapy with intra-CSF MTX and cytarabine also has been assessed. In an early randomized study of patients with NM from mostly solid tumors ($N = 44$), including 11 patients with NM from breast cancer, intra-CSF MTX resulted in a larger, albeit statistically insignificant, response rate (defined as improved clinical status, negative CSF cytology, and normal CSF biochemistry for 4 weeks or longer) than MTX and cytarabine (61% *v* 45%, respectively) ($P = .10$).²⁵ However, the overall median survival was 7 weeks in non-responders and 18 weeks in responders ($P < .05$).²⁵ Among patients with NM from breast cancer, MTX alone resulted in a 67% response rate, versus a 25% response rate in similar patients treated with a combination of MTX and cytarabine.²⁵ A more recent study investigated the combination of intra-CSF MTX, cytarabine, and hydrocortisone compared with intra-CSF MTX alone in a non-randomized study that included 13 patients with NM from breast cancer.²⁹ The overall response rate among patients with breast cancer was 39%.²⁹ Treatment with MTX, cytarabine, and hydrocortisone resulted in a markedly, but not statistically significant, improved survival rate compared with intra-CSF MTX alone (23.7 weeks *v* 10.1 weeks, respectively; $P = .445$). In a study by Wasserstrom and colleagues, patients with NM from breast cancer were treated with radiation therapy followed by either intra-CSF MTX or intra-CSF cytarabine. Patients

had a median survival of 7.2 months (range, 1-29 months), and two patients survived 29 months.⁸

Intra-CSF MTX and thiotepa were compared in a randomized study involving 52 patients, of whom 48% had breast cancer.²⁶ Most patients deteriorated neurologically within 8 weeks of initiating therapy. Median survival was 15.9 weeks in the MTX group and 14.1 weeks in the thiotepa group.²⁶

Liposomal cytarabine, an extended-release form of cytarabine, was compared with MTX in 61 patients with NM from solid tumors.²⁷ Of the 22 patients with breast cancer, two of 11 treated with liposomal cytarabine responded, including one who survived for 465 days, whereas none of the 11 patients treated with MTX responded to therapy.²⁷ Response was defined as a conversion from positive to negative CSF cytology from lumbar and ventricular sites plus a stable or improved neurological examination. Using similar response criteria, 28% of 43 evaluable patients with NM from breast cancer responded to intra-CSF therapy with liposomal cytarabine.³⁷ Median time to neurologic progression was 49 days (range, 1-515+ days), and median survival was 88 days (range, 1-515+ days).³⁷ Liposomal cytarabine was also investigated in an open-label study of 110 patients with NM, 38 of whom had breast cancer.²⁸ With similar response criteria, the overall response rate was 27%, with a median overall survival of 95 days (range, 7-791+ days) and a median time to neurological progression of 55 days (range, 0-584+ days).

In addition to intra-CSF therapies, several case studies have reported favorable response of CNS metastases³⁸⁻⁴⁰ and NM⁴⁰⁻⁴² to treatment with oral capecitabine.^{43,44} Capecitabine is indicated for the treatment of metastatic breast cancer as monotherapy or in combination with docetaxel.^{43,44} Based on these encouraging results, a pilot phase II, single-arm, open-label clinical trial is proposed to test whether combining capecitabine with liposomal cytarabine will improve the response rate, neurological status, and survival of pa-

Figure 1. Proposal for a pilot phase II single-arm, open-label clinical trial of capecitabine and liposomal cytarabine for the treatment of newly diagnosed neoplastic meningitis with or without central nervous system metastases in patients with breast cancer.

tients with breast cancer and NM (Figure 1). This trial could enroll patients with breast cancer and newly diagnosed CNS involvement (NM with or without brain metastases). Concurrent treatment such as with trastuzumab (to treat systemic disease), field radiotherapy (to treat bulky spinal disease including CSF blocks), and stereotactic surgery to treat isolated CNS metastases would be allowed. End points would include neurological progression-free survival (primary end point), overall response rate based upon clinical response (improvement of neurological signs and symptoms), cytologic and parenchymal response, overall survival, and safety. The predisposition for intrathecal medication-related toxicities, as discussed previously in this supplement, would need careful evaluation.

The Usefulness of Prophylactic Intra-CSF Treatment in Patients With Breast Cancer and CNS Metastases

At least half of the patients with CNS involvement have stable systemic disease, and the brain is often the first site of recurrence.¹³ When a brain relapse is diagnosed, seeding in the leptomeninges or CSF may already exist, even if it is not yet detectable. In addition, some patients with CNS metastases may be at increased risk of NM. Potential risk factors for meningeal relapse include surgery for isolated CNS metastases, especially surgery of metastases located in the posterior fossa⁹⁻¹²; the proximity of brain metastases to the subarachnoid space⁶; the number of metastases; the coexistence of vertebral metastases⁶; the tumor type³⁶; and the length of follow-up. Two potential clinical trials that could test the usefulness of CNS-directed chemoprophylaxis for patients with breast cancer and brain metastases are outlined in Figure 2. Both trials could include patients with recursive partitioning analysis class I or II (class I: patients with a Karnofsky Performance Score [KPS] ≥ 70 , < 65 years of age, controlled primary tumor and no extracranial metastases; class III: KPS < 70 ; class II: all others)⁴⁵ with complete or partial response after surgery, stereotactic surgery, radiation therapy, chemotherapy, or combined treatments. The first trial would randomize patients to observation or chemoprophylaxis with liposomal cytarabine (Figure 2A). The second trial would assign patients with positive CSF cytology to treatment with liposomal cytarabine, while those with negative CSF cytology would be observed (Figure 2B). Results from these trials could help determine the value of CNS-directed chemoprophylaxis.

Identifying Patients With Breast Cancer at High Risk of Developing CNS Metastases

The profoundly morbid effects of CNS metastases and the early identification of patients at risk may justify early systematic screening for CNS disease in otherwise asymptomatic patients with breast cancer

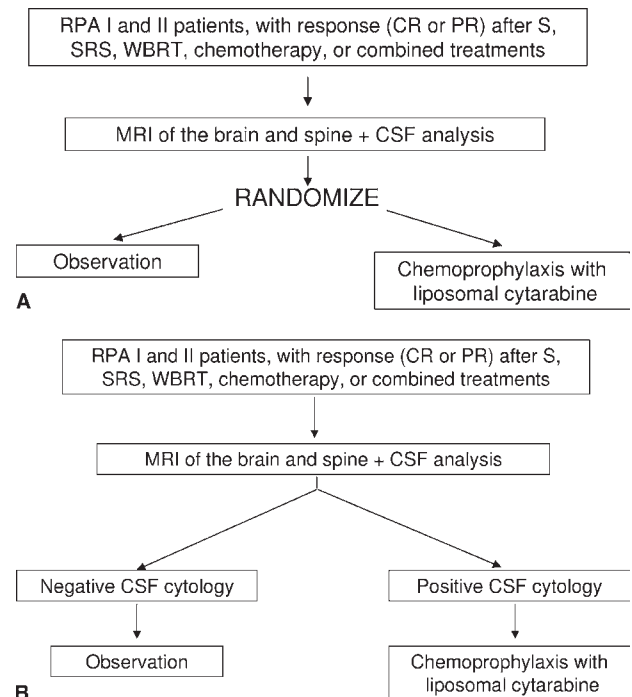


Figure 2. (A) Proposal for an intra-cerebrospinal fluid (CSF) prophylaxis trial in patients with brain metastases from breast cancer. Stratification for: CSF cytology (positive v negative v uncertain); tumor site (posterior fossa v cerebral hemispheres); surgical resection (yes v no); and vertebral metastases (yes v no). (B) Proposal for a CSF prophylaxis trial in patients with brain metastases from breast cancer. CR, complete response; PR, partial response; MRI, magnetic resonance imaging; RPA, recursive partitioning analysis (used for prognostic classification); S, surgery; SRS, stereotactic radiosurgery; WBRT, whole-brain radiation therapy.

and/or define a subpopulation of patients that may benefit from prophylaxis. However, there are currently no studies that address whether early screening for CNS metastases (parenchymal or meningeal) in patients with breast cancer would improve survival. Despite the paucity of data, it is possible to identify certain subpopulations of patients with breast cancer who are at high risk of developing CNS metastases.

Several factors have been identified that are associated with a higher risk of developing CNS metastases (Table 2).⁴⁶⁻⁴⁹ These include young age,⁴⁹⁻⁵² progressive disease stage,^{48,53} elevated lactate dehydrogenase,⁵⁴ nodal status,⁵³ lung metastases, and tumor characteristics such as negative estrogen (ER) or progesterone (PgR) receptor status, human epidermal growth factor receptor 2 (HER2) overexpression, cytokeratin (CK) 19 expression, tumor size, and grade.^{14,46-50,52,53,55,56} By evaluating several factors concomitantly, it may be possible to identify a group of women with a much higher risk of CNS metastases. This is illustrated in a study by Evans and colleagues, in which young age (ie, < 50 years old) combined with ER⁻ status resulted in a 53% risk of developing CNS metastases.⁵² For

Table 2. Risk Factors for Central Nervous System Relapse in Patients With Breast Cancer*

First Author, Year	HER-2 Overexpression	Negative Receptor Status	Large Tumor Size	CK 5/6/19 Expression	Infiltrating Ductal Carcinoma Histology	Lung Metastases	Disease Stage
Slimane, 2004 ⁴⁶		HR = 4.2; P = .002				HR = 4.3; P = 0.0003	
Gabos, 2006 ⁴⁷	HR = 3.55; P = .006	ER ⁺ : HR = 0.32; P = .002	≥2 cm HR = 2.76; P = .013				
Souglakos, 2006 ⁴⁸	HR = 29.4; P < .0001			CK19: HR = 8.31; P = .001			HR = 0.23; P < .0001
Tham, 2006 ⁴⁹		HR = 2.8; P < .001			HR = 2.5; P = .02		

Abbreviations: CK, cytokeratin; HER, human epidermal growth factor receptor; HR, hazard ratio.
*Identified by multivariate analysis.

patients with several risk factors, intensive screening (serial MRI and CSF cytology) may be justified to detect early signs of CNS disease. Even so, a true definition of risk factors still remains unclear, and the optimal timing and frequency of screening has not been established. Of consideration are the cost and inconvenience of routine CNS screening and the fact that some procedures are invasive (eg, lumbar puncture). In addition, the clinical and biological significance of isolated cells in the CSF is unclear and needs to be better defined.

Is There a Subpopulation of Breast Cancer Patients for Whom CNS Prophylaxis May Be Justified?

To be a candidate for CNS prophylaxis, the patient with breast cancer should be at high risk of CNS metastases and have a reasonable life expectancy. Analysis of breast tumor gene expression patterns may help identify patients who are candidates for CNS/CSF prophylaxis. More aggressive breast cancers, such as those with HER2/neu overexpression, and triple-negative receptor status (ER⁻, PgR⁻, and HER2⁻), have an increased risk of CNS metastasis and are associated with a poorer systemic prognosis.^{46-49,52,53,55,57}

HER2⁺ breast cancer can be effectively treated with a trastuzumab-containing regimen, resulting in improved survival.^{58,59} While trastuzumab is effective at eradicating systemic tumors, it may not prevent CNS metastases. As a monoclonal antibody directed against the extracellular domain of the HER2 receptor, the high molecular weight of trastuzumab may prevent it from crossing the BBB. As briefly mentioned earlier in this review, this may partly explain why brain metastases are increasingly reported among patients with breast cancer who are treated with a trastuzumab-based regimen (Table 3). Approximately 25% to 48% of women treated with trastuzumab develop CNS metastases,^{13,14,55,60-65} including 5% with NM alone¹³ and 14% to 24% with NM together with parenchymal metastases.^{13,62}

The tyrosine kinase inhibitor lapatinib, in combination with capecitabine, has been shown to be active against systemic disease and brain metastasis in women with advanced, progressive HER2⁺ breast cancer who have received multiple previous treatments.^{66,67} Anecdotal evidence indicates a potential role for capecitabine in NM.⁴⁰⁻⁴² In addition, preliminary data of an expanded phase II trial suggest that lapatinib alone is active in patients with HER2⁺ breast cancer and brain metastases.⁶⁸ Based on these premises, one of the first worldwide trials that incorporates tyrosine kinase inhibitors in the treatment of NM has been initiated (J. Bischoff, personal written communication, October 2008). This multicenter, open-label, single-arm, phase II study assesses the efficacy and safety of oral lapatinib in combination with oral capecitabine and intrathecally

Table 3. Frequency of Central Nervous System Metastases in Relation to Human Epidermal Growth Factor Receptor 2 Overexpression and Survival in Patients With Breast Cancer

First Author, Year	No. of Patients	Patients With CNS Metastases n (%)	Patients With HER2 Overexpressing Tumors (%)	Median Survival (mo)
Bendell, 2003 ¹³	122	42 (34)*	—	13
Lower, 2003 ⁶⁰	87	22 (25)	81	—
Van Pelt, 2003 ⁶¹	22	4 (18)	100	—
Clayton, 2004 ¹⁴	93	23 (25)	94	5.4
Lai, 2004 ⁶²	79	38 (48)†	47	24.9
Shmueli, 2004 ⁶³	32	10 (31)	100	—
Burstein, 2005 ⁵⁵	234	23 (10)‡	100	—
Stemmler, 2006 ⁶⁴	136	42 (31)	100	13
Yau, 2006 ⁶⁵	87	23 (30)	100	4

Abbreviations: CNS, central nervous system; HER, human epidermal growth factor receptor.

*5% with neoplastic meningitis (NM) alone and 14% with NM and parenchymal brain metastases.

†24% with NM.

‡Isolated CNS progression.

administered liposomal cytarabine for the treatment of meningeal and brain metastases in patients with HER2⁺ breast cancer (J. Bischoff, personal written communication, October 2008).

Despite the profound morbidity and the relatively high occurrence of CNS metastases in patients with breast cancer, the priority for patients with very aggressive and unresponsive breast tumors, such as basal-like breast cancers, remains finding therapies that will control the primary systemic cancer. Before a clinical trial assessing the therapeutic benefit of CNS prophylaxis in patients with breast cancer is performed, it is necessary to better identify patients at risk and develop superior regimens and/or therapies to treat CNS metastases from breast cancer.

NM AS A COMPLICATION OF LUNG CANCER

Lung cancer is the leading cause of cancer mortality among both men and women in the United States and is estimated to be responsible for 29% of all cancer deaths in 2008.¹ Mortality is due to end-organ failure caused by metastases, and CNS metastases are a common problem in lung cancer. According to the Metropolitan Detroit Cancer Surveillance System study, the incidence of brain metastases is 19.9% in patients diagnosed with primary lung cancer² and as high as 30% in patients with advanced-stage lung cancer.² As with breast cancer, effective multimodality regimens integrating chemotherapy with radiation therapy and/or surgery have increased the survival of patients with lung cancer. Three-year survival is now possible for patients with metastatic lung cancer, and 1-year survival can reach 50%.⁶⁹ As with breast cancer, the longer patients with lung cancer live, the higher the chance they will develop CNS metastases. Additionally, the

routine use of positron-emission tomography scanning in individuals with lung cancer allows for more precise staging of lung cancer, which should eventually translate into greater survival. MRI screening has become routine in both early-stage and metastatic lung cancer, particularly since the use of the anti-vascular agents, which is anticipated to increase the frequency of early detection of otherwise asymptomatic CNS metastases for patients with metastatic disease.

CNS Metastases in Patients With Non-Small Cell Lung Cancer

As many as 50% to 60% of patients with locally advanced non-small cell lung cancer (NSCLC) will develop CNS metastases during the course of their disease,^{16,70} and the CNS is the first site of recurrence in up to one third of all patients treated with multimodality treatment for stage III NSCLC (Table 4).^{70,71-76}

The treatment of patients with NSCLC has developed substantially over the last 5 years. A large percentage of stage I-III patients with NSCLC are treated with adjuvant chemotherapy. The Radiation Therapy Oncology Group 0139 study also showed that surgery in patients with stage III NSCLC does not affect the outcome for those who receive chemotherapy and radiation first. Furthermore, new drugs, such as bevacizumab and erlotinib for patients with stage IV lung cancer, have extended survival and substantially changed the clinician's practice.

Patients with advanced NSCLC remain difficult to treat and rarely attain a complete response. Conventional platinum-based chemotherapy, including cisplatin plus paclitaxel, gemcitabine or docetaxel, and carboplatin plus paclitaxel, provides only modest survival benefits in patients with advanced NSCLC (median sur-

Table 4. Central Nervous System Metastases as First Site of Failure in Advanced Non-Small Cell Lung Cancer After Multimodality Therapy

First Author, Year	No. of Patients	Patients With CNS Metastases as First Site of Relapse (%)	Percent of Total Relapses
Furuse, 1999 ⁷¹	147	19	
Law, 2001 ⁷²	42	29	
Robnett, 2001 ⁷³	150	19	
Ceresoli, 2002 ⁷⁴	139	22	29
Machtay, 2004 ⁷⁵	53	23	
Gaspar, 2005 ⁷⁶	422	17	26
Mamon, 2005 ⁷⁰	177	34	

Abbreviation: CNS, central nervous system.

vival, 8 months; 1-year survival rate, ~30%).⁷⁷ Several recently developed therapies, including the antiangiogenic drug bevacizumab and the orally administered EGFR inhibitors erlotinib and gefitinib, have improved the outcome of patients with advanced NSCLC. The addition of bevacizumab to standard chemotherapy regimens has increased median survival for metastatic non-squamous NSCLC to greater than 12 months.⁶⁹ The effect of bevacizumab treatment on the incidence of CNS metastases is unclear.

In a recent randomized, placebo-controlled study (N = 731), erlotinib treatment resulted in a response rate of 8.9% among previously treated patients with stage IIIb or stage IV NSCLC.⁷⁸ Overall survival was 6.7 months in the erlotinib group, versus 4.7 months in the placebo group ($P < .001$). In patients with advanced NSCLC who failed to respond to conventional therapy, gefitinib produced response rates ranging from 12% to 18% and a 1-year survival rate of 25%.^{16,79,80} Despite the ability to control systemic cancer, a recent study demonstrated that patients who respond to gefitinib treatment might be at greater risk of developing CNS relapse. Of 21 responders, seven (33%) had CNS metastases as first site of disease progression, with a 5-year actuarial incidence of CNS metastases of 60%.¹⁶ Of note, two (29%) patients with CNS relapses presented with NM. The median survival for patients with CNS disease treated with gefitinib was 15 months, compared with 24 months for patients without CNS disease.¹⁶ Interestingly, some reports have shown that gefitinib may have antitumor activity against CNS metastases from NSCLC at approximately the same frequency as its systemic efficacy.^{74,81,82} For example, 43% of patients with CNS metastases (n = 14) who had received gefitinib for advanced NSCLC achieved an objective response in the CNS, and 50% had extracranial responses.⁸¹ Ceresoli and colleagues prospectively evaluated 41 patients with NSCLC and measurable CNS metastases who were treated with gefitinib.⁷⁴ A partial response in the brain occurred in four patients (10%),

a rate observed in most trials of NSCLC with extracranial disease.⁷⁴

Subgroups of patients who are potential candidates for CNS prophylaxis could be defined by response to systemic therapy. For example, the likelihood of a response to erlotinib in previously treated patients with NSCLC has been shown to be significantly higher in women ($P = .006$), nonsmokers ($P < .001$), Asians ($P = .02$), patients with adenocarcinoma ($P < .001$), and those in whom EGFR was expressed in $\geq 10\%$ of the tumor.⁷⁸ However, the only factors that remained significant in multiple logistic-regression analyses were nonsmokers, adenocarcinoma histology, and EGFR expression.⁷⁸

Identifying High-Risk Patients Who May Be Candidates for CNS Prophylactic Treatment

By combining multiple factors, it may be possible to select a population with a high risk of CNS disease to justify CNS prophylaxis. For example, a clinical study could be conducted to evaluate the efficacy of prophylactic cranial irradiation versus observation in patients on second- or third-line treatment (whose primary tumors are slow-growing) or with low standardized uptake value. A high standardized uptake value is a poor prognostic factor for survival in NSCLC.⁸³ Another potential study could assess the efficacy of liposomal cytarabine versus observation in stage III patients in complete remission who previously received prophylactic cranial irradiation. Alternately, one could combine these strategies and consider a trial of previously treated patients with metastatic NSCLC who have responded to an EGFR inhibitor and treat them with liposomal cytarabine versus observation as a prevention strategy for NM. Finally, high-risk patients who have been identified by CSF screening or other means for the presence of micro-metastasis could also be considered for treatment with liposomal cytarabine (positive CSF) or observation (negative CSF).

Table 5. Incidence (%) of Neoplastic Meningitis After Surgical Resection of Brain Metastases

First Author, Year	No. of Patients With Surgical Resection	Cases of NM n (%)
Norris, 1997 ⁹	N = 66 Posterior fossa metastases: n = 11 Supratentorial metastases: n = 55	4* (36) 1 (2)
van der Ree, 1999 ¹²	N = 27 Posterior fossa, n = 9 Supratentorial metastases, n = 18	6† (67) 3 (17)
Siomin, 2004 ¹⁰	N = 18 Posterior fossa metastases: n = 18	9 (50)
Suki, 2008 ¹¹	N = 260 Posterior fossa metastases: N = 260	26 (10)

Abbreviation: NM, neoplastic meningitis.

*Two additional patients died of progressive neurological disease, and two patients were lost to follow-up.

†In five patients, NM was the only site of recurrence.

CNS Metastases in Patients With SCLC

Approximately 14% to 18% of patients with SCLC have verifiable CNS metastasis (parenchymal and NM) at the initial presentation.^{84,85} After 2 years, the cumulative risk of developing CNS metastases is almost 50% in patients with limited disease and 65% to 80% for those with extensive disease.⁸⁶ The majority of CNS metastases are located in the parenchyma, but NM is not uncommon and occurs in 8% to 18% of all patients with SCLC.⁸⁵⁻⁸⁹ In a prospective study of 458 patients with SCLC, 70% of whom had extensive disease, the prevalence of NM was 2% at diagnosis and 10% at the 2-year follow-up.¹⁵ Most patients with NM had metastases at other CNS locations. Treatment of NM with radiotherapy (if bulky disease, n = 9), systemic chemotherapy (n = 5), or intra-CSF MTX (n = 4) did not influence survival.¹⁵ Because CNS metastases are more common in patients with SCLC, a CNS prevention paradigm can be established, and prophylactic cranial irradiation is recommended for patients with limited disease who have achieved complete response. Prophylactic cranial irradiation has been shown to improve overall survival and quality-adjusted life expectancy^{90,91} and reduces the risk of CNS metastases by approximately 50%.⁹⁰ Similarly, it improves disease-free survival and reduces the incidence of symptomatic metastases in patients with advanced SCLC.⁹² Notwithstanding the clear benefits of prophylactic cranial irradiation, other modalities, including intra-CSF therapy, need to be evaluated for the prevention of this complication. For example, a potential clinical trial could be designed to assess the efficacy of intra-CSF chemotherapies such as MTX, cytarabine, or liposomal cytarabine versus no chemoprophylaxis for the prevention of NM in patients with SCLC. Such a trial could include patients with limited or advanced-stage cancer who are in

remission and have received prophylactic cranial irradiation.

POSTSURGICAL PROPHYLAXIS

There is evidence to suggest that surgical resection of bulky CNS tumors, particularly those in the posterior fossa, increases the risk of developing NM.⁹⁻¹² While surgery for supratentorial metastases only leads to a 2% to 17% incidence of NM, surgery for posterior fossa metastases leads to a 10% to 67% incidence of NM (Table 5).⁹⁻¹² NM is often the only site of recurrence.¹² This raises the question as to whether the increased incidence of NM in posterior fossa metastases is a consequence of surgery or can be explained otherwise.

As indicated above, the location of the lesions could by itself contribute to the development of NM. In one study, patients with CNS metastases located in the posterior fossa were found to be at a higher risk (15%) of developing NM compared with patients with CNS metastases located elsewhere (10%).¹⁵ The increased risk of NM after posterior fossa surgery may be due to close association with subarachnoid space and cisterna magna fossa.^{11,93} However, several reports suggest that the type of surgery of posterior fossa metastases may play an important role in NM.^{10,11} According to these studies, the incidence of NM is significantly higher after surgery than after stereotactic radiosurgery for the treatment of posterior fossa metastases.^{10,11} In a report by Suki and colleagues, 79% of cases of NM occurred after surgical resection of posterior fossa metastases and 19% after stereotactic radiosurgery ($P = .09$).¹¹ Several mechanisms have been proposed that may account for the higher incidence of NM after surgery of posterior fossa metastases, including contamination of the surgical field with tumor cells during surgery.

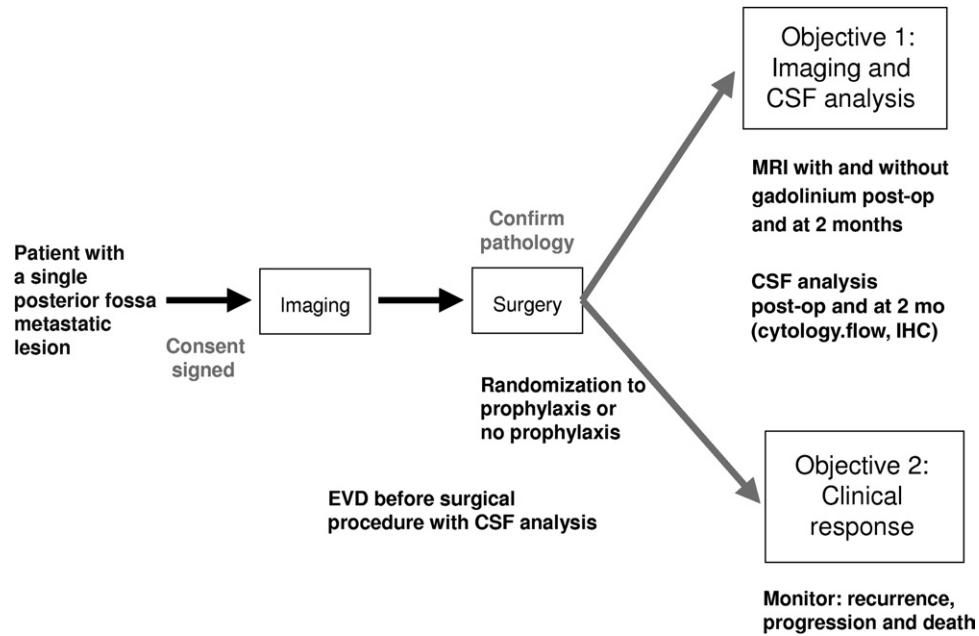


Figure 3. Proposal for a pilot clinical trial assessing whether chemoprophylaxis reduces the incidence of neoplastic meningitis in patients with posterior fossa central nervous system metastases who undergo surgical resection. CSF, cerebrospinal fluid; EVD, extra vascular drainage; IHC, immunohistochemistry; MRI, magnetic resonance imaging.

Piecemeal resection also is associated with a significantly higher rate of NM compared with en bloc resection (relative risk = 2.45; $P = .02$).¹¹ Although the minimal number of tumor cells in the CSF that would be sufficient to cause NM is unknown, preclinical data suggest that the introduction of just 3,000 tumor cells into the CSF can lead to NM.⁹⁴ Thus, a unique opportunity exists to investigate the value of CNS prophylaxis in patients who undergo posterior fossa surgery of isolated metastases by using chemotherapeutic prophylaxis during the perioperative period. An analogy is the use of prophylactic antibiotics for surgical introduction of intracranial ventricular shunts.⁹⁵ A randomized study to determine whether chemotherapy for CNS prophylaxis of NM will reduce the incidence of NM in patients undergoing surgery for posterior fossa metastasis is proposed (Figure 3). End points should include imaging and CSF cytology analyses, as well as clinical outcome measures such as recurrence, progression, or death. Other follow-up monitoring options, such as quantitative reverse transcription polymerase chain reaction, brain and spinal MRI, and immunohistochemistry also may be valuable. MTX, cytarabine, thiotepa, and liposomal cytarabine could be administered either intrathecally via lumbar puncture or Ommaya reservoir, or in the case of MTX and cytarabine, systemically through intravenous infusion at the time of incision. Potentially confounding factors, such as the chemoresistance of some tumors, abnormal CSF flow, and bulky deposits, should be closely evaluated before patient enrollment.

CONCLUSIONS

New and more effective treatment modalities have prolonged the remission and survival of patients with solid tumors, including breast and lung cancer. Because of these improved systemic outcomes, the relative significance of CNS metastases, including NM, has increased dramatically. CNS metastases are sometimes the only site of recurrence and the site that most threatens patients' QoL and the survival of otherwise responsive or stable patients. CNS prophylaxis in subpopulations at risk of CNS relapse and better screening and early diagnosis may improve clinical outcome and survival. The identification and validation of biological markers to predict CNS relapse would allow clinicians to identify patients who may benefit from CNS prophylactic treatment. Clinical trials with clearly defined end points also are needed to test the efficacy and safety of intra-CSF and other CNS prophylaxis in high-risk populations. It is hoped that the proposals in this paper stimulate discussion among clinicians and researchers and lead to the development of protocols for the prevention of NM and CNS metastases from solid tumors.

REFERENCES

1. Jemal A, Siegel R, Ward E, Hao Y, Xu J, Murray T, et al. Cancer statistics, 2008. *CA Cancer J Clin.* 2008;58:71-96.
2. Barnholtz-Sloan JS, Sloan AE, Davis FG, Vignea FD, Lai P, Sawaya RE. Incidence proportions of brain metastases in patients diagnosed (1973 to 2001) in the Metropolitan Detroit Cancer Surveillance System. *J Clin Oncol.* 2004; 22:2865-72.

3. Gleissner G, Chamberlain MC. Neoplastic meningitis. *Lancet Neurol*. 2006;5:443-52.
4. Balm M, Hammack J. Leptomeningeal carcinomatosis. Presenting features and prognostic factors. *Arch Neurol*. 1996;53:626-32.
5. Bruno MK, Raizer J. Leptomeningeal metastases from solid tumors (meningeal carcinomatosis). *Cancer Treat Res*. 2005;125:31-52.
6. Taillibert S, Laigle-Donadey F, Chodkiewicz C, Sanson M, Hoang-Xuan K, Delattre JY. Leptomeningeal metastases from solid malignancy: a review. *J Neurooncol*. 2005;75:85-99.
7. Olson ME, Chernik NL, Posner JB. Infiltration of the leptomeninges by systemic cancer. A clinical and pathologic study. *Arch Neurol*. 1974;30:122-37.
8. Wasserstrom WR, Glass JP, Posner JB. Diagnosis and treatment of leptomeningeal metastases from solid tumors: experience with 90 patients. *Cancer*. 1982;49:759-72.
9. Norris LK, Grossman SA, Olivi A. Neoplastic meningitis following surgical resection of isolated cerebellar metastasis: a potentially preventable complication. *J Neurooncol*. 1997;32:215-23.
10. Siomin VE, Vogelbaum MA, Kanner AA, Lee SY, Suh JH, Barnett GH. Posterior fossa metastases: risk of leptomeningeal disease when treated with stereotactic radiosurgery compared to surgery. *J Neurooncol*. 2004;67:115-21.
11. Suki D, Abouassi H, Patel AJ, Sawaya R, Weinberg JS, Groves MD. Comparative risk of leptomeningeal disease after resection or stereotactic radiosurgery for solid tumor metastasis to the posterior fossa. *J Neurosurg*. 2008;108:248-57.
12. van der Ree TC, Dippel DW, Avezaat CJ, Sillevs Smitt PA, Vecht CJ, van den Bent MJ. Leptomeningeal metastasis after surgical resection of brain metastases. *J Neurol Neurosurg Psych*. 1999;66:225-7.
13. Bendell JC, Domchek SM, Burstein HJ, Harris L, Younger J, Kuter I, et al. Central nervous system metastases in women who receive trastuzumab-based therapy for metastatic breast carcinoma. *Cancer*. 2003;97:2972-7.
14. Clayton AJ, Danson S, Jolly S, Ryder WD, Burt PA, Stewart AL, et al. Incidence of cerebral metastases in patients treated with trastuzumab for metastatic breast cancer. *Br J Cancer*. 2004;91:639-43.
15. Seute T, Leffers P, ten Velde GP, Twijnstra A. Leptomeningeal metastases from small cell lung carcinoma. *Cancer*. 2005;104:1700-5.
16. Omuro AM, Kris MG, Miller VA, Franceschi E, Shah N, Milton DT, Abrey LE. High incidence of disease recurrence in the brain and leptomeninges in patients with nonsmall cell lung carcinoma after response to gefitinib. *Cancer*. 2005;103:2344-8.
17. Patel RR, Mehta MP. Targeted therapy for brain metastases: improving the therapeutic ratio. *Clin Cancer Res*. 2007;13:1675-83.
18. Andrews DW, Scott CB, Sperduto PW, Flanders AE, Gaspar LE, Schell MC, et al. Whole brain radiation therapy with or without stereotactic radiosurgery boost for patients with one to three brain metastases: phase III results of the RTOG 9508 randomised trial. *Lancet*. 2004;363:1665-72.
19. Soffiatti R, Ruda R, Trevisan E. Brain metastases: current management and new developments. *Curr Opin Oncol*. 2008;20:676-84.
20. Jayson GC, Howell A, Harris M, Morgenstern G, Chang J, Ryder WD. Carcinomatous meningitis in patients with breast cancer. An aggressive disease variant. *Cancer*. 1994;74:3135-41.
21. Glantz MJ, Cole BF, Recht L, Akerley W, Mills P, Saris S, et al. High-dose intravenous methotrexate for patients with nonleukemic leptomeningeal cancer: is intrathecal chemotherapy necessary? *J Clin Oncol*. 1998;16:1561-7.
22. Chamberlain MC. Neoplastic meningitis. *Neurologist*. 2006;12:179-87.
23. Yap HY, Yap BS, Rasmussen S, Levens ME, Hortobagyi GN, Blumenschein GR. Treatment for meningeal carcinomatosis in breast cancer. *Cancer*. 1982;50:219-22.
24. Ongerboer de Visser BW, Somers R, Nooyen WH, van Heerde P, Hart AA, McVie JG. Intraventricular methotrexate therapy of leptomeningeal metastasis from breast carcinoma. *Neurology*. 1983;33:1565-72.
25. Hitchins RN, Bell DR, Woods RL, Levi JA. A prospective randomized trial of single-agent versus combination chemotherapy in meningeal carcinomatosis. *J Clin Oncol*. 1987;5:1655-62.
26. Grossman SA, Finkelstein DM, Ruckdeschel JC, Trump DL, Moynihan T, Ettinger DS. Randomized prospective comparison of intraventricular methotrexate and thiotepa in patients with previously untreated neoplastic meningitis. Eastern Cooperative Oncology Group. *J Clin Oncol*. 1993;11:561-9.
27. Glantz MJ, Jaeckle KA, Chamberlain MC, Phuphanich S, Recht L, Swinnen LJ, et al. A randomized controlled trial comparing intrathecal sustained-release cytarabine (DepoCyt) to intrathecal methotrexate in patients with neoplastic meningitis from solid tumors. *Clin Cancer Res*. 1999;5:3394-402.
28. Jaeckle KA, Batchelor T, O'Day SJ, Phuphanich S, New P, Lesser G, et al. An open label trial of sustained-release cytarabine (DepoCyt) for the intrathecal treatment of solid tumor neoplastic meningitis. *J Neurooncol*. 2002;57:231-9.
29. Kim DY, Lee KW, Yun T, Park SR, Jung JY, Kim DW, et al. Comparison of intrathecal chemotherapy for leptomeningeal carcinomatosis of a solid tumor: methotrexate alone versus methotrexate in combination with cytosine arabinoside and hydrocortisone. *Jpn J Clin Oncol*. 2003;33:608-12.
30. Boogerd W, van den Bent MJ, Koehler PJ, Heimans JJ, van der Sande JJ, Aaronson NK, et al. The relevance of intraventricular chemotherapy for leptomeningeal metastasis in breast cancer: a randomised study. *Eur J Cancer*. 2004;40:2726-33.
31. Bokstein F, Lossos A, Siegal T. Leptomeningeal metastases from solid tumors: a comparison of two prospective series treated with and without intra-cerebrospinal fluid chemotherapy. *Cancer*. 1998;82:1756-63.
32. Orlando L, Curigliano G, Colleoni M, Fazio N, Nole F, Martinelli G, et al. Intrathecal chemotherapy in carcinomatous meningitis from breast cancer. *Anticancer Res*. 2002;22:3057-9.
33. Gavrilovic IT, Posner JB. Brain metastases: epidemiology and pathophysiology. *J Neurooncol*. 2005;75:5-14.

34. Patanaphan V, Salazar OM, Risco R. Breast cancer: metastatic patterns and their prognosis. *South Med J*. 1988; 81:1109-12.
35. Tsukada Y, Fouad A, Pickren JW, Lane WW. Central nervous system metastasis from breast carcinoma. Autopsy study. *Cancer*. 1983;52:2349-54.
36. Kesari S, Batchelor TT. Leptomeningeal metastases. *Neurol Clin*. 2003;21:25-66.
37. Jaeckle KA, Phuphanich S, Bent MJ, Aiken R, Batchelor T, Campbell T, et al. Intrathecal treatment of neoplastic meningitis due to breast cancer with a slow-release formulation of cytarabine. *Br J Cancer*. 2001;84:157-63.
38. Wang ML, Yung WK, Royce ME, Schomer DF, Theriault RL. Capecitabine for 5-fluorouracil-resistant brain metastases from breast cancer. *Am J Clin Oncol*. 2001;24:421-4.
39. Fabi A, Vidiri A, Ferretti G, Felici A, Papaldo P, Carlini P, et al. Dramatic regression of multiple brain metastases from breast cancer with capecitabine: another arrow at the bow? *Cancer Invest*. 2006;24:466-8.
40. Tham YL, Hinckley L, Teh BS, Elledge R. Long-term clinical response in leptomeningeal metastases from breast cancer treated with capecitabine monotherapy: a case report. *Clin Breast Cancer*. 2006;7:164-6.
41. Giglio P, Tremont-Lukats IW, Groves MD. Response of neoplastic meningitis from solid tumors to oral capecitabine. *J Neurooncol*. 2003;65:167-72.
42. Rogers LR, Remer SE, Tejwani S. Durable response of breast cancer leptomeningeal metastasis to capecitabine monotherapy. *Neurooncol*. 2004;6:63-4.
43. Capecitabine [package insert]. Nutley, NJ: Roche Laboratories Inc; 2006.
44. Blum JL, Jones SE, Buzdar AU, LoRusso PM, Kuter I, Vogel C, et al. Multicenter phase II study of capecitabine in paclitaxel-refractory metastatic breast cancer. *J Clin Oncol*. 1999;17:485-93.
45. Gaspar L, Scott C, Rotman M, Asbell S, Phillips T, Wasserman T, et al. Recursive partitioning analysis (RPA) of prognostic factors in three Radiation Therapy Oncology Group (RTOG) brain metastases trials. *Int J Radiat Oncol Biol Phys*. 1997;37:745-51.
46. Slimane K, Andre F, Delaloge S, Dunant A, Perez A, Grenier J, et al. Risk factors for brain relapse in patients with metastatic breast cancer. *Ann Oncol*. 2004;15:1640-4.
47. Gabos Z, Sinha R, Hanson J, Chauhan N, Hugh J, Mackey JR, et al. Prognostic significance of human epidermal growth factor receptor positivity for the development of brain metastasis after newly diagnosed breast cancer. *J Clin Oncol*. 2006;24:5658-63.
48. Souglakos J, Vamvakas L, Apostolaki S, Perraki M, Saridaki Z, Kazakou I, et al. Central nervous system relapse in patients with breast cancer is associated with advanced stages, with the presence of circulating occult tumor cells and with the HER2/neu status. *Breast Cancer Res*. 2006;8:R36.
49. Tham YL, Sexton K, Kramer R, Hilsenbeck S, Elledge R. Primary breast cancer phenotypes associated with propensity for central nervous system metastases. *Cancer*. 2006;107:696-704.
50. Hicks DG, Short SM, Prescott NL, Tarr SM, Coleman KA, Yoder BJ, et al. Breast cancers with brain metastases are more likely to be estrogen receptor negative, express the basal cytokeratin CK5/6, and overexpress HER2 or EGFR. *Am J Surg Pathol*. 2006;30:1097-104.
51. Carey LA, Ewend MG, Metzger R, Sawyer L, Dees EC, Sartor CI, et al. Central nervous system metastases in women after multimodality therapy for high risk breast cancer. *Breast Cancer Res Treat*. 2004;88:273-80.
52. Evans AJ, James JJ, Cornford EJ, Chan SY, Burrell HC, Pinder SE, et al. Brain metastases from breast cancer: identification of a high-risk group. *Clin Oncol (R Coll Radiol)*. 2004;16:345-9.
53. Gonzalez-Angulo AM, Cristofanilli M, Strom EA, Buzdar AU, Kau SW, Broglio KR, et al. Central nervous system metastases in patients with high-risk breast carcinoma after multimodality treatment. *Cancer*. 2004;101:1760-6.
54. Ryberg M, Nielsen D, Osterlind K, Andersen PK, Skovsgaard T, Dombernowsky P. Predictors of central nervous system metastasis in patients with metastatic breast cancer. A competing risk analysis of 579 patients treated with epirubicin-based chemotherapy. *Breast Cancer Res Treat*. 2005;91:217-25.
55. Burstein HJ, Lieberman G, Slamon DJ, Winer EP, Klein P. Isolated central nervous system metastases in patients with HER2-overexpressing advanced breast cancer treated with first-line trastuzumab-based therapy. *Ann Oncol*. 2005;16:1772-7.
56. Luck AA, Evans AJ, Green AR, Rakha EA, Paish C, Ellis IO. The influence of basal phenotype on the metastatic pattern of breast cancer. *Clin Oncol (R Coll Radiol)*. 2008; 20:40-5.
57. Nam BH, Kim SY, Han HS, Kwon Y, Lee KS, Kim TH, Ro J. Breast cancer subtypes and survival in patients with brain metastases. *Breast Cancer Res*. 2008;10:R20.
58. Baselga J, Tripathy D, Mendelsohn J, Baughman S, Benz CC, Dantis L, et al. Phase II study of weekly intravenous recombinant humanized anti-p185HER2 monoclonal antibody in patients with HER2/neu-overexpressing metastatic breast cancer. *J Clin Oncol*. 1996;14:737-44.
59. Slamon DJ, Leyland-Jones B, Shak S, Fuchs H, Paton V, Bajamonde A, et al. Use of chemotherapy plus a monoclonal antibody against HER2 for metastatic breast cancer that overexpresses HER2. *N Engl J Med*. 2001;344: 783-92.
60. Lower EE, Drosick DR, Blau R, Brennan L, Danneman W, Hawley DK. Increased rate of brain metastasis with trastuzumab therapy not associated with impaired survival. *Clin Breast Cancer*. 2003;4:114-9.
61. Van Pelt AE, Mohsin S, Elledge RM, Hilsenbeck SG, Gutierrez MC, Lucci A Jr, et al. Neoadjuvant trastuzumab and docetaxel in breast cancer: preliminary results. *Clin Breast Cancer*. 2003;4:348-53.
62. Lai R, Dang CT, Malkin MG, Abrey LE. The risk of central nervous system metastases after trastuzumab therapy in patients with breast carcinoma. *Cancer*. 2004;101:810-6.
63. Shmueli E, Wigler N, Inbar M. Central nervous system progression among patients with metastatic breast cancer responding to trastuzumab treatment. *Eur J Cancer*. 2004;40:379-82.
64. Stemmler HJ, Kahlert S, Siekiera W, Untch M, Heinrich B, Heinemann V. Characteristics of patients with brain metastases receiving trastuzumab for HER2 overexpressing metastatic breast cancer. *Breast*. 2006;15:219-25.

65. Yau T, Swanton C, Chua S, Sue A, Walsh G, Rostom A, et al. Incidence, pattern and timing of brain metastases among patients with advanced breast cancer treated with trastuzumab. *Acta Oncol.* 2006;45:196-201.
66. Geyer CE, Forster J, Lindquist D, Chan S, Romieu CG, Pienkowski T, et al. Lapatinib plus capecitabine for HER2-positive advanced breast cancer. *N Engl J Med.* 2006;355:2733-43.
67. Cameron D, Casey M, Press M, Lindquist D, Pienkowski T, Romieu CG, et al. A phase III randomized comparison of lapatinib plus capecitabine versus capecitabine alone in women with advanced breast cancer that has progressed on trastuzumab: updated efficacy and biomarker analyses. *Breast Cancer Res Treat.* 2008;112:533-43.
68. Lin NU, Carey LA, Liu MC, Younger J, Come SE, Ewend M, et al. Phase II trial of lapatinib for brain metastases in patients with human epidermal growth factor receptor 2-positive breast cancer. *J Clin Oncol.* 2008;26:1993-9.
69. Sandler A, Gray R, Perry MC, Brahmer J, Schiller JH, Dowlati A, et al. Paclitaxel-carboplatin alone or with bevacizumab for non-small-cell lung cancer. *N Engl J Med.* 2006;355:2542-50.
70. Mamon HJ, Yeap BY, Janne PA, Reblando J, Shrager S, Jaklitsch MT, et al. High risk of brain metastases in surgically staged IIIA non-small-cell lung cancer patients treated with surgery, chemotherapy, and radiation. *J Clin Oncol.* 2005;23:1530-7.
71. Furuse K, Fukuoka M, Kawahara M, Nishikawa H, Takada Y, Kudoh S, et al. Phase III study of concurrent versus sequential thoracic radiotherapy in combination with mitomycin, vindesine, and cisplatin in unresectable stage III non-small-cell lung cancer. *J Clin Oncol.* 1999;17:2692-9.
72. Law A, Karp DD, Dipetrillo T, Daly BT. Emergence of increased cerebral metastasis after high-dose preoperative radiotherapy with chemotherapy in patients with locally advanced nonsmall cell lung carcinoma. *Cancer.* 2001;92:160-4.
73. Robnett TJ, Machtay M, Stevenson JP, Algazy KM, Hahn SM. Factors affecting the risk of brain metastases after definitive chemoradiation for locally advanced non-small-cell lung carcinoma. *J Clin Oncol.* 2001;19:1344-9.
74. Ceresoli GL, Reni M, Chiesa G, Carretta A, Schipani S, Passoni P, et al. Brain metastases in locally advanced nonsmall cell lung carcinoma after multimodality treatment: risk factors analysis. *Cancer.* 2002;95:605-12.
75. Machtay M, Lee JH, Stevenson JP, Shrager JB, Algazy KM, Treat J, Kaiser LR. Two commonly used neoadjuvant chemoradiotherapy regimens for locally advanced stage III non-small cell lung carcinoma: long-term results and associations with pathologic response. *J Thorac Cardiovasc Surg.* 2004;127:108-13.
76. Gaspar LE, Chansky K, Albain KS, Vallieres E, Rusch V, Crowley JJ, et al. Time from treatment to subsequent diagnosis of brain metastases in stage III non-small-cell lung cancer: a retrospective review by the Southwest Oncology Group. *J Clin Oncol.* 2005;23:2955-61.
77. Schiller JH, Harrington D, Belani CP, Langer C, Sandler A, Krook J, et al. Comparison of four chemotherapy regimens for advanced non-small-cell lung cancer. *N Engl J Med.* 2002;346:92-8.
78. Shepherd FA, Rodrigues Pereira J, Ciuleanu T, Tan EH, Hirsh V, Thongprasert S, et al. Erlotinib in previously treated non-small-cell lung cancer. *N Engl J Med.* 2005;353:123-32.
79. Kris MG, Natale RB, Herbst RS, Lynch TJ Jr, Prager D, Belani CP, et al. Efficacy of gefitinib, an inhibitor of the epidermal growth factor receptor tyrosine kinase, in symptomatic patients with non-small cell lung cancer: a randomized trial. *JAMA.* 2003;290:2149-58.
80. Fukuoka M, Yano S, Giaccone G, Tamura T, Nakagawa K, Douillard JY, et al. Multi-institutional randomized phase II trial of gefitinib for previously treated patients with advanced non-small-cell lung cancer (The IDEAL 1 Trial) [corrected]. *J Clin Oncol.* 2003;21:2237-46.
81. Hotta K, Kiura K, Ueoka H, Tabata M, Fujiwara K, Kozuki T, et al. Effect of gefitinib ('Iressa', ZD1839) on brain metastases in patients with advanced non-small-cell lung cancer. *Lung Cancer.* 2004;46:255-61.
82. Shimato S, Mitsudomi T, Kosaka T, Yatabe Y, Wakabayashi T, Mizuno M, et al. EGFR mutations in patients with brain metastases from lung cancer: association with the efficacy of gefitinib. *Neurooncol.* 2006;8:137-44.
83. Berghmans T, Dusart M, Paesmans M, Hossein-Foucher C, Buvat I, Castaigne C, et al. Primary tumor standardized uptake value (SUVmax) measured on fluorodeoxyglucose positron emission tomography (FDG-PET) is of prognostic value for survival in non-small cell lung cancer (NSCLC): a systematic review and meta-analysis (MA) by the European Lung Cancer Working Party for the IASLC Lung Cancer Staging Project. *J Thorac Oncol.* 2008;3:6-12.
84. Hochstenbag MM, Twijnstra A, Wilmink JT, Wouters EF, ten Velde GP. Asymptomatic brain metastases (BM) in small cell lung cancer (SCLC): MR-imaging is useful at initial diagnosis. *J Neurooncol.* 2000;48:243-8.
85. Seute T, Leffers P, ten Velde GP, Twijnstra A. Neurologic disorders in 432 consecutive patients with small cell lung carcinoma. *Cancer.* 2004;100:801-6.
86. Nugent JL, Bunn PA Jr, Matthews MJ, Ihde DC, Cohen MH, Gazdar A, et al. CNS metastases in small cell bronchogenic carcinoma: increasing frequency and changing pattern with lengthening survival. *Cancer.* 1979;44:1885-93.
87. Rosen ST, Aisner J, Makuch RW, Matthews MJ, Ihde DC, Whitacre M, et al. Carcinomatous leptomeningitis in small cell lung cancer: a clinicopathologic review of the National Cancer Institute experience. *Medicine.* 1982;61:45-53.
88. Aisner J, Ostrow S, Govindan S, Wiernik PH. Leptomeningeal carcinomatosis in small cell carcinoma of the lung. *Med Pediatr Oncol.* 1981;9:47-59.
89. Aroney RS, Dalley DN, Chan WK, Bell DR, Levi JA. Meningeal carcinomatosis in small cell carcinoma of the lung. *Am J Med.* 1981;71:26-32.
90. Auperin A, Arriagada R, Pignon JP, Le Pechoux C, Gregor A, Stephens RJ, et al. Prophylactic cranial irradiation for patients with small-cell lung cancer in complete remission. Prophylactic Cranial Irradiation Overview Collaborative Group. *N Engl J Med.* 1999;341:476-84.
91. Lee JJ, Bekele BN, Zhou X, Cantor SB, Komaki R, Lee JS. Decision analysis for prophylactic cranial irradiation for

- patients with small-cell lung cancer. *J Clin Oncol*. 2006; 24:3597-603.
92. Slotman B, Faivre-Finn C, Kramer G, Rankin E, Snee M, Hatton M, et al. Prophylactic cranial irradiation in extensive small-cell lung cancer. *N Engl J Med*. 2007;357: 664-72.
93. Mirimanoff RO, Choi NC. Intradural spinal metastases in patients with posterior fossa brain metastases from various primary cancers. *Oncology*. 1987;44:232-6.
94. Phillips PC, Than TT, Cork LC, Hilton J, Carson BS, Colvin OM, Grochow LB. Intrathecal 4-hydroperoxycyclophosphamide: neurotoxicity, cerebrospinal fluid pharmacokinetics, and antitumor activity in a rabbit model of VX2 leptomeningeal carcinomatosis. *Cancer Res*. 1992;52:6168-74.
95. Ratilal B, Costa J, Sampaio C. Antibiotic prophylaxis for surgical introduction of intracranial ventricular shunts. *Cochrane Database Syst Rev (Online)*. 2006;3:CD005365.