

Treatment of recurrent high-grade gliomas

Myrna R. Rosenfeld, MD, PhD, Karen Albright, CRNP, and Amy A. Pruitt, MD

University of Pennsylvania School of Medicine, Philadelphia, PA

Despite treatment, glioblastoma (GB) inevitably recurs, and there is often no clear standard of care to follow. This article reviews the treatment options for recurrent GB and anaplastic gliomas. The three FDA-approved treatments for recurrent GB are biodegradable carmustine-impregnated wafers; bevacizumab; and the NovoTTF-100A System, which delivers low-intensity, alternating electrical fields to the tumor bed. Treatment decisions must take into consideration prior therapies, the extent and location of recurrence, and the patient's general medical condition, as well as the rapidity of tumor growth, extent of edema, mass effect, need for steroids, and symptoms. New treatment strategies are emerging based on the identification of prognostic and predictive markers and defining distinct molecular subtypes of GB.

Glioblastoma (grade IV glioma, GB) is the most common of the primary malignant gliomas. Advances in the past decade have clarified that adjuvant treatment can improve quality of life and survival. The current standard of care for newly diagnosed patients with GB after optimal resection is focal radiation with concurrent (chemoradiation) and post-radiation temozolomide (Temodar). This regimen was shown to improve overall survival in a randomized phase III study.¹ Furthermore, a subgroup of patients whose tumors were shown to have low levels of O⁶-methylguanine DNA methyltransferase (MGMT), the enzyme that repairs DNA damage due to temozolomide, showed overall survival of 46% at 2 years and 14% at 5 years.^{2,3}

Biodegradable wafers impregnated with carmustine (Gliadel) implanted at the time of resection are another approved therapy for patients with newly diagnosed high-grade gliomas (GB and anaplastic gliomas, grade III glioma).⁴ Although short-term survivals for GB patients are similar with Gliadel compared to focal radiation with concurrent and post-radiation temozolomide, the latter results in superior long-term survival (1.9% at 56 months for Gliadel and 9.8% at 60 months for temozolomide).^{3,5} The nitrosoureas lomustine (CeeNU) and carmustine (BiCNU) were approved in the 1970s for use as single agents or in combination therapy in patients with glioma who had received surgery and/or radiation. These agents no longer have a clear role in the initial treatment of malignant glioma, although practitioners use them, often in combination therapy, for patients with recurrent GB and anaplastic oligo-

dendrogliomas, a chemosensitive subtype of glioma.⁶

Despite the use of the above approved therapies, GB invariably recurs. In the absence of effective treatment options, treatment approaches for recurrent GB have been varied. This article will review the most common accepted treatment options for recurrent GB and discuss emerging strategies. In the absence of a clear standard of care for newly diagnosed anaplastic gliomas, treatment at recurrence is largely dictated by prior therapies received, as noted below.

Tumor progression or treatment effect?

Glioblastoma recurrence is suspected when a previously stable patient develops recurrent or new neurologic signs and symptoms or when surveillance imaging (preferably MRI with gadolinium) shows increased tumor size or new enhancement likely associated with increased edema. However, clinical and imaging changes may result from perioperative complications such as infection or ischemia, a change in steroid use, or radiation necrosis (also called pseudoprogression). In fact, studies have shown that up to half of patients with presumed early tumor progression during or after chemoradiation actually have radiation necrosis (Figure 1).⁷ These data have led some clinicians to suggest that a minimum of 3 cycles of adjuvant temozolomide be given before a conclusion of tumor progression is made.

Manuscript received December 1, 2010; accepted April 15, 2011.

Correspondence to: Myrna R. Rosenfeld, MD, PhD, Department of Neurology, 3 W. Gates, University of Pennsylvania, 3400 Spruce Street, Philadelphia, PA 19104; telephone: 215-746-2820; fax: 215-746-2818; e-mail: myrna.rosenfeld@uphs.upenn.edu.

Commun Oncol 2010;8:171-177 © 2011 Elsevier Inc. All rights reserved.

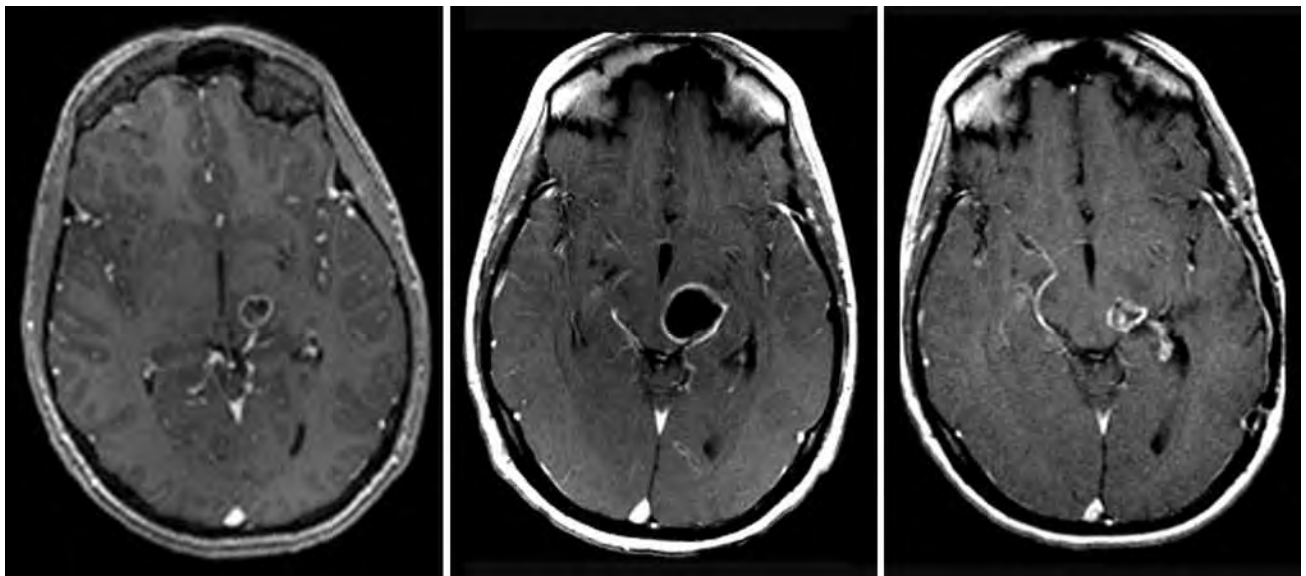


FIGURE 1 Pseudoprogression after chemoradiation. MRI of a biopsy-proven grade III astrocytoma before treatment (**left panel**). Three weeks after completion of chemoradiation, there is an increase in the size of the cystic component and enhancement (**middle panel**), which could be interpreted as tumor progression. After 4 cycles of post-radiation temozolomide, the **right panel** shows a decrease in size and enhancement, supporting the earlier imaging changes as reflective of pseudoprogression. All images are T1 post gadolinium with a 1.5 Tesla magnet.

Several imaging modalities, such as magnetic resonance perfusion with or without spectroscopy and positron emission tomography, are used to help distinguish tumor recurrence from pseudoprogression but are not always reliable.⁸ In these cases, repeat imaging can be useful, although surgery may be necessary to relieve mass effect and obtain a tissue diagnosis.

Approved therapies for recurrent glioblastoma

There are currently three US Food and Drug Administration (FDA)-approved therapies for recurrent GB: Gliadel wafers; bevacizumab (Avastin), a humanized monoclonal antibody that sequesters vascular endothelial growth factor-A (VEGF); and the NovoTTF-100A System (NovoCure; Portsmouth, NH), which delivers low-intensity, alternating electrical fields (called tumor treatment fields) to the tumor bed that may inhibit cell growth by disrupting microtubule formation.⁹

The prospective randomized study that led to the approval of Gliadel demonstrated a modest increase in overall survival, from 23 weeks in

those patients who received placebo wafers to 31 weeks for those receiving Gliadel.⁴ This study included recurrent anaplastic gliomas and GB, and the benefit in the GB subgroup was smaller than in the group as a whole. Furthermore, this and other studies predated the use of chemoradiation and adjuvant temozolomide, and it is unclear what benefit, if any, Gliadel offers in recurrent GB patients treated with prior temozolomide.

The approval of bevacizumab for recurrent GB in the United States was based on two clinical trials that evaluated bevacizumab as a single agent or combined with irinotecan in patients with tumor recurrence after initial treatment with chemoradiation and adjuvant temozolomide. The comparative study enrolled 167 patients, 85 in the bevacizumab-alone arm and 82 in the bevacizumab plus irinotecan arm.¹⁰ The objective response rate was 25.9% in patients who received bevacizumab monotherapy. There were no complete responses per outside review. The median duration of response was 4.2 months, and the 6-month progression-free survival (PFS-6) was 36.0%. The single-arm study enrolled 56 patients with re-

current high-grade glioma.¹¹ Objective response as determined by independent review was 19.6%. The median duration of response was 3.9 months.

The FDA approved bevacizumab for use as a single agent based on the improvement in objective response rate in these studies (albeit without improvement in disease-related symptoms or increased survival) and on the fact that patients receiving bevacizumab as a single agent had less toxicity than those receiving the combination with irinotecan and similar outcomes. Subsequent studies with bevacizumab as a single agent in recurrent GB have shown similar PFS-6 rates of between 29% and 42%; smaller studies in recurrent anaplastic gliomas reported response rates ranging between 34% and 68% and PFS-6 rates ranging between 32% and 68%.^{12,13}

The NovoTTF-100A System received approval in the spring of 2011 based on the results of a single multinational study of 237 patients with recurrent GB.¹⁴ Patients were randomized to receive either the NovoTTF-100A System or chemotherapy of their physician's choice. The NovoTTF device includes a battery pack

(weighing about 6 pounds) and electrodes, which are placed on the scalp and designed to be worn for about 20 hours a day. The results showed that patients who used the NovoTTF-100A System had higher objective response rates (12% for NovoTTF compared with 6% in the chemotherapy group) and a favorable overall survival rate of 6.6 months compared with 6.0 months for the chemotherapy group. The device was well tolerated, with a significantly higher incidence of toxicities (hematologic and other) in the patients receiving chemotherapy.

Temozolomide is approved in Europe for recurrent high-grade gliomas, including both GB and anaplastic astrocytoma, but in the United States, it is only approved for recurrent anaplastic astrocytoma. These approvals were based on studies in mostly chemotherapy-naïve patients, and although it is less clear that rechallenge with temozolomide is useful, as noted below, ongoing studies may clarify this issue.

Approach to the patient with recurrent GB

In the absence of enrollment in a clinical trial, which is encouraged for all glioma patients, the approach to the patient with recurrent GB should take into consideration prior therapies, extent of recurrence and location, and general medical condition. An initial consideration is whether the patient is a candidate for further resection and/or radiation. Re-resection can relieve mass effect and reduce the need for steroids, can provide histologic confirmation of the diagnosis, and likely can increase survival, although this has not been shown in randomized studies.¹⁵ For a patient with contraindications for further systemic chemotherapy and who is undergoing resection, Gliadel is a reasonable consideration, and it does not preclude use of bevacizumab or NovoTTF.

Re-irradiation with single-fraction or fractionated stereotactic radiation

is feasible in patients with localized recurrent disease. Small, single-arm prospective studies and retrospective reviews suggest a benefit, and the focused delivery modalities reduce the dose to surrounding brain tissue, minimizing the risk of radiation toxicity.¹⁶ In some studies, low-dose temozolomide or bevacizumab was combined with re-irradiation with results suggesting both tolerability and efficacy.¹⁷ We have found re-irradiation to be a good alternative for those patients who develop profound and prolonged myelosuppression (usually thrombocytopenia) during initial treatment with temozolomide and who have tumor progression before recovery of the counts.

Bevacizumab is currently the most common single agent used for glioma recurrence and is usually dosed at 10 mg/kg every 2 weeks until disease progression, unacceptable toxicity, or the decision to discontinue care. Due to its potent anti-VEGF activity, which results in normalization of highly permeable tumor vessels, bevacizumab often produces rapid and marked reduction in edema and contrast enhancement on neuroimaging.¹⁸ This can produce rapid clinical and imaging responses, although whether this reflects true anti-glioma activity remains under debate.

Resolution of mass effect and contrast enhancement can also coexist with progression of nonenhancing fluid-attenuated recovery (FLAIR) abnormality that reflects a phenotypically invasive tumor recurrence pattern, with GB co-option of normal cerebral vessels and diffuse, multilobar perivascular spread of tumor cells. The imaging changes can make evaluation of tumor response and progression difficult if one relies on the standard criteria of two-dimensional measurement of enhancing disease; new criteria that take into consideration nonenhancing signal abnormality changes have been proposed.¹⁹

Bevacizumab is well tolerated in the brain tumor population, with the same spectrum of side effects seen in

other cancer populations (hemorrhage, thrombosis, hypertension, bowel perforation, impaired wound healing, and proteinuria).^{12,13} The incidence of life-threatening events, such as significant intracranial hemorrhage (3%) or thromboembolism (2%–12%), is within the expected range for the population and is not clearly increased by bevacizumab.¹²

Several small series have reported that corticosteroid reductions were feasible in 33%–59% of patients with recurrent GB after bevacizumab treatment, and others have reported average corticosteroid dose reductions of 72% and 59%.^{11,13} This is an important benefit of bevacizumab, as chronic or high-dose corticosteroid use in patients with glioma is associated with significant morbidity. The ability of bevacizumab to control edema confounds the definition of tumor progression. Figure 2 shows a patient who had early neurologic improvement after initiation of bevacizumab and then remained clinically stable without corticosteroids over 14 months of therapy, despite slow continuous growth of the tumor mass.

Bevacizumab is also tolerated by older patients; there is an intriguing study suggesting that not only do older patients tolerate bevacizumab, they may also have increased benefit over younger patients (age separation: younger than 55 years or 55 years and older).²⁰

Another option for some patients, prior to bevacizumab, is rechallenge with temozolomide at alternative dosing schedules, which result in prolonged exposure to higher cumulative doses than that achieved by standard 5-day dosing.²¹ Resistance to temozolomide occurs through direct repair of DNA by MGMT; a proposed mechanism to overcome resistance would be to deplete tumor-cell MGMT. Several studies have shown that prolonged exposure of peripheral blood mononuclear cells results in depletion of MGMT, and it has been

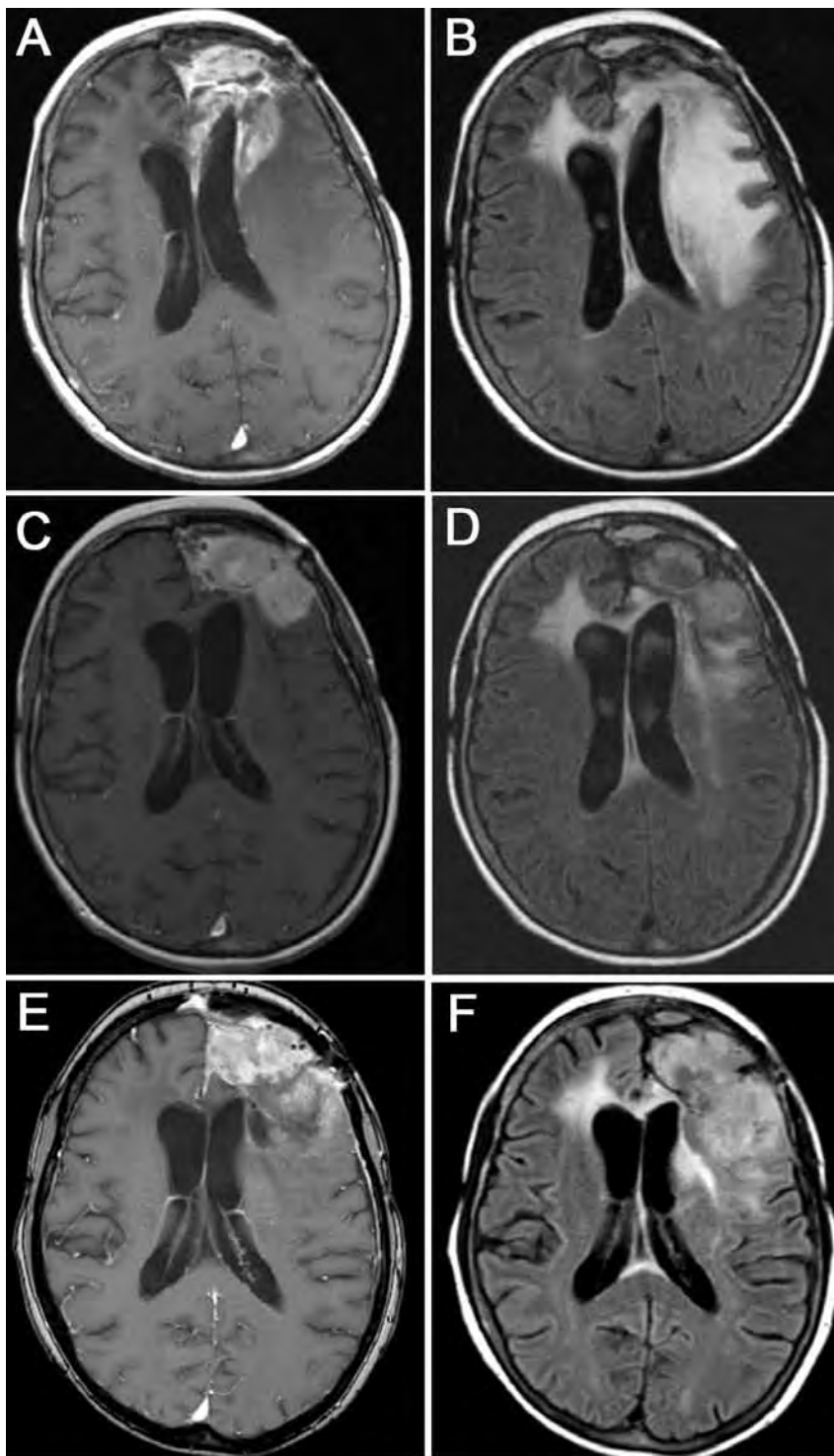


FIGURE 2 Imaging changes with bevacizumab. This 57-year-old woman presented with a second recurrence of glioblastoma 2 years after chemoradiation and 6 cycles of adjuvant temozolomide and 6 months after 8 cycles of low-dose temozolomide. The images show post-contrast T1-weighted sequences (**A, C, E**) and fluid-attenuated recovery (FLAIR) sequences (**B, D, F**). Baseline images (**A, B**) show a left frontal mass with enhancement, edema, and some mass effect. Eight months later, after 4 cycles of bevacizumab (dosed every 2 weeks with 3 doses per cycle), there is decreased periventricular enhancement and edema (**C**) and improved FLAIR signal (**D**) but enlargement of the enhancing left frontal mass, which would meet standard definitions of tumor progression. The patient was neurologically stable and remained on treatment. Nine months later, after 5 additional cycles, she remained neurologically stable (and was not receiving corticosteroids). At this time, the mass has continued to increase in size (note: there is also invasion of the frontal sinus; **E**), with increasing FLAIR abnormality, likely reflecting a progressive infiltrating nonenhancing tumor (**F**).

suggested that this could also occur in glioma cells.²² Other studies suggest that prolonged exposure to temozolomide may be directly toxic to endothelial cells.²³ These data provide a rationale for temozolomide rechallenge

using alternative dose and dosing schedules that deliver higher cumulative doses over prolonged periods.

Commonly tried temozolomide schedules have been 21 days on/7 days off at doses of 75–100 mg/m², 7 days

on/7 days off at a dose of 150 mg/m², and continuous daily dosing at 50 mg/m² (Table 1). These schedules were well tolerated in these pretreated patients, with cumulative leukopenia after several cycles. Results have shown

PFS-6 of 23%–48% with a suggestion (not supported by all studies) that best responses are seen in patients who were rechallenged after a treatment-free interval (from standard adjuvant temozolomide).^{24–27} Responses were also similar in patients with high and low levels of tumor MGMT, suggesting that these regimens may overcome MGMT-mediated resistance.²⁸

In addition to bevacizumab and temozolomide, lomustine, carmustine, irinotecan, cisplatin, and carboplatin have shown modest efficacy in studies as single agents or in combination regimens.^{29–31} The populations in these studies usually included both recurrent GB and anaplastic tumors, including oligodendrogliomas, and were carried out prior to standard use of chemoradiation and adjuvant temozolomide. Thus, it is difficult to extrapolate how these results would translate into today's patient population. Interestingly, in a recent randomized phase III trial of recurrent GB (after prior temozolomide), lomustine was found to be superior to the investigational pan-VEGF receptor inhibitor cediranib.³²

As noted, the NovoTTF-100A System was only recently approved, and experience is limited. Despite the need for patients to wear the device for 20 hours a day, and for intermittent adjustments to electrode placement at a clinic site, patient compliance in the study was good, and toxicities were minimal. It is clearly an option for patients with recurrent GB, but additional experience is needed to clarify the optimal time of use. The device is currently under study for the treatment of newly diagnosed GB; results of this study may help clarify the role of NovoTTF in treating this malignancy.

In deciding which of the above strategies to use at first or even subsequent recurrences, we take into consideration the rapidity of tumor growth, extent of edema, mass effect, need for corticosteroids, and symptoms. Furthermore, to date there are no agents that improve outcomes when com-

TABLE 1**Recurrent glioblastoma and temozolomide rechallenge**

Reference	PFS-6, % ^a	Temozolomide regimen
Wick et al, 2009 ²⁴	27.7	<ul style="list-style-type: none"> • 150 mg/m² on days 1–7 and 15–21 of a 28-day cycle • 75 mg/m² on days 1–21 of a 28-day cycle • 40 mg/d continuous
Perry et al, 2010 ²⁵	23.9	50 mg/m ² /d continuous
Wick et al, 2004 ²⁶	48.0	150 mg/m ² on days 1–7 and 15–21 of a 28-day cycle
Brandes et al, 2006 ²⁷	30.3	75 mg/m ² on days 1–21 of a 28-day cycle
Wick et al, 2007 ²⁸	43.8	150 mg/m ² on days 1–7 and 15–21 of a 28-day cycle

^aSix-month progression-free survival is for the entire cohort of glioblastoma patients. Some studies also provided results of cohorts stratified according to the timing of tumor progression during or after initial adjuvant therapy with chemoradiation and adjuvant temozolomide.

bined with bevacizumab or used after relapse on bevacizumab. This is often the last treatment regimen many patients receive before palliative end-of-life care. Thus, for a patient with a small, asymptomatic recurrence found on surveillance imaging and in the absence of an available clinical trial, we initiate therapy with any of the above-mentioned standard chemotherapeutic agents. At tumor progression and if chemotherapy is still tolerated, another agent may be tried. In contrast, the patient with a rapidly growing, large, or symptomatic recurrence requiring increasing doses of steroids will usually have an immediate clinical benefit from bevacizumab, which will improve quality of life.

Recurrent anaplastic gliomas

There is less consensus on how to treat anaplastic gliomas (anaplastic astrocytoma, anaplastic oligodendroglioma, and mixed anaplastic oligoastrocytoma) at initial diagnosis and therefore even more variability in how these patients are treated at recurrence. The study that showed the benefit of chemoradiation and adjuvant temozolomide for newly diagnosed GB excluded patients with anaplastic tumors.¹ A meta-analysis of clinical trials included adults with high-grade glioma who after initial surgery were treated with radiation plus chemotherapy

(most often a nitrosourea) or radiation. The results only suggested that chemotherapy provided an additional survival benefit over radiotherapy alone for both GB and anaplastic patients.

Many cite the above data as the rationale for including temozolomide in the initial treatment of anaplastic tumors.³³ Others, however, cite the results of NOA-04, a large study of patients with anaplastic glioma randomized to receive initial therapy with radiation or one of two chemotherapy regimens: procarbazine (Matulane), lomustine, and vincristine (PCV) or temozolomide.³⁴ At tumor progression, patients who had received radiation were treated with either PCV or temozolomide, and those initially treated with either chemotherapy regimen were irradiated. This study demonstrated no difference in time to treatment failure or PFS among the three groups or any significant difference between the two chemotherapy regimens. Patients with anaplastic astrocytomas fared worse than those with anaplastic oligodendrogliomas or mixed tumors, suggesting that the latter groups may do well with initial chemotherapy only and then radiation at recurrence.

For patients with anaplastic tumors who have not previously been treated with temozolomide, studies do suggest that its use at recurrence is beneficial. In one phase II study, temozolomide-naïve patients, or those who

had previously received a nitrosourea, showed a 35% overall response rate and PFS-6 of 46% when treated with temozolomide at first recurrence.³⁵ A recent study (RESCUE) evaluating a continuous low-dose temozolomide regimen of 50 mg/m² in recurrent GB and anaplastic tumors demonstrated a PFS-6 of 35.7% for the anaplastic subgroup that contained patients who had previously had a variety of initial therapies, including chemoradiation.²⁵

With the knowledge that the presence of chromosome 1p/19q codeletions in anaplastic tumors is prognostic for better outcomes,³⁶ two ongoing studies will hopefully provide definitive answers for the treatment of recurrent anaplastic gliomas. The Chemoradiation and Adjuvant Temozolomide in Non-deleted Anaplastic Tumors (CATNON) study will randomly assign patients after surgery to receive either chemoradiation or radiation alone. Following this therapy, there is a second randomization to adjuvant temozolomide or observation only. The trial endpoint is overall survival. The phase III intergroup study of radiotherapy versus temozolomide alone versus radiotherapy with concomitant and adjuvant temozolomide for patients with 1p/19q codeleted anaplastic glioma (CODEL) will determine whether these patients with inherently better outcomes may do just as well with less aggressive therapy.

Several studies of bevacizumab have included recurrent anaplastic gliomas. Two studies of the combination of bevacizumab and irinotecan produced response rates of 55%–66% and PFS-6 of 56%–61%, suggesting activity.^{12,37} Extrapolating from the GB data, it is likely that single-agent bevacizumab would be efficacious and less toxic than this combination.

Emerging strategies

The identification of prognostic and predictive markers is paving the way for individualized treatment

planning. In addition to the prognostic value of 1p/19q codeletions in anaplastic gliomas, the presence of MGMT promoter methylation in GB is likely predictive of response to temozolomide, although this is still under debate. There has been recent excitement about the demonstration that the presence of mutated isocitrate dehydrogenase 1 (IDH1) in gliomas is a robust independent factor associated with better outcome.³⁸ For example, in a series of patients with anaplastic glioma, patients with the IDH1 mutation had a median survival four times longer than that of those without the mutation (81.1 months vs 19.4 months).³⁹ This raises the question of the role of mutated IDH1 in glioma biology and makes it a potentially valuable therapeutic target.

Ongoing gene-expression profiling studies are showing that histologically indistinguishable GB can be clustered into distinct molecular subtypes, with widely different outcomes and responses to treatment.⁴⁰ This likely contributed to the failure of past clinical trials, as the populations under study were, in fact, too diverse; potentially efficacious agents for one or more subtypes may have been overlooked. These studies are also identifying novel cellular targets such as MET, fibroblast growth factor receptor (FGFR), heat shock protein-90 (HSP-90), and hypoxia-inducible factor 1 α (HIF1 α).⁴¹ Other research is focusing on targets involved in glioma migration and invasion such as tenascin, the Src family of nonreceptor tyrosine kinases, the Rho family of small GTPases, and integrins. The role of glioma stem cells in glioma development and resistance to therapy is another emerging area of study and has led to the identification of specific glioma stem cell targets such as Notch and Sonic hedgehog.⁴²

Conclusion

High-grade gliomas are challenging to treat, and there is often no clear

standard of care. The Glioma Outcomes Project tracked clinical practice patterns and outcomes among North American patients with malignant glioma between 1997 and 2000.⁴³ The results showed that patients treated at academic centers were significantly more likely to receive chemotherapy or radiation therapy, to participate in clinical trials, and to have longer survival times than those treated at community centers. Whether these results would be the same today, with the routine use of temozolomide and bevacizumab, is unclear, but they do support referral of these patients to centers with multispecialty clinics. This is, however, not always feasible, and patients may choose to stay close to home.

For patients with recurrent high-grade gliomas, there are several available therapeutic options, including operation, irradiation, and additional systemic therapies, which are available at most centers. Although the optimal sequence in which therapies should be given has not been clarified, these treatments can delay the onset of neurologic deficits and result in improved quality of life and likely prolonged survival. Additionally, the appropriate management of comorbidities such as seizures and brain edema is essential, and several pertinent reviews are available.^{44,45}

References

1. Stupp R, Mason WP, van den Bent MJ, et al. Radiotherapy plus concomitant and adjuvant temozolomide for glioblastoma. *N Engl J Med* 2005;352:987–996.
2. Hegi ME, Diserens AC, Gorlia T, et al. MGMT gene silencing and benefit from temozolomide in glioblastoma. *N Engl J Med* 2005;352:997–1003.
3. Stupp R, Hegi ME, Mason WP, et al. Effects of radiotherapy with concomitant and adjuvant temozolomide versus radiotherapy alone on survival in glioblastoma in a randomised phase III study: 5-year analysis of the EORTC-NCIC trial. *Lancet Oncol* 2009;10:459–466.
4. Brem H, Piantadosi S, Burger PC, et al. Placebo-controlled trial of safety and efficacy of intraoperative controlled delivery by biodegradable polymers of chemotherapy for recurrent gliomas. *The Polymer-Brain Tumor Treat-*

ment Group. *Lancet* 1995;345:1008–1012.

5. Westphal M, Ram Z, Riddle V, et al. Gliadel wafer in initial surgery for malignant glioma: long-term follow-up of a multicenter controlled trial. *Acta Neurochir (Wien)* 2006;148:269–275.
6. Cairncross G, MacDonald D, Ludwin S, et al. Chemotherapy for anaplastic oligodendroglioma. National Cancer Institute of Canada Clinical Trials Group. *J Clin Oncol* 1994;12:2013–2021.
7. Chamberlain MC, Glantz MJ, Chalmers L, et al. Early necrosis following concurrent Temozolomide and radiotherapy in patients with glioblastoma. *J Neurooncol* 2007;82:81–83.
8. Clarke JL, Chang S. Pseudoprogression and pseudoresponse: challenges in brain tumor imaging. *Curr Neurol Neurosci Rep* 2009;9:241–246.
9. Kirson ED, Dbaly V, Tovarys F, et al. Alternating electric fields arrest cell proliferation in animal tumor models and human brain tumors. *Proc Natl Acad Sci U S A* 2007;104:10152–10157.
10. Friedman HS, Prados MD, Wen PY, et al. Bevacizumab alone and in combination with irinotecan in recurrent glioblastoma. *J Clin Oncol* 2009;27:4733–4740.
11. Kreisl TN, Kim L, Moore K, et al. Phase II trial of single-agent bevacizumab followed by bevacizumab plus irinotecan at tumor progression in recurrent glioblastoma. *J Clin Oncol* 2009;27:740–745.
12. Vredenburgh JJ, Desjardins A, Herndon JE, et al. Bevacizumab plus irinotecan in recurrent glioblastoma multiforme. *J Clin Oncol* 2007;25:4722–4729.
13. Norden AD, Young GS, Setayesh K, et al. Bevacizumab for recurrent malignant gliomas: efficacy, toxicity, and patterns of recurrence. *Neurology* 2008;70:779–787.
14. Stupp R, Kanner A, Engelhard H, et al. A prospective, randomized, open-label, phase III clinical trial of NovoTTF-100A versus best standard of care chemotherapy in patients with recurrent glioblastoma. *J Clin Oncol* 2010;28(18S):LBA2007.
15. Park JK, Hodges T, Arko L, et al. Scale to predict survival after surgery for recurrent glioblastoma multiforme. *J Clin Oncol* 2010;28:3838–3843.
16. Combs SE, Thilmann C, Edler L, et al. Efficacy of fractionated stereotactic reirradiation in recurrent gliomas: long-term results in 172 patients treated in a single institution. *J Clin Oncol* 2005;23:8863–8869.
17. Combs SE, Wagner J, Bischof M, et al. Radiochemotherapy in patients with primary glioblastoma comparing two temozolomide dose regimens. *Int J Radiat Oncol Biol Phys* 2008;71:999–1005.
18. Pope WB, Lai A, Nghiemphu P, et al. MRI in patients with high-grade gliomas treated with bevacizumab and chemotherapy. *Neurology* 2006;66:1258–1260.
19. Wen PY, Macdonald DR, Reardon DA, et al. Updated response assessment criteria for

high-grade gliomas: response assessment in neuro-oncology working group. *J Clin Oncol* 2010;28:1963–1972.

20. Nghiemphu PL, Liu W, Lee Y, et al. Bevacizumab and chemotherapy for recurrent glioblastoma: a single-institution experience. *Neurology* 2009;72:1217–1222.
21. Wick W, Platten M, Weller M. New (alternative) temozolomide regimens for the treatment of glioma. *Neuro Oncol* 2009;11:69–79.
22. Spiro TP, Liu L, Majka S, et al. Temozolomide: the effect of once- and twice-a-day dosing on tumor tissue levels of the DNA repair protein O(6)-alkylguanine-DNA-alkyltransferase. *Clin Cancer Res* 2001;7:2309–2317.
23. Kurzen H, Schmitt S, Naher H, Mohler T. Inhibition of angiogenesis by non-toxic doses of temozolomide. *Anticancer Drugs* 2003;14:515–522.
24. Wick A, Pascher C, Wick W, et al. Rechallenge with temozolomide in patients with recurrent gliomas. *J Neurol* 2009;256:734–741.
25. Perry JR, Belanger K, Mason WP, et al. Phase II trial of continuous dose-intense temozolomide in recurrent malignant glioma: RESCUE study. *J Clin Oncol* 2010;28:2051–2057.
26. Wick W, Steinbach JP, Kuker WM, Dichgans J, Bamberg M, Weller M. One week on/one week off: a novel active regimen of temozolomide for recurrent glioblastoma. *Neurology* 2004;62:2113–2115.
27. Brandes AA, Tosoni A, Cavallo G, et al. Temozolomide 3 weeks on and 1 week off as first-line therapy for recurrent glioblastoma: phase II study from Gruppo Italiano Cooperativo di Neuro-oncologia (GICNO). *Br J Cancer* 2006;95:1155–1160.
28. Wick A, Felsberg J, Steinbach JP, et al. Efficacy and tolerability of temozolomide in an alternating weekly regimen in patients with recurrent glioma. *J Clin Oncol* 2007;25:3357–3361.
29. Newton HB, Page MA, Junck L, et al. Intra-arterial cisplatin for the treatment of malignant gliomas. *J Neurooncol* 1989;7:39–45.
30. Yung WK, Mechtler L, Gleason MJ. Intravenous carboplatin for recurrent malignant glioma: a phase II study. *J Clin Oncol* 1991;9:860–864.
31. Gwak HS, Youn SM, Kwon AH, Lee SH, Kim JH, Rhee CH. ACNU-cisplatin continuous infusion chemotherapy as salvage therapy for recurrent glioblastomas: phase II study. *J Neurooncol* 2005;75:173–180.
32. Batchelor T, Mulholland P, Neyns B, et al. The efficacy of cediranib as monotherapy and in combination with lomustine compared to lomustine alone in patients with recurrent glioblastoma: a phase III randomized study. *J Neurooncol* 2010;12(suppl 4):iv69–iv75.
33. Stewart LA. Chemotherapy in adult high-grade glioma: a systematic review and meta-analysis of individual patient data from 12 randomised trials. *Lancet* 2002;359:1011–1018.

34. Wick W, Hartmann C, Engel C, et al. NOA-04 randomized phase III trial of sequential radiochemotherapy of anaplastic glioma with procarbazine, lomustine, and vincristine or temozolomide. *J Clin Oncol* 2009;27:5874–5880.

35. Yung WK, Prados MD, Yaya-Tur R, et al. Multicenter phase II trial of temozolomide in patients with anaplastic astrocytoma or anaplastic oligoastrocytoma at first relapse. Temodal Brain Tumor Group. *J Clin Oncol* 1999;17:2762–2771.
36. Jenkins RB, Blair H, Ballman KV, et al. A t(1;19)(q10;p10) mediates the combined deletions of 1p and 19q and predicts a better prognosis of patients with oligodendroglioma. *Cancer Res* 2006;66:9852–9861.
37. Desjardins A, Reardon DA, Herndon JE, et al. Bevacizumab plus irinotecan in recurrent WHO grade 3 malignant gliomas. *Clin Cancer Res* 2008;14:7068–7073.
38. Parsons DW, Jones S, Zhang X, et al. An integrated genomic analysis of human glioblastoma multiforme. *Science* 2008;321:1807–1812.
39. Sanson M, Marie Y, Paris S, et al. Isocitrate dehydrogenase 1 codon 132 mutation is an important prognostic biomarker in gliomas. *J Clin Oncol* 2009;27:4150–4154.
40. Verhaak RG, Hoadley KA, Purdom E, et al. Integrated genomic analysis identifies clinically relevant subtypes of glioblastoma characterized by abnormalities in PDGFRA, IDH1, EGFR, and NF1. *Cancer Cell* 2010;17:98–110.
41. Minniti G, Muni R, Lanzetta G, Marchetti P, Enrici RM. Chemotherapy for glioblastoma: current treatment and future perspectives for cytotoxic and targeted agents. *Anticancer Res* 2009;29:5171–5184.
42. Van Meir EG, Hadjipanayis CG, Norden AD, Shu HK, Wen PY, Olson JJ. Exciting new advances in neuro-oncology: the avenue to a cure for malignant glioma. *CA Cancer J Clin* 2010;60:166–193.
43. Chang SM, Parney IF, Huang W, et al. Patterns of care for adults with newly diagnosed malignant glioma. *JAMA* 2005;293:557–564.
44. Pruitt AA. Treatment of medical complications in patients with brain tumors. *Curr Treat Options Neurol* 2005;7:323–336.
45. Drappatz J, Schiff D, Kesari S, Norden AD, Wen PY. Medical management of brain tumor patients. *Neurol Clin* 2007;25:1035–1071, ix.

ABOUT THE AUTHORS

Affiliations: Dr. Rosenfeld is Adjunct Professor of Neurology, University of Pennsylvania School of Medicine, Philadelphia, PA; Ms. Albright is a Certified Registered Nurse Practitioner at the University of Pennsylvania School of Medicine; and Dr. Pruitt is Associate Professor of Neurology at the University of Pennsylvania School of Medicine.

Conflicts of interest: The authors have nothing to disclose.