

# Pathological Changes After Autologous Formalin-Fixed Tumor Vaccine Therapy Combined With Temozolomide for Glioblastoma

## —Three Case Reports—

Noriaki SAKAMOTO,<sup>1</sup> Eiichi ISHIKAWA,<sup>1</sup> Tetsuya YAMAMOTO,<sup>1</sup> Kaishi SATOMI,<sup>2</sup> Kei NAKAI,<sup>1</sup> Masayuki SATO,<sup>1</sup> Takao ENOMOTO,<sup>3</sup> Yukio MORISHITA,<sup>2</sup> Shingo TAKANO,<sup>1</sup> Tadao OHNO,<sup>4</sup> Koji TSUBOI,<sup>5</sup> and Akira MATSUMURA<sup>1</sup>

<sup>1</sup>Department of Neurosurgery, and <sup>5</sup>Proton Medical Research Center, Graduate School of Comprehensive Human Sciences, University of Tsukuba, Tsukuba, Ibaraki;

<sup>2</sup>Department of Pathology, Institute of Basic Medical Sciences, University of Tsukuba, Tsukuba, Ibaraki;

<sup>3</sup>Department of Neurosurgery, Tsukuba Central Hospital, Ushiku, Ibaraki;

<sup>4</sup>Advanced Research Institute for Science and Engineering, Waseda University, Tokyo

### Abstract

**Temozolomide (TMZ), an alkylating agent widely used for patients with glioblastoma multiforme (GBM), has the potential to enhance the acquired immune response to GBM. Here, we describe 3 cases of GBM patients treated with autologous formalin-fixed tumor vaccine (AFTV) combined with TMZ. All cases demonstrated pathological changes associated with the therapy. After a 4-week break from the standard initial treatments, 1 patient with primary GBM and 2 patients with secondary GBM received adjuvant TMZ for 5 days combined with AFTV injection and were subsequently treated with multiple cycles of adjuvant TMZ for 5 days every 28 days (AFTV/TMZ therapy). Adverse effects related to AFTV plus TMZ were very minor in all patients. Magnetic resonance imaging revealed partial response in 2 patients. CD3<sup>+</sup>CD8<sup>+</sup> lymphocytes were frequently detected in surgical specimens and MIB-1 labeling index in 2 cases decreased after AFTV/TMZ therapy. AFTV/TMZ therapy is suitable for larger scale clinical trials.**

Key words: vaccine therapy, tumor-specific immunotherapy, chemotherapy, malignant glioma, temozolomide

### Introduction

The emergence of the new alkylating agent, temozolomide (TMZ), has changed the standard treatment of glioblastoma multiforme (GBM). Patients with newly diagnosed GBM are currently treated with maximal removal and standard focal radiotherapy (RT) plus concomitant daily TMZ administration followed by adjuvant TMZ (standard RT/TMZ) therapy.<sup>18,19</sup> However, the 2-year survival rate with the standard RT/TMZ therapy does not exceed 50%,<sup>19</sup> which has led to the development of various novel GBM therapies. In particular, there is growing interest in treatments that involve tumor-specific immune reactions, because of the potentially high benefit-to-risk ratio. These treatments may be useful in preventing tumor recurrence after initial localized treatments that involve surgery and RT. Our clinical study on adoptive cell therapy using autologous tumor-specific T lymphocytes (ATTL)<sup>21</sup> has re-

vealed that immunotherapy of recurrent malignant glioma yields favorable results. Moreover, we have previously reported autologous formalin-fixed tumor vaccine (AFTV)-based experimental and clinical immunotherapies.<sup>6,7</sup> These studies have suggested that autologous formalin-fixed tumor (AFT) tissues are useful sources of tumor-associated antigens and preparation of AFTV is easier than that of ATTL. Indeed, the latter pilot study mainly of recurrent GBM patients demonstrated the feasibility of such treatment, with 17% response rate and 42% disease control rate.<sup>7</sup> These results may be not inferior to those for other vaccines including peptide vaccine and peptide-pulsed dendritic cells (DC) vaccine, which have been used for the treatment of patients with GBM.<sup>24</sup>

RT can enhance immune response to tumors and so the combination of immunotherapy and RT is promising.<sup>2,5,13</sup> Recently, we closed a Phase IIa study of RT combined with AFTV (RT/AFTV) for the treatment of patients with initially diagnosed primary GBM (since September 2005,

UMIN C00000002).<sup>12)</sup> The efficacy of AFTV was verified since the median overall survival after initial surgery exceeded 21 months. Vaccination with DC followed by chemotherapy can significantly increase survival in patients with malignant glioma.<sup>11)</sup> In animals, TMZ shows potential ability to enhance antitumor immunity.<sup>9,10,14)</sup> However, only a few cases of GBM have been treated with vaccine-based immunotherapy combined with or after TMZ<sup>4,16,17)</sup> without detailed pathological findings at the pre- and post-vaccination stages.

We treated three patients with GBM using AFTV and adjuvant TMZ (AFTV/TMZ) therapy, and demonstrate the pathological changes associated with such chemoinmunotherapy.

## Patients and Methods

This study included patients with histologically verified primary or secondary GBM (World Health Organization grade IV) aged ranged from 16 to 75 years, who were candidates for TMZ administration, with AFT volume of more than 3 g and the Karnofsky performance status (KPS) of 40% and more. Patients with severe autoimmune diseases, with other active malignant tumors, and/or who participated in other clinical studies were excluded. Four patients among 8 candidates of the 20 GBM patients treated surgically from April 2008 to February 2009 agreed to participate and gave written informed consent for the AFTV/TMZ therapy. Three patients with preserved pathological specimens both before the therapy and after the tumor regrowth were included. One patient with no specimen after the tumor regrowth was excluded. Histological diagnoses were made by two pathologists at the Department of Pathology, University Hospital of Tsukuba. The AFTV therapy has been approved by the Ethical Committee of Tsukuba Central Hospital, where the AFTV was administered. The clinical characteristics of the patients are summarized in Table 1. Two patients had recurrent disease (Cases 2 and 3), and one patient had been initially treated but retained a visible tumor mass (Case 1). Case 2 presented with increased intracranial pressure (ICP) and was treated with low-dose oral steroid therapy at the time of AFTV treatment; hemiparesis was observed in 2 patients (Cases 2 and 3).

Case 1 was treated using the standard RT/TMZ protocol. Conformal RT with three-dimensional planning was administered for a total dose of 60 Gy at 2 Gy/fraction 5 days

a week for 6 weeks with a linear accelerator. Concomitant chemotherapy consisting of TMZ at a daily dose of 75 mg/m<sup>2</sup> administered 7 days a week from the first until the last day of RT was carried out. After a 4-week break, the patient received multiple cycles of adjuvant TMZ (150–200 mg/m<sup>2</sup>) for 5 days every 28 days, while no hematologic toxicity was observed. Patients with recurrent GBM (Cases 2 and 3) also received multiple cycles of the adjuvant TMZ therapy. Patients received three intradermal vaccinations with AFTV at one-week intervals. Each vaccination consisted of five intradermal injections of 0.2 ml (1 ml of vaccine in total) into the upper arm at five different sites; three vaccinations completed the AFTV treatment. The first injection was combined on the first day of the first (or second) cycle of the adjuvant TMZ therapy, in patients with initially diagnosed GBM and recurrent GBM.

The AFTV was prepared from AFT tissue and administered with adjuvant microparticles as described previously.<sup>7,15)</sup> The lesions used to prepare the vaccines were histologically viable GBM tissues with minimal necrotic lesions and no (or minimal) edematous gliosis lesions. All patients received adjuvant TMZ without additional treatment until tumor recurrence. When re-growth of the tumor was detected after the AFTV/TMZ therapy, the best treatment including second or third surgery was performed if informed consent was obtained from the patient. Histological examinations such as hematoxylin and eosin staining and immunohistochemical staining with MIB-1, CD3, CD8, CD4, and CD20 antibodies were assessed in all 3 cases before and after the AFTV/TMZ therapy.

## Results

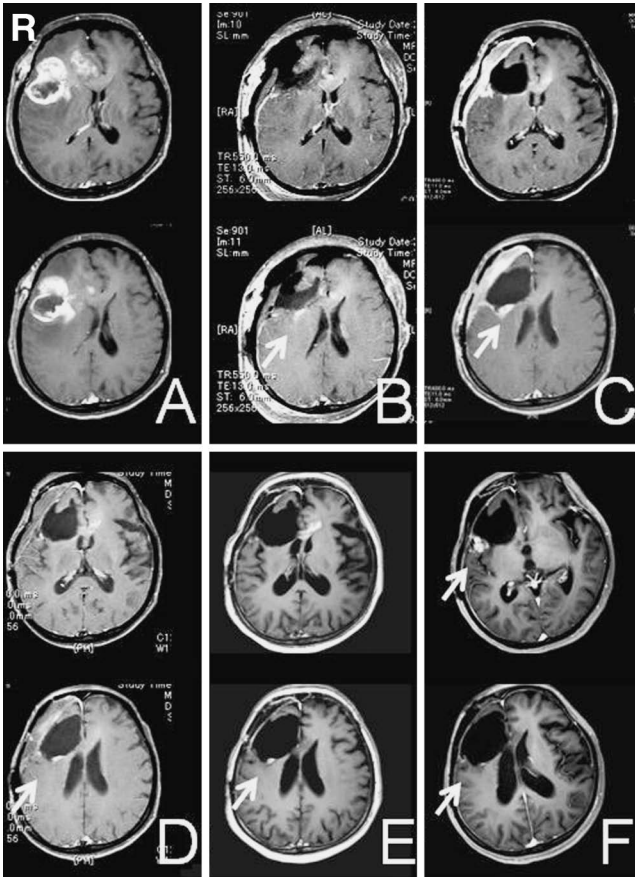
### I. Case presentations

**Case 1:** A 52-year-old woman presented with a ring-enhanced tumor in the right frontal lobe extending to the corpus callosum). The tumor was removed subtotally and histological examination revealed that the tumor was GBM (MIB-1 labeling index 60%). She received conventional RT (local irradiation, 60 Gy/30 fractions) with concomitant TMZ, followed by AFTV/TMZ therapy. Her general condition was good except for infrequent generalized convulsions, and serial magnetic resonance (MR) imaging demonstrated gradual decrease of the lesion (Fig. 1). Tumor recurrence was found after 6 cycles of adjuvant

**Table 1** Clinical characteristics of the patients

Case No.	Age (yrs)/ Sex	GBM type	Location of GBM	KPS at diagnosis (%)	Removal ratio (%)	Timing of AFTV therapy from surgery (wks)	KPS at AFTV therapy (%)
1	52/F	primary	rt frontal lobe	90	90	14	80
2	33/M	secondary	bil frontal lobes, corpus callosum	60	10	4	40
3	72/M	secondary	rt frontal lobe	60	99	5	50

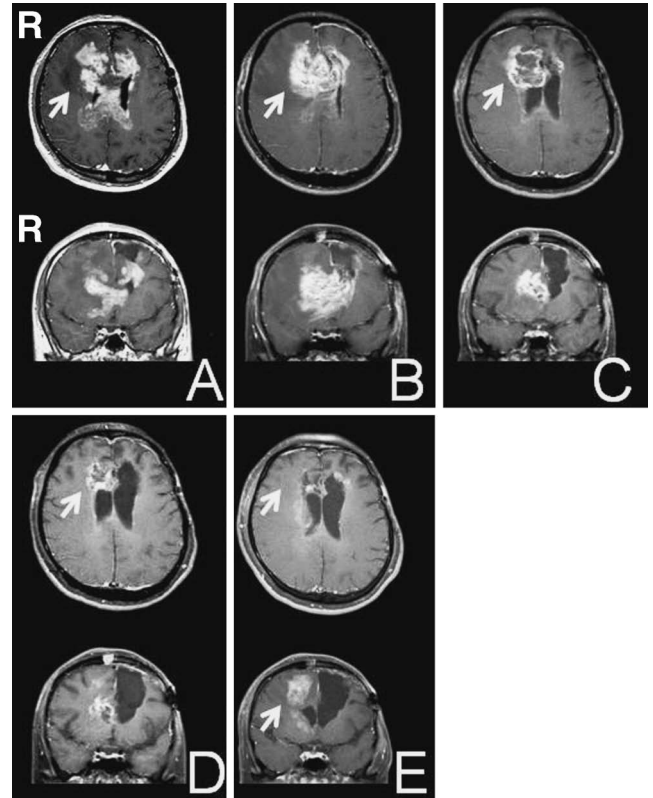
AFTV: autologous formalin-fixed tumor vaccine, F: female, GBM: glioblastoma multiforme, KPS: Karnofsky performance status, M: male.



**Fig. 1** Case 1. A 52-year-old woman with a right frontal primary glioblastoma multiforme (arrows). Serial T<sub>1</sub>-weighted magnetic resonance images with gadolinium demonstrating gradual decrease of the enhanced area with a resolution of mass effect (A: before the 1<sup>st</sup> operation, B: after the operation, C: after radiotherapy/temozolomide [TMZ] therapy, D: 7 weeks after autologous formalin-fixed tumor vaccine [AFTV]/TMZ therapy, E: 22 weeks after AFTV/TMZ therapy), and regrowth of the tumor (F: 31 weeks after AFTV/TMZ therapy).

TMZ and second surgery was performed for tumor decompression. The histological diagnosis of the resected tissue was GBM (MIB-1 labeling index 75%) with infiltration of lymphocytes.

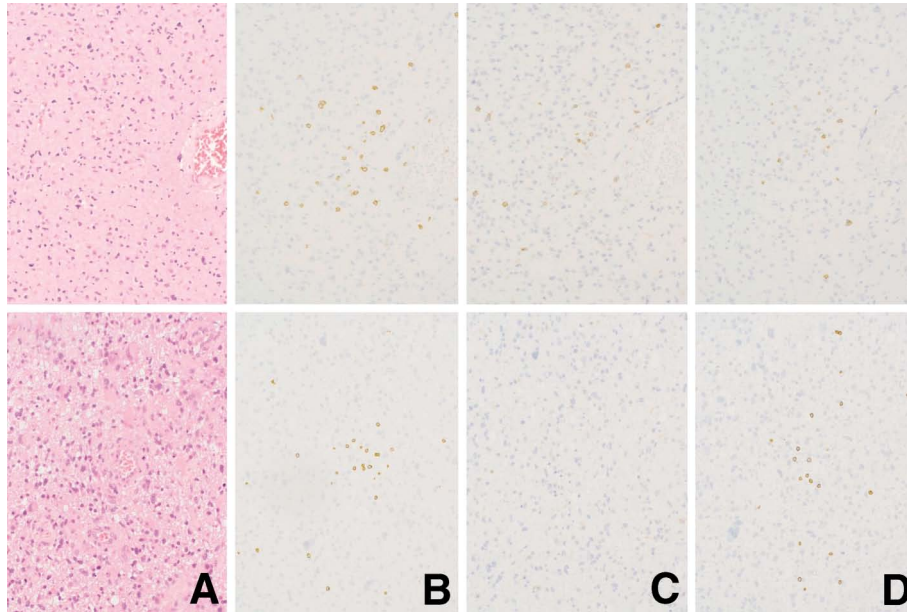
**Case 2:** A 27-year-old man presented with diffuse fibrillary astrocytoma (MIB-1 labeling index 5%) in the left frontal lobe. He received conventional RT (local irradiation, 60 Gy/30 fractions) because of the slightly high MIB-1 labeling index. Tumor recurrence was found in the bilateral frontal lobes and corpus callosum 5 years after the treatment. Second surgery was performed at the age of 33 years and the tumor in the left frontal lobe was partially removed (resection rate 10%) and submitted for AFTV preparation. The histological diagnosis of the tissue was GBM (MIB-1 labeling index 62.3%). The patient received the 1<sup>st</sup> cycle of adjuvant TMZ just after the second operation and the 2<sup>nd</sup> cycle of TMZ together with AFTV treatment. Before the AFTV/TMZ therapy, he could not walk (KPS 40%) and his consciousness was not clear due to se-



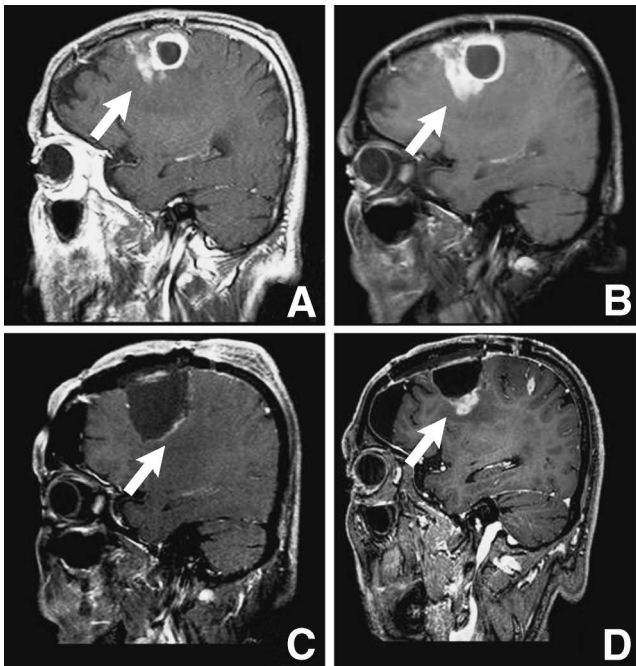
**Fig. 2** Case 2. A 33-year-old man with secondary glioblastoma multiforme lesions (arrows) in the bilateral frontal lobes and corpus callosum. Serial T<sub>1</sub>-weighted magnetic resonance images with gadolinium demonstrating dramatic decrease of the enhanced area (A: before the 2<sup>nd</sup> operation, B: after the 2<sup>nd</sup> operation, C: 5 weeks after autologous formalin-fixed tumor vaccine [AFTV]/ temozolomide [TMZ] therapy, D: 12 weeks after AFTV/TMZ therapy), and regrowth of the tumor (E: 20 weeks after AFTV/TMZ therapy).

vere increased ICP. MR imaging after the therapy demonstrated gradual decrease of the residual tumor volume (Fig. 2). He regained clear consciousness without increased ICP signs, and was able to walk using a cane (KPS 60%). Five months after the second surgery, tumor regrowth in the right frontal lobe was observed. He underwent 40 Gy/20 fractions of RT for the right frontal lesion, with continuing adjuvant TMZ. In addition, third surgery was performed to remove partially the growing tumor in the left frontal lobe. The surgical specimen was histologically identified as GBM recurrence (MIB-1 labeling index 30.6%) with infiltration of lymphocytes (Fig. 3).

**Case 3:** A 70-year-old man presented with anaplastic astrocytoma in the right frontal lobe. He received tumor removal and conventional RT (local irradiation, 60 Gy/30 fractions) but did not receive chemotherapy because of mild leukocytopenia. Local recurrence of the tumor was found in the right frontal lobe 1.5 years after the initial treatment. Second surgery was performed at the age of 72 years and the tumor was gross totally removed and submitted for AFTV preparation. The patient received the



**Fig. 3** Case 2. Photomicrographs showing the typical appearance of glioblastoma multiforme (A: hematoxylin and eosin stain,  $\times 400$ ), and CD3-, CD4-, and CD8-positive cells (B, C, and D, respectively: immunohistochemical stain,  $\times 400$ ) after the re-operation (upper row) and the 3<sup>rd</sup> operation after tumor re-growth (lower row).



**Fig. 4** Case 3. A 72-year-old man with a secondary glioblastoma multiforme (arrows) in the right frontal lobe. Serial T<sub>1</sub>-weighted magnetic resonance images with gadolinium demonstrating changes in the enhanced area (A: 6 weeks before re-operation, B: 2 weeks before the re-operation, C: just after the re-operation, D: 3 weeks after autologous formalin-fixed tumor vaccine/temozolomide therapy).

AFTV/TMZ therapy after the histological diagnosis of GBM (MIB-1 labeling index 31.4%) was established. He continued rehabilitation for his mild hemiparesis, and his clinical condition was improved for 3 months. MR imaging after the therapy demonstrated gradual increase in the residual tumor volume (Fig. 4). Concurrently, he complained of dyspnea due to the worsened chronic heart failure triggered by co-incident bacterial pneumonia. He died of respiratory and heart dysfunction 2 weeks later. His autopsy showed GBM cells were identified along the surgical defect (MIB-1 labeling index 16%) with infiltration of lymphocytes. The locations of the regrown tumors were compatible to those on the previous MR imaging, and tumor growth into brain stem or subarachnoid/intraventricular space was not detected. The specimen of the heart confirmed the presence of obsolete myocardial infarction and severe coronary arteriosclerosis, without auto-immune features. The histopathological cause of death was diagnosed as chronic heart failure.

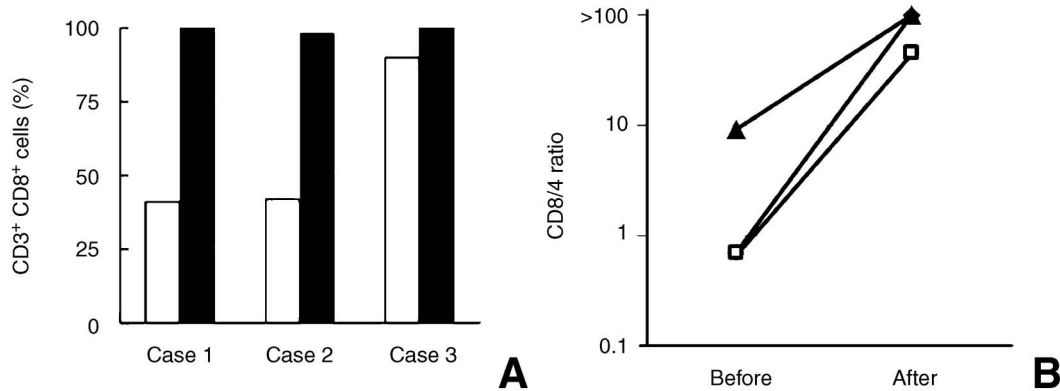
## II. Results of AFTV/TMZ therapy

The adverse effects related to RT/TMZ therapy were according to the Common Toxicity Criteria version 3.0 (CTC): grade 1 neutropenia, grade 3 lymphopenia, and grade 2 decreased white blood cell count in Case 1. The latter part of concomitant TMZ and subsequent adjuvant TMZ just after the 4-week break were not performed in Case 1, because of these adverse effects. The adverse effects related to AFTV/TMZ therapy consisted of CTC grade 1 skin trouble such as erythema, induration, and/or swelling of the inoculated sites in all cases, but were well tolerated by all patients. Low-grade fever, allergic dermatitis, and anaphylaxis were not noted in any patient after the

**Table 2 Clinical outcomes of the patients**

Case No.	Best response	Progression-free survival (wks)		Follow-up period (wks)	Last outcome
		From surgery	From AFTV therapy		
1	PR	45	31	66	died of GBM
2	PR	25	21	54	died of GBM
3	PD	8	3	20	died of heart failure

AFTV: autologous formalin-fixed tumor vaccine, GBM: glioblastoma multiforme, PD: progressive disease, PR: partial response.



**Fig. 5 A: Proportions of CD3<sup>+</sup>CD8<sup>+</sup> cells in tumor specimen before (open columns) and after (closed columns) autologous formalin-fixed tumor vaccine/temozolomide therapy. B: Changes in the CD8/4 ratios before and after the therapy. ◇: Case 1, □: Case 2, ▲: Case 3.**

AFTV vaccination. The adverse effects probably related to adjuvant TMZ but not AFTV consisted of transient elevation of aspartate aminotransferase (CTC grade 2) and transient elevation of alanine aminotransferase (CTC grade 3) in Case 2.

The clinical responses to the AFTV/TMZ therapy are summarized in Table 2. MR imaging revealed partial response over 5 months after AFTV administration in Case 1 (maximal percentage of tumor reduction by Response Evaluation Criteria In Solid Tumors [RECIST] was +68%) and in Case 2 (+54% by RECIST), and progressive disease in Case 3, as increase in the enhanced volume one month after the AFTV administration. Two patients (Cases 1 and 2) died of GBM over one year after the latest surgery. Case 3 died of chronic heart failure, independent of GBM or AFTV/TMZ therapy.

The histological findings before and after AFTV/TMZ therapy are summarized in Fig. 5. The MIB-1 labeling index in Cases 2 and 3 decreased after the AFTV/TMZ therapy (Case 1: 60% and 75%, Case 2: 62% and 31%, Case 3: 31% and 16% before and after therapy, respectively). CD3<sup>+</sup> T lymphocyte counts per 10 highly magnified ( $\times 400$ ) fields were almost stable before and after the therapy (mean counts, 68.7 and 64.0, respectively). CD3<sup>+</sup>CD8<sup>+</sup> T cells were detected with high frequency in the surgical specimens, especially after the AFTV/TMZ therapy, in all 3 cases (mean ratio in CD3<sup>+</sup> lymphocytes: 57.7% and 99.3% before and after therapy, respectively) (Fig. 5A). CD3<sup>+</sup>CD4<sup>+</sup> T cells decreased or were not detected after the therapy (mean ratio in CD3<sup>+</sup> lymphocytes: 42.3% and

0.7% before and after therapy, respectively). CD8/4 ratios increased in all 3 cases (Fig. 5B). CD20<sup>+</sup> cells mainly consisting of B cells were not detected before or after the therapy. Immunohistochemical staining for p53 and MGMT was positive in all cases before and after the therapy (mean frequency of p53-positive cells: 43.3% and 69.5%, mean frequency of MGMT-positive cells: 17.0% and 21.0%, respectively).

## Discussion

In the present 3 patients treated with the AFTV/TMZ therapy, objective responses were observed in Cases 1 and 2 (Table 2), in spite of positive immunohistochemical staining for MGMT in all 3 cases. Moreover, abundant CD3<sup>+</sup>CD8<sup>+</sup> T cells, which probably contain cytotoxic T lymphocytes, were detected in the surgical specimens and, to our surprise, these cells almost completely occupied the infiltrating T lymphocyte population after the AFTV/TMZ therapy (Fig. 5). The other infiltrating T lymphocyte population, CD3<sup>+</sup>CD4<sup>+</sup> cells, may have been depleted by TMZ treatment, as CD4<sup>+</sup> T cells in peripheral blood mononuclear cells are reduced in melanoma patients treated with TMZ.<sup>20</sup> However, with the limitations of the present study, we could not establish any definite conclusions about the immunological and pathological results because of the lack of objective controls such as histopathological studies before and after TMZ or AFTV therapy, and because of the limited number of patients.

In this study, whether the infiltrated CD8<sup>+</sup> T cells in the

tumor tissues obtained after the AFTV/TMZ therapy had actual specificity to the antigen used in the AFTV could not be confirmed. The CD8<sup>+</sup> T-dominant infiltration in tumor tissues after AFTV/TMZ therapy has not proved that this phenomenon is specific to this combined treatment, since AFTV, TMZ, or RT mono-therapy might yield a similar subset shift. Increased level of infiltration of CD4<sup>+</sup> and CD8<sup>+</sup> T cells was observed in brain tumors in mice treated with TMZ and DC vaccine compared with the level of infiltration achieved by mono-therapies.<sup>10)</sup> Only RT increased CD4<sup>+</sup> and CD8<sup>+</sup> T cell infiltration.<sup>13)</sup> These points should be resolved in further AFTV/TMZ studies, using immunohistochemical staining and cytotoxic T lymphocyte assay against already identified glioma-specific antigens. The immunohistochemical staining of MGMT showed positive staining in all 3 cases, suggesting relative resistance of the tumor cells to TMZ treatment. However, immunohistochemical staining remains controversial as the optimal MGMT assay. MGMT methylation-specific polymerase chain reaction assay should be explored to investigate the relationship between MGMT status of the tumor and the response to the AFTV/TMZ therapy in further studies.

Cases 1 and 2 finally died of GBM. Malignant gliomas have several mechanisms to escape human immune reactions including decreased expression of major histocompatibility complex class I (MHC-1) and cytokine production.<sup>23)</sup> Thus, adjuvant treatments to enhance the efficacy of AFTV are necessary to overcome such escape mechanisms. Recently, several researchers have proved that regulatory T cells (Treg) in the tumor tissue might be critical immune cells involved in the escape mechanism by producing immunosuppressive cytokines. Treg, which is also included in CD3<sup>+</sup>CD4<sup>+</sup> T cell population, inhibits the natural killer cell functions in a transforming growth factor- $\beta$ -dependent manner.<sup>3)</sup> Depletion of Treg promotes a tumor-specific immune response in pancreatic cancer-bearing mice.<sup>22)</sup> Several experimental studies have shown that TMZ has not only direct cytotoxicity against GBM but also the potential to deplete Treg<sup>1)</sup> and enhances acquired immunotherapies.<sup>9,10,14)</sup> In the present study, the results shown in Fig. 5 imply that TMZ-induced Treg depletion occurred after the AFTV/TMZ therapy. However, we could not confirm that Treg depletion did contribute to induce the objective responses in Cases 1 and 2.

Various adverse effects were observed in all 3 patients. The worst adverse effect was observed during the initial RT/TMZ treatment in the patient with primary GBM (Case 1), as has been observed in our case series in which 82% of malignant glioma patients suffered one or more adverse effects.<sup>8)</sup> Only minor adverse effects such as CTC grade 1 skin reaction were observed during the AFTV/TMZ therapy as well as during the adjuvant TMZ. AFTV-related impairment of vital organ functions was not found, supporting the feasibility of the combination of AFTV and TMZ. However, part of the TMZ protocol was not performed in Case 1, mainly because of TMZ-induced leukopenia and lymphopenia (detailed data not shown). The decrease of pathological CD3<sup>+</sup> T cell infiltration in Case 1 might have been related to this lymphopenia. The concomitant TMZ

protocol may require modification to maintain the immunity of the patients and the benefits of the AFTV/TMZ therapy.

Radiological responses were observed in 2 of 3 patients after AFTV/TMZ therapy without unexpected adverse effects. CD3<sup>+</sup>CD8<sup>+</sup> lymphocytes were frequently detected in the surgical specimens and MIB-1 labeling index in 2 cases decreased after the AFTV/TMZ therapy. AFTV/TMZ therapy appears to be suitable for larger scale clinical trials.

### Conflict of Interest Notification

TO is president and CEO of Cell-Medicine, Inc. (Tsukuba, Ibaraki). KT is also a board member of Cell-Medicine, Inc. Other authors have no conflict of interest.

### References

- 1) Banissi C, Ghiringhelli F, Chen L, Carpentier AF: Treg depletion with a low-dose metronomic temozolomide regimen in a rat glioma model. *Cancer Immunol Immunother* 58: 1627-1634, 2009
- 2) Ferrara TA, Hodge JW, Gulley JL: Combining radiation and immunotherapy for synergistic antitumor therapy. *Curr Opin Mol Ther* 11: 37-42, 2009
- 3) Ghiringhelli F, Ménard C, Terme M, Flament C, Taieb J, Chaput N, Puig PE, Novault S, Escudier B, Vivier E, Lecesne A, Robert C, Blay JY, Bernard J, Caillat-Zucman S, Freitas A, Tursz T, Wagner-Ballon O, Capron C, Vainchenker W, Martin F, Zitvogel L: CD4<sup>+</sup>CD25<sup>+</sup> regulatory T cells inhibit natural killer cell functions in a transforming growth factor-beta-dependent manner. *J Exp Med* 202: 1075-1085, 2005
- 4) Heimberger AB, Sun W, Hussain SF, Dey M, Crutcher L, Aldape K, Gilbert M, Hassenbusch SJ, Sawaya R, Schmittling B, Archer GE, Mitchell DA, Bigner DD, Sampson JH: Immunological responses in a patient with glioblastoma multiforme treated with sequential courses of temozolomide and immunotherapy: case study. *Neuro Oncol* 10: 98-103, 2008
- 5) Ishikawa E, Tsuboi K, Saijo K, Takano S, Ohno T: X-irradiation to human malignant glioma cells enhances the cytotoxicity of autologous killer lymphocytes under specific conditions. *Int J Radiat Oncol Biol Phys* 59: 1505-1512, 2004
- 6) Ishikawa E, Tsuboi K, Takano S, Uchimura E, Nose T, Ohno T: Intratumoral injection of IL-2-activated NK cells enhances the antitumor effect of an intradermally injected paraformaldehyde-fixed tumor vaccine in a rat intracranial brain tumor model. *Cancer Sci* 95: 98-103, 2004
- 7) Ishikawa E, Tsuboi K, Yamamoto T, Muroi A, Takano S, Enomoto T, Matsumura A, Ohno T: Clinical trial of autologous formalin-fixed tumor vaccine for glioblastoma multiforme patients. *Cancer Sci* 98: 1226-1233, 2007
- 8) Ishikawa E, Yamamoto T, Sakamoto N, Nakai K, Akutsu H, Tsuboi K, Takano S, Matsumura A: Low peripheral lymphocyte count before focal radiotherapy plus concomitant temozolomide predicts severe lymphopenia during malignant glioma treatment. *Neurol Med Chir (Tokyo)* 50: 638-644, 2010
- 9) Kim CH, Woo SJ, Park JS, Kim HS, Park MY, Park SD, Hong YK, Kim TG: Enhanced antitumor immunity by combined use of temozolomide and TAT-survivin pulsed dendritic cells in a murine glioma. *Immunology* 122: 615-622, 2007
- 10) Kim TG, Kim CH, Park JS, Park SD, Kim CK, Chung DS,

- Hong YK: Immunological factors relating to the antitumor effect of temozolomide chemoimmunotherapy in a murine glioma model. *Clin Vaccine Immunol* 17: 143–153, 2010
- 11) Liu G, Black KL, Yu JS: Sensitization of malignant glioma to chemotherapy through dendritic cell vaccination. *Expert Rev Vaccines* 5: 233–247, 2006
  - 12) Muragaki Y, Maruyama T, Iseki H, Tanaka M, Shinohara C, Takakura K, Tsuboi K, Yamamoto T, Matsumura A, Matsutani M, Karasawa K, Shimada K, Yamaguchi K, Nakazato Y, Sato K, Uemae Y, Ohno T, Okada Y, Hori T: Phase I/IIa trial of autologous formalin-fixed tumor vaccine concomitant with fractionated radiotherapy for newly diagnosed glioblastoma. *J Neurosurg* (in press)
  - 13) Newcomb EW, Demaria S, Lukyanov Y, Shao Y, Schnee T, Kawashima N, Lan L, Dewyngaert JK, Zagzag D, McBride WH, Formenti SC: The combination of ionizing radiation and peripheral vaccination produces long-term survival of mice bearing established invasive GL261 gliomas. *Clin Cancer Res* 12: 4730–4737, 2006
  - 14) Park SD, Kim CH, Kim CK, Park JA, Sohn HJ, Hong YK, Kim TG: Cross-priming by temozolomide enhances antitumor immunity of dendritic cell vaccination in murine brain tumor model. *Vaccine* 25: 3485–3491, 2007
  - 15) Peng BG, Liu SQ, Kuang M, He Q, Totsuka S, Huang L, Huang J, Lu MD, Liang LJ, Leong KW, Ohno T: Autologous fixed tumor vaccine: a formulation with cytokine-microparticles for protective immunity against recurrence of human hepatocellular carcinoma. *Jpn J Cancer Res* 93: 363–368, 2002
  - 16) Sampson JH, Aldape KD, Gilbert MR, Hassenbusch SJ, Sawaya R, Schmittling B, Archer GE, Mitchell D, Bigner DD, Reardon DA, Heimberger AB: Temozolomide as a vaccine adjuvant in GBM. *J Clin Oncol* 25(18S), 2007 ASCO Annual Meeting Proceedings Part I: abstract No. 2020, 2007
  - 17) Sampson JH, Archer GE, Mitchell DA, Heimberger AB, Herndon JE 2nd, Lally-Goss D, McGehee-Norman S, Paolino A, Reardon DA, Friedman AH, Friedman HS, Bigner DD: An epidermal growth factor receptor variant III-targeted vaccine is safe and immunogenic in patients with glioblastoma multiforme. *Mol Cancer Ther* 8: 2773–2779, 2009
  - 18) Stupp R, Hegi ME, Gilbert MR, Chakravarti A: Chemoradiotherapy in malignant glioma: standard of care and future directions. *J Clin Oncol* 25: 4127–4136, 2007
  - 19) Stupp R, Mason WP, van den Bent MJ, Weller M, Fisher B, Taphoorn MJ, Belanger K, Brandes AA, Marosi C, Bogdahn U, Curschmann J, Janzer RC, Ludwin SK, Gorlia T, Allgeier A, Lacombe D, Cairncross JG, Eisenhauer E, Mirimanoff RO; European Organisation for Research and Treatment of Cancer Brain Tumor and Radiotherapy Groups; National Cancer Institute of Canada Clinical Trials Group: Radiotherapy plus concomitant and adjuvant temozolomide for glioblastoma. *N Engl J Med* 352: 987–996, 2005
  - 20) Su YB, Sohn S, Krown SE, Livingston PO, Wolchok JD, Quinn C, Williams L, Foster T, Sepkowitz KA, Chapman PB: Selective CD4+ lymphopenia in melanoma patients treated with temozolomide: a toxicity with therapeutic implications. *J Clin Oncol* 22: 610–616, 2004
  - 21) Tsuboi K, Saijo K, Ishikawa E, Tsurushima H, Takano S, Morishita Y, Ohno T: Effects of local injection of ex vivo expanded autologous tumor-specific T lymphocytes in cases with recurrent malignant gliomas. *Clin Cancer Res* 9: 3294–3302, 2003
  - 22) Viehl CT, Moore TT, Liyanage UK, Frey DM, Ehlers JP, Eberlein TJ, Goedegebuure PS, Linehan DC: Depletion of CD4+CD25+ regulatory T cells promotes a tumor-specific immune response in pancreas cancer-bearing mice. *Ann Surg Oncol* 13: 1252–1258, 2006
  - 23) Weller M, Fontana A: The failure of current immunotherapy for malignant glioma. Tumor-derived TGF-beta, T-cell apoptosis, and the immune privilege of the brain. *Brain Res Brain Res Rev* 21: 128–151, 1995
  - 24) Yamanaka R: Cell- and peptide-based immunotherapeutic approaches for glioma. *Trends Mol Med* 14: 228–235, 2008

---

Address reprint requests to: Eiichi Ishikawa, MD, PhD, Department of Neurosurgery, Graduate School of Comprehensive Human Sciences, University of Tsukuba, 1-1-1 Tennodai, Tsukuba, Ibaraki 305-8575, Japan.  
e-mail: e-ishikawa@md.tsukuba.ac.jp