



Linear accelerator-based stereotactic radiosurgery in recurrent glioblastoma: a single center experience

Stereotaksična radiohirurgija uz pomoć linearnog akceleratora kod rekurentnog glioblastoma – iskustvo jednog centra

Sait Sirin*, Kaan Oysul[†], Serdar Surenkok[†], Omer Sager[†], Ferrat Dincoglan[†],
Bahar Dirican[†], Murat Beyzadeoglu[†]

Gulhane Military Medical Academy, *Department of Neurosurgery, [†]Department of Radiation Oncology, Ankara, Turkey

Abstract

Background/Aim. Management of patients with recurrent glioblastoma (GB) comprises a therapeutic challenge in neurooncology owing to the aggressive nature of the disease with poor local control despite a combined modality treatment. The majority of cases recur within the high-dose radiotherapy field limiting the use of conventional techniques for re-irradiation due to potential toxicity. Stereotactic radiosurgery (SRS) offers a viable non-invasive therapeutic option in palliative treatment of recurrent GB as a sophisticated modality with improved setup accuracy allowing the administration of high-dose, precise radiotherapy. The aim of the study was to, we report our experience with single-dose linear accelerator (LINAC) based SRS in the management of patients with recurrent GB. **Methods.** Between 1998 and 2010 a total of 19 patients with recurrent GB were treated using single-dose LINAC-based SRS. The median age was 47 (23–65) years at primary diagnosis. Karnofsky Performance Score was ≥ 70 for all the patients. The median planning target volume (PTV) was 13 (7–19) cc. The median marginal dose was 16 (10–19) Gy prescribed to the 80%–95% isodose line encompassing the planning target volume. The median follow-up time was 13 (2–59) months. **Results.** The median survival was 21 months and 9.3 months from the initial GB diagnosis and from SRS, respectively. The median progression-free survival from SRS was 5.7 months. All the patients tolerated radiosurgical treatment well without any Common Toxicity Criteria (CTC) grade > 2 acute side effects. **Conclusion.** Single-dose LINAC-based SRS is a safe and well-tolerated palliative therapeutic option in the management of patients with recurrent GB.

Key words:

glioblastoma; recurrence; palliative care; radiosurgery; particle accelerators.

Apstrakt

Uvod/Cilj. Lečenje bolesnika sa recidivantnim glioblastomom (GB) predstavlja terapijski izazov u neuroonkologiji zbog agresivne prirode bolesti i loše lokalne kontrole, uprkos kombinovanom lečenju. Najveći broj bolesnika dobije recidiv, iako prima visokodoznu radioterapiju u ograničenom predelu. Konvencionalne tehnike reiradijacije imaju ograničenu primenu zbog potencijalne toksičnosti. Stereotaksična radiohirurgija (SRH) predstavlja neinvazivnu terapijsku opciju u palijativnom lečenju rekurentnog GB kao sofisticirani modalitet sa unapređenom preciznošću podešavanja čime se omogućava primena visokodozne, precizne radioterapije. Cilj ove studije bio je da se prikažu sopstvena iskustva sa primenom jednodozne SRH uz korišćenje linearnog akceleratora (LINAC) u lečenju bolesnika sa rekurentnim GB. **Metode.** U periodu od 1998. do 2010. godine lečeno je 19 bolesnika sa rekurentnim GB korišćenjem linearnog akceleratora za jednodoznu SRH. Prosečna starost bolesnika pri postavljanju dijagnoze bila je 47 (23–65) godina. Karnofsky Performance Score bio je ≥ 70 kod svih bolesnika. Prosečni planirani ciljni volumen (*median planning target volume* – PTV) bio je 13 (7–19) cc. Prosečna marginalna doza iznosila je 16 (10–19) Gy i bila je određena za 80–95% izodozne linije, ispunjavajući tako planirani ciljni volumen. Prosečno vreme praćenja bilo je 13 (2–59) meseci. **Rezultati.** Prosečno preživljavanje bolesnika iznosilo je 21 mesec, tj. 9,3 meseca od uspostavljanja inicijalne dijagnoze GB i primene SRS. Prosečni interval od SRS do progresije bolesti iznosio je 5,7 meseci. Svi bolesnici dobro su podnosili radiohirurško lečenje bez pojave uobičajenih toksičnih efekata, nabrojanih u kriterijumima (*Common Toxicity Criteria* – CTC gradusa > 2) za akutne sporedne efekte. **Zaključak.** Jednodozna SRS pomoću linearnog akceleratora bezbedna je i dobro podnošljiva terapijska procedura u lečenju bolesnika sa rekurentnim GB.

Ključne reči:

glioblastom; recidiv; lečenje, palijativno; radiohirurgija; akceleratori čestica.

Introduction

Glioblastoma (GB) comprising the most common primary malignant brain tumor in adults, is as yet considered an incurable disease with a treatment-refractory, rapidly progressive course characterized by frequent recurrences despite a combined modality treatment. Recurrent glioblastoma is a more resistant form with a grim diagnosis in which treatment modalities are used with palliative intention. Today standard treatment of GB includes surgery followed by chemoradiation^{1,2}. Improved survival is achieved by adding radiotherapy with concurrent and adjuvant temozolomide following surgery^{1,3,4}, however, most patients eventually present with recurrence.

Many prognostic factors have been suggested for GB including age, tumor histopathology, extent of surgery and performance status. Recursive Partitioning Analysis (RPA) was applied to all of the prognostic factors to evaluate the associations between tumor characteristics, patient pre-treatment factors and treatment, versus survival⁵. Median survival by RPA classes III, IV, V and VI were 17.9, 11.1, 8.9, and 4.6 months, respectively⁵. This analysis conducted before the temozolomide era revealed that patients with GB represented a heterogeneous group with a median duration of survival ranging from 4.6 to 17.9 months⁵.

Therapeutic options at the time of recurrence include surgery, radiotherapy and/or chemotherapy^{6,7}, however these salvage treatment options used with palliative intention are usually hampered by initial primary treatment with surgery, full course radiotherapy and/or chemotherapy. Surgery may have a role in providing symptom's palliation and histopathological verification of recurrent disease, but infiltrative nature of GB usually precludes optimal surgery at recurrence owing to the risk of significant morbidity^{8,9}. Glioblastoma cells are chemoresistant and modest survival benefit has been achieved with systemic chemotherapy in the setting of recurrent disease¹⁰⁻¹². Re-irradiation is a therapeutic option for recurrent GB, however, the high dose delivered for initial primary disease releases concerns about radiation induced side effects in the recurrent disease setting due to the cumulative dose to normal brain structures with poor repair capacity, particularly when conventional involved field radiotherapy is considered¹³. Brachytherapy has been used in the treatment of recurrent malignant gliomas, but a high morbidity related with this invasive procedure limits its use^{14,15}. While delivering tumoricidal doses with conventional radiotherapy techniques is substantially limited by the potential adverse effects, focal re-irradiation in the form of stereotactic radiosurgery (SRS) and fractionated stereotactic radiotherapy (FSRT) exploiting the advantage of rigid immobilization and improved setup accuracy to deliver high dose of radiation precisely with a steep dose fall-off around the target are increasingly being used in the recurrent disease setting with promising results¹⁶⁻²³. In this study we reported our experience with single-dose LINAC-based SRS in the management of patients with recurrent GB.

Methods

Between 1998 and 2010 a total of 19 patients (13 males, 6 females) with recurrent GB were treated using single dose SRS. All the patients had a diagnosis of glioblastoma confirmed histopathologically. The patients were thoroughly evaluated by a multidisciplinary team consisting of the experts in radiation oncology, neurosurgery, medical oncology, and neuroradiology to decide on optimal management. Eligibility criteria for re-irradiation with SRS included the presence of a contrast-enhancing lesion on T1 weighted MRI of a suitable size and shape to allow accurate target definition. All the patients were required to have a Karnofsky Performance Score (KPS) of ≥ 70 and informed consent. The neurosurgical procedure for primary GB was gross-total resection in 5 patients, subtotal resection in 12 patients and biopsy in 2 patients. Local recurrence was diagnosed by neuroimaging, which showed regrowth of primary tumor; biopsy or resection was not required for confirmation. The median age at initial diagnosis of GB was 47 (23–65) years. Karnofsky Performance Score was ≥ 70 for all the patients, with a median KPS of 90. Recursive Partitioning Analysis (RPA) classification of the 19 patients was Class III in 2 patients, Class IV in 12 patients and Class V in 5 patients. All the patients received first line definitive radiotherapy with a median dose of 60 (54–62) Gy in daily fractions of 2 Gy. Eleven patients (57.9%) received chemotherapy consisting of temozolomide before recurrence. The median time between primary radiotherapy and SRS was 9 (5–49) months. The most common presenting symptoms in 15 out of 19 patients at recurrence included seizures, headache, nausea, vomiting, sensory and motor deficits.

For the first 10 years, SRS planning was done with XKnife-3 (Radionics, Boston, MA, USA) planning system and treatment was delivered with SL-25 LINAC (Elekta, UK). Radiosurgery planning system was then replaced with ERGO ++ (CMS, Elekta, US) allowing Volumetric Modulated Arc Radiosurgery and Synergy LINAC (Elekta, UK) with 3 mm thickness head-on micro-MLC (micro-multileaf collimator). On the day of treatment, a stereotactic frame (Leksell frame or 3D-Line frame, Elekta, UK) was affixed with the help of 4 pins to the patient's skull under local anesthesia, and a planning CT scan usually fused with a prior MRI was used for computerized treatment planning (Figure 1).

Coronal and sagittal images were used in addition to axial images to further improve target and organ-at-risk (OAR) delineation accuracy. Target volumes and critical structures were defined manually by both radiation oncologist and neurosurgeon. Gross tumor volume (GTV) was defined as contrast-enhancing lesion on T1 weighted MRI. In the generation of clinical target volume (CTV), GTV was expanded uniformly in each direction by 3 mm to cover potential microscopic tumor expansion. No additional margin was added to CTV to generate the planning target volume (PTV). Most often defined critical structures included the brainstem, optic chiasm and optic nerves, whereas dose constraints were < 10 Gy for all critical structures.

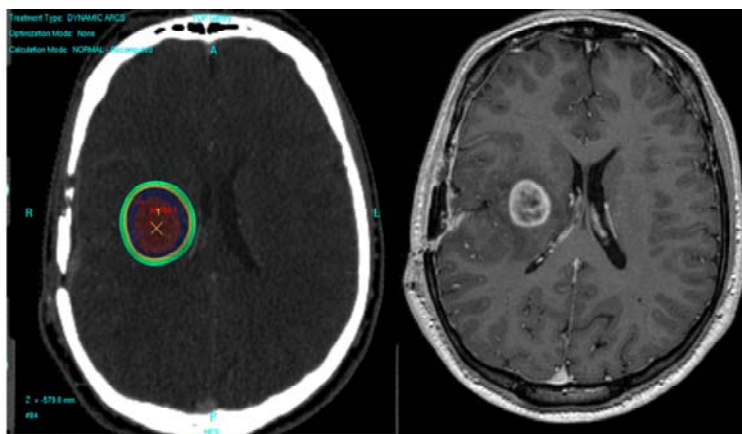


Fig. 1 – Treatment planning of a patient with recurrent glioblastoma in axial planning computerized tomography in ERGO planning system and T1 weighted magnetic resonance imaging used to improve target localization

A single 360° arc, double 360° arcs, or five 180° arcs were selected to spare the critical structures around the target location in the planning. Arc Modulation Optimization Algorithm (AMOA) was used to improve target coverage while sparing critical structures. Among different candidate treatment plans, the best plan was selected according to dose-volume histogram data analysis.

All the patients underwent single dose SRS using a LINAC with 6-MV photons. The median PTV was 13 (7–19) cc. The median marginal dose was 16 (10–19) Gy prescribed to the 80%–95% isodose line encompassing the PTV. Iso-centers of all the patients were checked by kV-CBCT (kilovoltage Cone Beam Computed Tomography) and setup verifications were done by XVI (X-ray Volumetric Imaging, Elekta, UK) system. Eight milligrams of intravenous dexamethasone with H2-antihistamines was used immediately after SRS.

After the completion of the treatment, follow-up visits were scheduled for every patient routinely at the first 2-month and then at 3-month intervals including clinical examination with neurological evaluation and neuroimaging with contrast-enhanced MRI. The patients were requested to inform the treating physician about any unexpected neurological worsening regardless of the follow-up schedule. Macdonald criteria were used to assess response to radiosurgical treatment²⁴. Complete response was defined as no clinically detectable cancer following treatment. Partial response was defined as ≥ 50% reduction in the size of enhancing tumor. Progressive disease was defined as ≥ 25% increase in the size of enhancing tumor or appearance of new lesions. If enhancing lesion did not meet the criteria for complete response, partial response, or progressive disease, then response was defined as stable disease. Local tumor control was calculated regarding complete or partial response and stable disease. If radiation necrosis was suspected, additional procedures such as MR-spectroscopy were scheduled. Acute toxicity was scored according to the Common Toxicity Criteria (CTC). The median follow-up time was 13 (2–59) months. Endpoints of the study were overall survival (OS) and progression-free survival (PFS). Overall survival was calculated from primary GB diagnosis and survival after SRS was calculated from the date of SRS. Progres-

sion-free survival was calculated from the date of SRS until progression of tumor or death.

Results

The characteristics of the patients are shown in Table 1.

The median overall survival was 21 (6.1–58.8) months from diagnosis of primary GB. The median progression-free survival was 5.7 (1–49.7) months and overall survival was 9.3 (1.1–49.7) months after SRS.

Table 1

Characteristics of the patients with recurrent glioblastoma

Patients characteristics (n = 19)	n	%
Gender		
male	13	68
female	6	32
Age at primary diagnosis of glioblastoma		
≤ 50 years	12	63
> 50 years	7	37
Histologic diagnosis		
WHO grade IV glioblastoma	19	100
Neurosurgical procedures		
gross-total resection	5	26
subtotal resection	12	63
biopsy	2	11
KPS		
90–100	9	47
80	8	42
70	2	11
RPA classification		
class III	2	11
class IV	12	63
class V	5	26

KPS – Karnofsky Performance Score; RPA – Recursive Partitioning Analysis

All the patients tolerated the treatment well with no acute toxicities (> CTC grade 2). Headache, nausea and vomiting were observed in 3 patients (15.8%), which resolved after 3 weeks of steroid therapy. Magnetic resonance imaging of these patients 2 months after SRS at first follow-up revealed stable disease. The first follow-up MRI at 2

months after SRS revealed partial response in 1 patient (5.3%), stable disease in 14 patients (73.7%) and progressive disease in 4 patients (21%). Local tumor control was achieved in 15 out of 19 patients (79%) and median duration of response was 7 months. Tumor progression was the cause of death in all the patients during follow-up.

Discussion

Glioblastoma, the most common primary brain tumor in adults, is characterized by rapid progression and has a grim prognosis with the median survival of 12–18 months despite multidisciplinary management with surgery, radiotherapy and chemotherapy at primary diagnosis²⁵. Management of GB is mainly palliative since providing cure for this devastating tumor is almost unachievable. Most patients eventually present with local recurrence and die as a result of locally recurrent disease within the original tumor site^{26–29}. Therapeutic options at the time of recurrence include surgery, systemic therapy, re-irradiation and investigational treatment modalities. Surgery for repeat debulking of recurrent tumor may be considered. Carmustine wafers have also been used after reoperation for recurrent gliomas with promising results³⁰. However, surgical treatment is usually hampered by the infiltrative nature of GB, which frequently precludes optimal re-resection^{8,9}. Modest survival benefit has been achieved with systemic chemotherapy in the setting of recurrent disease^{10–12}. Systemic therapy agents used in recurrent GB include temozolomide with various dosing regimens, antiangiogenic agents such as bevacizumab which may be used in combination with irinotecan, nitrosoureas either as single agents or in combination regimens; however, optimal combination of systemic agents has yet to be defined and currently considered experimental. Brachytherapy has been used in the treatment of recurrent malignant gliomas, but needs surgical intervention, which may cause severe morbidity^{14,15}.

Re-irradiation using conventional techniques at recurrence is usually limited by the high dose delivered for initial primary disease. Cumulative dose to normal brain structures with poor repair capacity should be thoroughly assessed to avoid excess neurotoxicity when considering re-irradiation. Among the radiotherapeutic options considered for re-irradiation of recurrent GB, radiosurgery appears to be the most appealing treatment modality. Its capability to precisely deliver tumoricidal doses of irradiation in a single fraction offering a non-invasive, well tolerated treatment with a steep dose fall-off around the target location minimizing normal tissue exposure to avoid toxicity without any systemic side effects is the reason for selecting SRS as a viable therapeutic option. Utilizing sophisticated stereotactic techniques offer non-invasive high dose treatments with submillimeter geometric accuracy through rigid immobilization and improved setup accuracy. Stereotactic radiosurgery may be considered as a viable therapeutic option in the management of recurrent GB with its inherent advantages over other radiotherapeutic approaches, however, selecting eligible patients to be treated with this highly sophisticated technology requires thorough assessment. Lesion size and shape should be suitable for SRS to

allow accurate target definition. Infiltrative nature of glioblastomas limit the use of focal treatments owing to potential microscopic extension of the disease beyond radiological borders thus making target definition difficult, so utmost care should be focused on patient selection for re-irradiation with SRS.

In our study, the patients were thoroughly evaluated by a multidisciplinary team before deciding on optimal management. All the patients in our study tolerated the treatment well with no acute toxicities (> CTC grade 2). We used a 3 mm uniform margin around the contrast-enhancing lesion on T1 weighted MRI to cover potential microscopic expansion of the recurrent tumor. Maranzano et al.¹⁸ also used a 3 mm margin in their study. In the RTOG 0023 study by Cardinale et al.³¹, PTV for stereotactic radiotherapy included the GTV plus a 5 mm margin in all directions. In the study by Fogh et al.²² and Souhami et al.³², no margin was used in target definition. There is still no consensus on the use of margins for target definition in SRS of glioblastomas.

Most recurrences occur locally in patients with GB regardless of the initial management strategy^{26–29}. Failure to control the tumor at its original site has prompted the utilization of SRS in an attempt to achieve dose escalation in primary radiotherapy of GB, however, no improvement in overall survival was achieved³². In the recurrent setting, retrospective data with matched pair analyses suggest the benefit of salvage therapy although results are subject to selection bias favoring patients undergoing salvage³³. Stereotactic radiosurgery has been used to palliate GB recurrences with promising results^{16–23, 34–36}. In the case control study by Mahajan et al.¹⁶, the median survival was 11 months in the case group and 10 months in the control group from the date of SRS. In the study by Shrieve et al.¹⁷, the median actuarial survival was 10.2 months for patients treated with SRS from the time of treatment for recurrence. In a recent study by Maranzano et al.¹⁸, the median overall survival from the first surgery to death was 26 months, median overall survival after re-irradiation was 11 months, the median progression-free survival was 4 months while local control was obtained in 71% of patients. In the study by Hsieh et al.¹⁹, treatment with adjuvant gamma knife-SRS conferred a median overall survival of 14.3 months for the patient cohort. Adjuvant gamma knife-SRS performed at tumor progression yielded an improved median survival of 16.7 months compared with the median survival of 10 months when SRS was performed upfront after initial tumor resection¹⁹. In the study by Combs et al.²⁰, the median overall survival was 21 months and 8 months after primary diagnosis and after re-irradiation, respectively for patients treated with fractionated stereotactic re-irradiation for GB. In the study by Kong et al.²¹, the median overall survival was 23 months and median progression-free survival after SRS was 4.6 months for patients with GB. Compared with the historical control group, SRS was found to prolong survival significantly as a salvage treatment in patients with recurrent glioblastoma (23 months vs 12 months; $p < 0.0001$)²¹. In the study by Fogh et al.²², the median survival time (MST) from the date of diagnosis and from the time of hypofractionated stereotactic radiation therapy (H-SRT) was 23 months and 11 months, respectively for patients

with GB. Follow-up MRI scans after H-SRT revealed stable disease in 60% of the patients, minimal response in 10% of the patients, and progression in 30% of the patients²². In the study by Patel et al.²³, MST after SRS was 8.5 months. Radiographic tumor response or stable disease was observed in 35% of patients and tumor progression was seen in 65% of patients treated with SRS²³. In the study by Cho et al.³⁴ comparing single dose vs fractionated stereotactic radiotherapy for recurrent high grade gliomas, actuarial MST was 11 months for the SRS group and 12 months for the FSRT group, without a statistical significance. In the study by Hall et al.³⁵ evaluating the role of SRS in the management of recurrent malignant gliomas, the actuarial survival time for all patients was 21 months from diagnosis and 8 months from radiosurgery. In the study by Combs et al.³⁶, the median overall survival was 22 months and 10 months from primary diagnosis and after SRS, respectively for patients with recurrent GB.

In our study, the median overall survival was 21 months from diagnosis of primary GB. The median progression-free survival was 5.7 months and overall survival was 9.3 months after SRS. The first follow-up MRI at 2 months after SRS revealed a partial response in 1 patient (5.3%), stable disease in 14 patients (73.7%) and progressive disease in 4 patients (21%); thus local tumor control was achieved in 15 out of 19 patients (79%). Tumor progression was the cause of death for all the patients during the follow-up in our study.

Conclusion

LINAC-based, single-dose SRS, is a safe and well-tolerated palliative therapeutic option in the management of patients with recurrent GB. Further studies are warranted to refine the optimal management of this challenging, as yet incurable disease.

R E F E R E N C E S

1. *Stupp R, Mason WP, Bent MJ Van den, Weller M, Fischer B, Taphoorn MJ, et al.* Radiotherapy plus concomitant and adjuvant temozolomide for glioblastoma. *N Engl J Med.* 2005; 352(10): 987–96.
2. *Stupp R, Hegi ME, Mason WP, Bent MJ Van den, Taphoorn MJ, Janzer RC, et al.* Effects of radiotherapy with concomitant and adjuvant temozolomide versus radiotherapy alone on survival in glioblastoma in a randomised phase III study: 5-year analysis of the EORTC-NCIC trial. *Lancet Oncol* 2009;10(5):459–66.
3. *Gorlia T, Bent MJ van den, Hegi ME, Mirimanoff RO, Weller M, Cairncross JG, et al.* Nomograms for predicting survival of patients with newly diagnosed glioblastoma: prognostic factor analysis of EORTC and NCIC trial 26981-22981/CE.3. *Lancet Oncol* 2008; 9(1):29–38.
4. *Mirimanoff RO, Gorlia T, Mason W, Bent MJ Van den, Kortmann RD, Fisher B, et al.* Radiotherapy and temozolomide for newly diagnosed glioblastoma: recursive partitioning analysis of the EORTC 26981/22981-NCIC CE3 phase III randomized trial. *J Clin Oncol* 2006; 24(16): 2563–9.
5. *Curran WJ Jr, Scott CB, Horton J, Nelson JS, Weinstein AS, Fischbach AJ, et al.* Recursive partitioning analysis of prognostic factors in three Radiation Therapy Oncology Group malignant glioma trials. *J Natl Cancer Inst* 1993; 85(9): 704–10.
6. *Nieder C, Grosu AL, Molls M.* A comparison of treatment results for recurrent malignant gliomas. *Cancer Treat Rev* 2000; 26(6): 397–409.
7. *Nieder C, Wiedenmann N, Andrasschke N, Molls M.* Current status of angiogenesis inhibitors combined with radiation therapy. *Cancer Treat Rev* 2006; 32(5): 348–64.
8. *Harsb GR, Levin VA, Gutin PH, Seager M, Silver P, Wilson CB.* Reoperation for recurrent glioblastoma and anaplastic astrocytoma. *Neurosurgery* 1987; 21(5): 615–21.
9. *Dirks P, Bernstein M, Muller PJ, Tucker WS.* The value of reoperation for recurrent glioblastoma. *Can J Surg* 1993; 36(3): 271–5.
10. *Chua SL, Rosenthal MA, Wong SS, Ashley DM, Woods AM, Dowling A, et al.* Phase 2 study of temozolomide and Caelyx in patients with recurrent glioblastoma multiforme. *Neuro Oncol* 2004; 6(1): 38–43.
11. *Chamberlain MC, Tsao-Wei DD.* Salvage chemotherapy with cyclophosphamide for recurrent, temozolomide-refractory glioblastoma multiforme. *Cancer* 2004; 100(6): 1213–20.
12. *Brandes AA, Pasetto LM, Monfardini S.* New drugs in recurrent high grade gliomas. *Anticancer Res* 2000; 20(3B): 1913–20.
13. *Mayer R, Sminia P.* Reirradiation tolerance of the human brain. *Int J Radiat Oncol Biol Phys* 2008; 70(5): 1350–60.
14. *Chamberlain MC, Barba D, Kormanik P, Berson AM, Saunders WM, Shea MC.* Concurrent cisplatin therapy and iodine 125 brachytherapy for recurrent malignant brain tumors. *Arch Neurol* 1995; 52(2): 162–7.
15. *Scharfen CO, Sneed PK, Wara WM, Larson DA, Phillips TL, Prados MD, et al.* High activity iodine-125 interstitial implant for gliomas. *Int J Radiat Oncol Biol Phys* 1992; 24(4): 583–91.
16. *Mabajan A, McCutcheon IE, Suki D, Chang EL, Hassenbusch SJ, Weinberg JS, et al.* Case-control study of stereotactic radiosurgery for recurrent glioblastoma multiforme. *J Neurosurg* 2005; 103(2): 210–7.
17. *Shrieve DC, Alexander E III, Wen PY, Fine HA, Kooy HM, Black PM, et al.* Comparison of stereotactic radiosurgery and brachytherapy in the treatment of recurrent glioblastoma multiforme. *Neurosurgery* 1995; 36(2): 275–84.
18. *Maranzano E, Anselmo P, Casale M, Trippa F, Carletti S, Principi M, et al.* Treatment of recurrent glioblastoma with stereotactic radiotherapy: long-term results of a mono-institutional trial. *Tumori* 2011; 97(1): 56–61.
19. *Hsieh PC, Chandler JP, Bhangoo S, Panagiotopoulos K, Kalapurakal JA, Marymont MH, et al.* Adjuvant gamma knife stereotactic radiosurgery at the time of tumor progression potentially improves survival for patients with glioblastoma multiforme. *Neurosurgery* 2005; 57(4): 684–92.
20. *Combs SE, Thilmann C, Edler L, Debus J, Schulz-Ertner D.* Efficacy of fractionated stereotactic reirradiation in recurrent gliomas: long-term results in 172 patients treated in a single institution. *J Clin Oncol* 2005; 23(34): 8863–9.
21. *Kong DS, Lee JL, Park K, Kim JH, Lim DH, Nam DH.* Efficacy of stereotactic radiosurgery as a salvage treatment for recurrent malignant gliomas. *Cancer* 2008; 112(9): 2046–51.
22. *Fogh SE, Andrews DW, Glass J, Curran W, Glass C, Champ C, et al.* Hypofractionated stereotactic radiation therapy: an effective therapy for recurrent high-grade gliomas. *J Clin Oncol* 2010; 28(18): 3048–53.
23. *Patel M, Siddiqui F, Jin JY, Mikkelsen T, Rosenblum M, Movsas B, et al.* Salvage reirradiation for recurrent glioblastoma with radiosurgery: radiographic response and improved survival. *J Neurooncol* 2009; 92(2): 185–9.

24. Macdonald DR, Cascino TL, Schold SC Jr, Cairncross JG. Response criteria for phase II studies of supratentorial malignant glioma. *J Clin Oncol* 1990; 8(7): 1277–80.
25. Hou LC, Veeravagu A, Hsu AR, Tse VC. Recurrent glioblastoma multiforme: a review of natural history and management options. *Neurosurg Focus* 2006; 20(4): E5.
26. Wallner KE, Galicich JH, Krol G, Arbit E, Malkin MG. Patterns of failure following treatment for glioblastoma multiforme and anaplastic astrocytoma. *Int J Radiat Oncol Biol Phys* 1989; 16(6): 1405–9.
27. Sneed PK, Gutin PH, Larson DA, Malec MK, Phillips TL, Prados MD, et al. Patterns of recurrence of glioblastoma multiforme after external irradiation followed by implant boost. *Int J Radiat Oncol Biol Phys* 1994; 29(4): 719–27.
28. Leibel SA, Scott CB, Loeffler JS. Contemporary approaches to the treatment of malignant gliomas with radiation therapy. *Semin Oncol* 1994; 21(2): 198–219.
29. Combs SE, Gutwein S, Thilmann Cb, Huber P, Debus J, Schulz-Ertner D. Stereotactically guided fractionated re-irradiation in recurrent glioblastoma multiforme. *J Neurooncol* 2005; 74(2): 167–171.
30. Brem H, Piantadosi S, Burger PC, Walker M, Selker R, Vick NA, et al. Placebo-controlled trial of safety and efficacy of intraoperative controlled delivery by biodegradable polymers of chemotherapy for recurrent gliomas. The Polymer-brain Tumor Treatment Group. *Lancet* 1995; 345(8956): 1008–12.
31. Cardinale R, Won M, Choucair A, Gillin M, Chakeravarti A, Schultz C, et al. A phase II trial of accelerated radiotherapy using weekly stereotactic conformal boost for supratentorial glioblastoma multiforme: RTOG 0023. *Int J Radiat Oncol Biol Phys* 2006; 65(5): 1422–8.
32. Souhami L, Sejerbeld W, Brachman D, Podgorsak EB, Werner-Wasik M, Lustig R, et al. Randomized comparison of stereotactic radiosurgery followed by conventional radiotherapy with carmustine to conventional radiotherapy with carmustine for patients with glioblastoma multiforme: report of Radiation Therapy Oncology Group 93-05 protocol. *Int J Radiat Oncol Biol Phys* 2004; 60(3): 853–60.
33. Hau P, Baumgart U, Pfeijfer K, Bock A, Jauch T, Dietrich J, et al. Salvage therapy in patients with glioblastoma: is there any benefit? *Cancer* 2003;98(12): 2678–86.
34. Cho KH, Hall WA, Gerbi BJ, Higgins PD, McGuire WA, Clark HB. Single dose versus fractionated stereotactic radiotherapy for recurrent high-grade gliomas. *Int J Radiat Oncol Biol Phys* 1999; 45(5): 1133–41.
35. Hall WA, Djalilian HR, Sperduto PW, Cho KH, Gerbi BJ, Gibbons JP, et al. Stereotactic radiosurgery for recurrent malignant gliomas. *J Clin Oncol* 1995; 13(7): 1642–8.
36. Combs SE, Widmer V, Thilmann C, Hof H, Debus J, Schulz-Ertner D. Stereotactic radiosurgery (SRS): treatment option for recurrent glioblastoma multiforme (GBM). *Cancer* 2005; 104(10): 2168–73.

Received on March 23, 2011.

Revised on August 25, 2011.

Accepted on September 5, 2011.