



Original Research Article

The role of large volume re-irradiation with Bevacizumab in chemorefractory high grade glioma



Joseph Chan^{a,*}, Dasantha Jayamanne^{a,d}, Helen Wheeler^{a,d,e}, Mustafa Khasraw^{a,d,e}, Matthew Wong^b, Marina Kastelan^{a,e}, Lesley Guo^a, Michael Back^{a,b,c,d,e}

^a Northern Sydney Cancer Centre, Royal North Shore Hospital, Sydney, Australia

^b Central Coast Cancer Centre, Gosford Hospital, Gosford, Australia

^c Genesis Cancer Care, Sydney, Australia

^d Sydney Medical School, University of Sydney, Sydney, Australia

^e The Brain Cancer Group, Sydney, Australia

ARTICLE INFO

Article history:

Received 18 December 2019

Revised 6 March 2020

Accepted 6 March 2020

Available online 9 March 2020

Keywords:

Recurrent glioma

Glioblastoma

Re-irradiation

CNS

Bevacizumab

ABSTRACT

Background and purpose: Current practice in re-irradiation (reRT) of previously treated high-grade gliomas (HGG) has generally been limited to small volume reRT with stereotactic procedures. Less evidence exists for large volume reRT involving treatment volumes equivalent to that used at initial diagnosis. The primary aim of this study was to investigate the outcome of large volume reRT delivered in combination with Bevacizumab (BEV) in patients with recurrent chemorefractory HGG.

Methods and materials: Patients with HGG managed with reRT were entered prospectively into a database. Clinicopathological features were recorded including timing of reRT, use of BEV and Dosimetric data. Median survival following reRT was the primary endpoint and association with clinicopathological factors was assessed with cox regression models.

Results: Sixty seven patients in total were managed with reRT, 51 patients had glioblastoma and 16 had anaplastic glioma. The median PTV was 145.3 cm³. Median OS post reRT was 7.8 months (95% CI 6.3–9.2 months) in the total cohort and 7.5 months (95% CI: 6.6–8.3 months) for GBM patients. In multivariate analysis of the whole cohort, IDH1 mutation status ($p = 0.041$) and ECOG status prior to reRT (<0.001) were significantly associated with OS. In terms of safety and toxicity, the majority of patients (66.5%) were ECOG 0–2 three months after treatment. In total, four episodes of suspected radiation necrosis occurred, all in patients treated without upfront BEV.

Conclusion: Large volume reRT with bevacizumab is a feasible late salvage option in patients with recurrent HGG and offers meaningful prolongation of survival with low toxicity.

© 2020 Published by Elsevier B.V. on behalf of European Society for Radiotherapy and Oncology. This is an open access article under the CC BY-NC-ND license (<http://creativecommons.org/licenses/by-nc-nd/4.0/>).

1. Introduction

The treatment of primary high-grade gliomas at recurrence depends on numerous factors including histology, age and patient fitness. Patients at relapse are typically managed with combinations of repeat resection, second and third line chemotherapy, or bevacizumab (BEV). However re-irradiation (reRT) remains an uncommon treatment in patients with recurrent high-grade gliomas over concerns regarding efficacy and potential toxicity.

Abbreviations: BEV, bevacizumab; ECOG, Eastern cooperative oncology group; OS, overall survival; reRT, reirradiation.

* Corresponding author at: Northern Sydney Cancer Centre, Royal North Shore Hospital, St Leonards, Sydney, NSW 2065, Australia.

E-mail address: joseph.chan@health.nsw.gov.au (J. Chan).

Historically, reRT of recurrent high-grade gliomas have been performed only in select cases and primarily on patients with volumes of disease of less than 40 cm³ [1]. The main barrier in treating larger volume disease in the setting of recurrent high-grade gliomas has been the perceived risk of CNS radionecrosis. This risk, which increases with escalating dose and treatment volumes, has been somewhat minimised in recent years by the understanding of bevacizumab as an effective treatment in cases of CNS radionecrosis. Several studies including a study of 118 patients by Palmer et al. (2018) have demonstrated both the safety and efficacy of combining reRT with BEV [2,3]. These studies have shown reasonable survival outcomes. However, these prior studies of reRT with BEV have primarily focused on treatment of patients with

<https://doi.org/10.1016/j.ctro.2020.03.005>

2405-6308/© 2020 Published by Elsevier B.V. on behalf of European Society for Radiotherapy and Oncology.

This is an open access article under the CC BY-NC-ND license (<http://creativecommons.org/licenses/by-nc-nd/4.0/>).

small volumes [3]. The body of evidence in the literature looking at large volume reRT remains small.

The aims of the current study was to investigate the feasibility, outcome and tolerability of large-volume reRT in patients with recurrent high-grade glioma.

2. Materials and methods

Adult patients diagnosed with recurrent high-grade glioma and referred to the Neuro-oncology Multidisciplinary Tumour Board were entered into a prospective database, approved by Institutional Ethics Review Board. Consecutive patients managed with reRT using intensity modulated radiation therapy (IMRT) between January 2010 and December 2017 were eligible for this analysis.

2.1. Patient selection

Eligible patients included those with a prior diagnosis of high grade glioma (glioblastoma, anaplastic glioma or other anaplastic glial pathology) and an initial management that involved definitive or adjuvant high dose radiation therapy. At time of entry into the database patients required conclusive radiological or histopathological evidence of recurrent and chemorefractory intracranial progression. This would be with either sequential MRI or PET imaging that excluded the potential for initial post treatment effects such as pseudoprogression or radiation necrosis. Chemorefractory disease was defined as either progression on at least one salvage systemic cytotoxic chemotherapy or inability to receive salvage systemic chemotherapy because of contraindications. Patients could be included for reRT before the onset of bevacizumab refractory disease.

2.2. Definition of re-irradiation

Eligible patients for reRT required a history of previous high dose radiation therapy, defined as a dose of at least 40 Gy in 15 fractions (as used in elderly patients with GBM), up to a dose of 60 Gy in 30 fractions; and then a subsequent course of radiation therapy overlapping the same region to at least a dose of 30 Gy in 2 Gy equivalent fractions. All dosimetric parameters of the reRT were recorded.

2.3. Re-irradiation protocol

All patients were managed with fractionated radiation therapy using an IMRT or VMAT technique. Target volume delineation (GTV) was determined using sequential MRI scans with GTV encompassing any gadolinium enhancing mass on T1 sequence and any suspicious non-enhancing region on T2 FLAIR sequences. DWI sequences were utilised in patients who were receiving BEV to provide improved delineation of infiltrative disease when gadolinium enhancement was reduced post BEV. FET PET was used to clarify uncertainties regarding extent of disease, especially in presence of widespread T2 Flair. The GTV was subsequently expanded by 5 mm to CTV and a further 3 mm to PTV.

The prescription dose is detailed in Table 1. Generally 35–40 Gy in 15 fractions over three weeks was delivered to the PTV, with the higher dose selected in latter patients after initial review noted the absence of treatment related morbidity. In patients with extensive infiltrative non-enhancing disease on T2 Flair an integrated boost technique was used with the contrast enhancing areas treated to 40 Gy whilst T2 Flair was limited to 35 Gy.

Normal tissue tolerances were based on the estimated sum plan and included the optic chiasm and brainstem being limited to 75 Gy and 85 Gy respectively. No limitation was placed on normal

Table 1
Baseline characteristics of patients included in the current study.

Characteristics	n = 67	%
Gender		
Male	43	64.2
Female	24	35.8
Age		
Age range	26–83	
Median age	54	
Time from diagnosis to re RT (months)		
Range	4–263	
Median	21	
Initial histopathology		
GBM	51	76.1
Anaplastic glioma	16	23.9
Disease Location		
Frontal	20	29.9
Temporal	17	25.4
Parietal	21	31.3
Occipital	8	11.9
Other	1	1.5
IDH1 status		
Mutated	17	25.4
Non-mutated	50	74.6
Initial RT dose		
60 Gy/30#	50	74.6
59.4 Gy/33#	4	6.0
54 Gy/30#	8	11.9
40 Gy/15#	5	7.5
ReRT dose*		
35 Gy/15#	35	53.0
40 Gy/15#	15	22.7
35 Gy/10#	6	9.1
55 Gy/25#	6	9.1
25 Gy/5# or 30 Gy/5#	4	6.1
ReRT PTV (Cm3)		
Range	10.6–432.8	
Median	145.3	
Bevacizumab at reRT		
Yes	52	77.6
No	15	22.4
Bevacizumab post reRT		
Yes	61	91.0
No	6	9.0
ECOG status pre-reRT		
0	1	1.5
1	29	43.3
2	27	40.3
3	10	14.9
4	0	0
ECOG status 3 months post-reRT ^		
0	3	4.6
1	16	24.6
2	24	36.9
3	18	27.7
4	1	1.6
5	3	4.6

*1 patient missing reRT dose, ^2 patients missing ECOG status.

brain and generally maximum sum plan doses exceeding 100 Gy were recorded. Online treatment verification was performed daily to confirm treatment accuracy. Patients were reviewed weekly and steroids were utilised sparingly to minimise steroid related morbidity.

2.4. Other treatment procedures

2.4.1. Cytotoxic chemotherapy

No concurrent chemotherapy was administered as patients were chemorefractory at the time of reRT. Prior chemotherapy regimens were reported and patient categorised to timing of reRT at second or later relapse.

2.4.2. Bevacizumab

The majority of patients had commenced BEV prior to reRT as part of their prior chemotherapy regimens; and this BEV continued during and after reRT. A dose of 5 mg/m² was utilised with infusions every 2–3 weeks. The BEV naïve patients with glioblastoma generally had BEV commenced in the two weeks prior to reRT; whilst those with prior anaplastic glioma were managed expectantly with BEV held in reserve. BEV was continued indefinitely after reRT until time of BEV limiting toxicity or deterioration in performance status limiting outpatient delivery.

2.4.3. Corticosteroid therapy

Intervention was individualised based on patient features and imaging features. Generally dexamethasone was reduced to 0.5 mg once BEV had been commenced and then continued on that dose until symptomatic progression.

2.5. Follow-up protocol

Patients were reviewed with MRI at one month post reRT and then regularly with MRI every three months or earlier if symptomatic.

2.6. Study endpoints

The primary endpoint was median overall survival (OS) calculated from date of commencement of reRT to either date of death or censure of data at end April 2018. Secondary endpoint was ECOG status at three months post reRT.

2.7. Statistical considerations

All patients had demographic, clinical, survival and treatment data entered into a database at the Northern Sydney Cancer Centre. The Kaplan Meier estimator was used to compute survival. An alpha level of <0.05 was used for statistical significance. Log-rank test was used to compare outcome for risk groups and to investigate associations between the distribution of survival and potential prognostic factors. Variables found to be significant in univariate analysis ($p < 0.05$) were then included in multivariate analysis using a backwards Cox proportional hazards model. Analyses were performed using SPSS software version 21 (SPSS Inc., Chicago, IL, USA) and R (Version 3.2.5).

3. Results

Between 2010 and 2017, 67 patients with recurrent chemorefractory high grade glioma were referred for reRT and eligible for analysis. 60 patients died with a median follow-up for survivors of 25 months (IQR 17.9–59.3 months). The baseline patient characteristics are detailed in Table 1. Briefly, male to female ratio was 1.8 to 1; and median age at reRT was 54 years (range 26–83 years). Fifty-one patients had an initial pathology of glioblastoma multiforme, whilst 16 had anaplastic glioma.

Prior radiation therapy dose was 54–60 Gy in 30–33 fractions in 92.5% of patients. The site of initial relapse after definitive therapy was local in 70.2% of patients whilst 13.4% and 16.4% had predominantly adjacent and distant relapse respectively. Of the 16 patients with an initial diagnosis of anaplastic glioma, all eventually relapsed with contrast enhancing disease and 12 had repeat surgery confirming a diagnosis of GBM.

Prior to reRT, all patients had chemorefractory disease with 94.0% managed at second or later relapse; with the 4 patients managed at first relapse with early reRT being due to a presence of a small volume and predominantly distant failure.

BEV was utilised in 77.6% of patients prior to reRT. Subsequently this increased to 91.0% as 9 of the 15 patients managed without prior BEV required salvage BEV in the six months post reRT for an enlarging contrast enhancing mass.

3.1. Re-irradiation details

All patients were managed with IMRT or VMAT to a median PTV volume of 145.3 cm³ (range 10.6–432.8 cm³). The majority of patients received a reRT dose of either 35 Gy in 15 fractions (52.2%); 40 Gy in 15 fractions (22.3%) or 35 Gy in 10 fractions (8.9%). In the anaplastic glioma patients a more fractionated approach was adopted in 6 patients with a dose of 55 Gy in 25 fractions.

Complete summated dose data was available for 19 patients and is demonstrated in Table 2. The median summated mean dose for the entire brain was 40.9 Gy (range 21.6–74.6 Gy). The median summated max dose (MSMD) in specific critical structures in these patients was 64.0 Gy (range 6.8–97.3 Gy) to the brainstem and 54.9 Gy (range 3.6–91.0 Gy) to the optic chiasm. For the optic nerves the MSMD was 28.9 Gy (range 1.5–83.9 Gy) to the left optic nerve and 26.8 Gy (range 1.6–82.3 Gy) to the right optic nerve.

3.2. Overall survival

The median OS for the total cohort was 7.8 months (95% CI 6.3–9.2 months) (Fig. 1). For patients with initial histopathological diagnosis of GBM this was 7.5 months (95% CI 6.6–8.3 months) compared with anaplastic glioma of 14.6 months (95% CI 6.3–22.9 months).

3.3. Univariate and multivariate analysis

In univariate analysis to determine factors associated with OS in the complete cohort, initial histopathology ($p = 0.006$), ECOG status prior to reRT ($p = 0.007$), time to reRT ($p = 0.001$) and IDH1 mutation status ($p < 0.001$) were all significant (Table 3). In multivariate analysis IDH1 mutation status ($p = 0.041$) and ECOG status prior to reRT ($p < 0.001$) remained significant.

For the cohort of 51 patients with GBM, IDH1 mutation status ($p = 0.009$), time to reRT ($p = 0.001$) and ECOG prior to reRT ($p = 0.003$) were significant in univariate analysis. In multivariate analysis, IDH1 status ($p = 0.027$), time to reRT ($p = 0.017$) and ECOG prior to reRT ($p = 0.011$) remained significant (Table 4).

3.4. Toxicity

In total, 4 patients had radiological evidence of radionecrosis on routine MRI surveillance. Clinically, 1 was grade 4, 2 had grade 3 and 1 had grade 2 radionecrosis. These patients did not receive upfront bevacizumab. The patient with clinical grade 4 radionecrosis required a craniotomy and resection. All four patients subsequently received bevacizumab with radiological and clinical improvements observed.

Table 2
Average summated mean and max dose for 19 patients with complete dose data.

Structure	Median summated mean dose, [Gy, range]	Median summated max dose, [Gy, range]
Brain	40.9 (21.6–74.6)	–
Brain stem	–	64 (6.8–97.3)
Optic chiasm	–	54.9 (3.6–91.0)
Left optic nerve	–	28.9 (1.5–83.9)
Right optic nerve	–	26.8 (1.6–82.3)

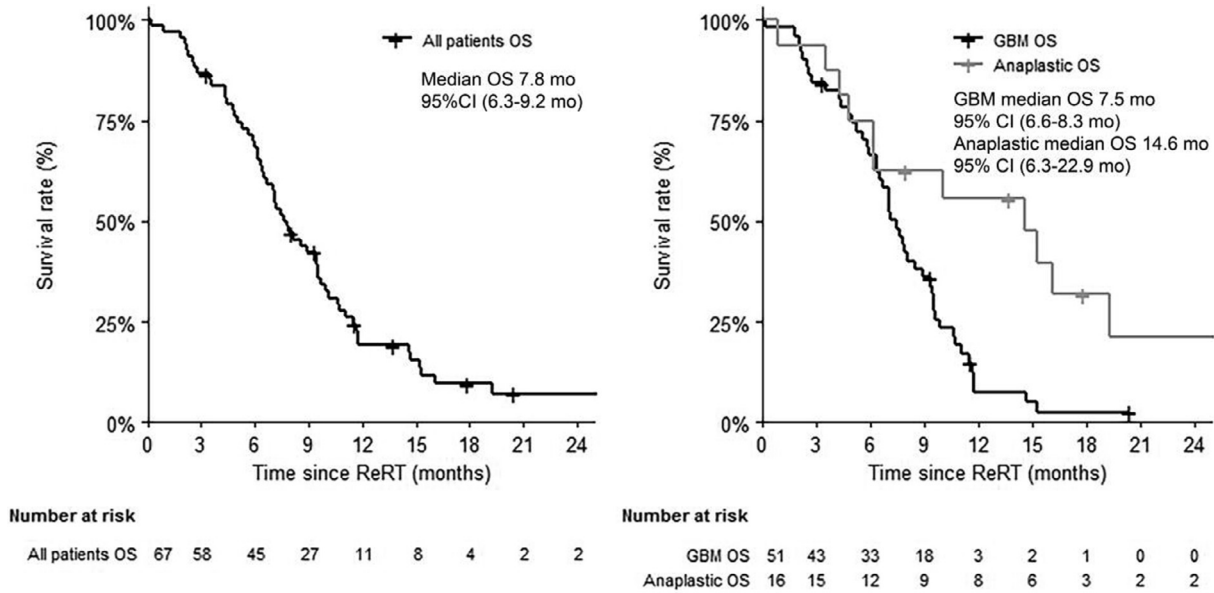


Fig. 1. Survival curves for patients undergoing reirradiation: (Left) Survival curve for all patients undergoing reirradiation (Right) Survival curve for GBM and anaplastic patients undergoing reirradiation.

Table 3
 Univariate and multivariate analysis of clinicopathologic variables in all patients who received re-irradiation.

Characteristics	N = 67	Median Survival, Months (95%CI)	Univariate Hazard ratio	P value	Multivariate HR	P Value
Gender						
Male	43	7.1 (5.7–8.5)	1	0.348		–
Female	24	9.3 (6.8–12.0)	0.774 (0.453–1.322)			
Age at ReRT						
<50 years	25	8.1 (5.3–10.9)	1	0.490		–
>=50 years	42	7.1 (5.3–8.8)	1.209 (0.706–2.069)			
Initial histopathology						
GBM	51	7.5 (6.6–8.3)	1	0.006		0.171
Anaplastic glioma	16	14.6 (6.3–22.9)	0.377 (0.188–0.756)			
IDH1 status						
Non mutated	50	7.1 (6.0–8.2)	1 (referent)	<0.001	1 (referent) 0.378 (0.148–0.963)	0.041
Mutated	17	15.2 (0.2–21.2)				
Disease Location						
Frontal	20	9.6 (6.2–12.9)	1 (Referent)	0.075		–
Temporal	17	6.4 (4.3–8.5)	2.701 (1.256–5.808)			
Parietal	21	7.8 (6.6–9.0)	1.882 (0.927–3.819)			
Occipital	8	3.5 (0–13.0)	3.083 (1.252–7.591)			
Other	1	8.9 (na)	2.223 (0.285–17.353)			
Tumor volume (PTV)						
<=47 mL	8	8.5 (6.6–10.5)	1 (referent)	0.718		–
>47 mL	59	7.1 (5.2–8.9)	0.608 (0.273 – 1.354)			
Time to reRT						
<=21 months (median)	34	6.4 (5.5–7.3)	1 (referent)	0.001		0.106
>21 months	33	9.6 (7.5–11.6)	0.413 (0.240–0.710)			
ECOG prior to ReRT						
0/1	30	9.9 (8.1–11.7)	1 (referent)	0.007	1 (referent) 2.850 (1.614 – 5.033)	<0.001
2/3	37	6.4 (5.5–7.2)	2.059 (1.216–3.489)			
Re-resection						
No	25	7.8 (5.4–10.2)	1 (referent)	0.121		–
Yes	42	7.7 (5.1–10.2)	0.656 (0.385–1.117)			
ReRT dose*						
35 Gy/15#	35	7.9 (6.2–9.7)	1 (referent)	0.104		–
40 Gy/15#	15	7.8 (6.7–8.9)	0.915 (0.473–1.771)			
35 Gy/10#	6	4.3 (0–12.0)	1.216 (0.470–3.143)			
55 Gy/25#	6	DNR median	0.213 (0.051–0.893)			
30 Gy/5# or 25 Gy/5#	4	2.3 (0.9–3.7)	2.340 (0.816–6.708)			
Bevacicuzmab post reRT						
Yes	61	7.9 (6.2–9.6)	1 (referent)	0.948		–
No	6	4.4 (2.0–6.8)	1.031 (0.410–2.597)			

*1 patient missing reRT dose.

Table 4
Subgroup univariate and multivariate analysis of clinicopathologic variables in GBM patients who received re-irradiation.

Characteristics	N = 51	Univariate HR	P value	Multivariate HR	P Value	Median Survival, Months (95%CI)
Gender						
Male	32	1 (referent)	0.223		–	6.7 (5.6–7.8)
Female	19	0.692 (0.380–1.262)				7.8 (5.9–9.6)
Age at ReRT						
<50 years	17	1 (referent)	0.169		–	7.8 (6.9–8.7)
>=50 years	34	1.535 (0.833–2.826)				6.7 (5.1–8.3)
IDH1 status						
Non mutated	47	1 (referent)	0.009	1 (referent)	0.027	7.1 (6.2–7.9)
Mutated	4	0.145 (0.034–0.622)		0.189 (0.043–0.824)		11.8 (10.1–13.4)
Disease Location						
Frontal	12	1 (referent)	0.542		–	8.1 (4.5–11.7)
Temporal	14	1.984 (0.862–4.564)				5.9 (3.4–8.4)
Parietal	16	1.543 (0.670–3.556)				7.2 (6.3–8.1)
Occipital	8	1.967 (0.768–5.037)				3.5 (0–13.0)
Other	1	1.545 (0.194–12.331)				8.9 (na)
Tumor volume (PTV)						
<=47 mL	8	1 (referent)	0.934		–	4.4 (0.1–8.7)
>47 mL	43	1.025 (0.568–1.851)				7.5 (6.6–8.4)
Time to reRT						
<=16 months (median)	27	1 (referent)	0.001	1 (referent)	0.017	5.9 (4.4–7.5)
>16 months	24	0.339 (0.178–0.647)		0.450 (0.234–0.867)		8.5 (6.5–10.6)
ECOG prior to ReRT						
0/1	25	1 (referent)	0.003	1 (referent)	0.011	9.5 (8.0–11.0)
2/3	26	2.493 (1.362 – 4.563)		2.265 (1.210–4.238)		6.4 (5.9–7.9)
Re-resection						
No	22	1 (referent)	0.460		–	7.1 (5.3–8.9)
Yes	29	0.803 (0.448–1.439)				7.2 (6.4–8.0)
ReRT dose [^]						
35 Gy/15#	28	1 (referent)	0.513		–	7.5 (6.1–8.9)
40 Gy/15#	12	0.771 (0.362–1.640)				7.7 (5.7–9.6)
35 Gy/10#	6	1.000 (0.382–2.615)				4.3 (0–12.0)
30 Gy/5# or 25 Gy/5#	4	1.940 (0.667–5.640)				2.3 (5.9–8.4)
Bevacicuzmab post reRT						
Yes	6	1 (referent)	0.544		–	4.4 (2.0–6.8)
No	45	1.251 (0.484–3.231)				7.5 (6.5–8.4)

[^]1 patient missing ReRT dose.

Two other patients had adverse radiological findings. One had evidence of ischemia and another had evidence of bleeding. Both patients were asymptomatic and these changes resolved with the cessation of bevacizumab. No other grade 3 or 4 toxicity related to reRT was observed.

4. Discussion

The current study achieved its aims in demonstrating the feasibility of large volume re-irradiation (ReRT) in patients with recurrent refractory high grade gliomas. Specifically, it was able to assess doses to organs at risk, to demonstrate acceptable levels of toxicity and demonstrated a median OS comparable to previous small volume reRT studies.

One of the central aspects of the current study was the large volumes of tissue retreated. The median PTV of 145 cm³ reflects the nature of this patient group who are chemorefractory with progressive disease extending around the brain adjacent to initial site of disease. This is not selected early stage focal relapsed disease, that may be considered for focal approaches such as repeat craniotomy or stereotactic radiosurgery. These patients did not have other salvage modalities available. This is important as the retreatment of HGGs with radiotherapy historically have been limited to select patients with small volumes of disease. Recent reviews identifying over 40 studies of reRT in HGG's found that the majority of studies treated patients with a PTV < 40 cm³ [1,4]. These studies did demonstrate the safety, efficacy and benefit of small volume reRT in HGGs. This has led to the development of prognostic scores such as the Combs score which help select patients for reRT based on factors such as histopathology, age and time to reirradiation

[5,6]. However, the applicability of these scores to larger volume reRT is unclear. In reviews of the reRT literature, only four studies have been identified where the median re-treatment PTV exceeds 75 cm³. Of these, three were small cohorts with 14–22 patients [7–9]. Perhaps the best evidence to date for the feasibility of large volume reRT is the study by Scholtyssek et al. (2013) [10]. In their study of 64 patients, they investigated reRT with and without concurrent chemotherapy in a cohort with a median PTV of 110 cm³. The median OS was 7.7 months with minimal grade 3 or 4 toxicity. Comparatively, the current cohort had a median OS of 7.8 months with few cases of grade 3 or 4 toxicity related to reRT. Our figures, which are similar to prior studies of small volume reRT, suggests the feasibility of re-irradiating large volume disease [1].

The use of concurrent BEV in the majority of re-treated patients was another crucial part of the current study because of its possible role in mitigating radionecrosis. Traditionally, radionecrosis has been the barrier to treating larger volume disease in the setting of recurrent CNS malignancies. Escalating doses and volumes of brain treated are correlated with increasing risk of radionecrosis. The role of BEV in diminishing this risk was demonstrated in the seminal RCT by Levin et al. (2011) who demonstrated it to be an effective treatment for CNS radionecrosis [11]. One strength of the current study, compared to prior studies, was that we were able to assess radionecrosis radiologically with routine 3-monthly MRIs as opposed to clinical follow-up alone. Four cases of suspected radiological radionecrosis were identified, with one being confirmed histopathologically. All cases occurred in patients who were not on concurrent bevacizumab during reRT. Subsequent salvage with BEV resulted in significant reduction in MR contrast enhancement. This may correlate with an improvement in suspected radionecrosis.

These results suggest the role of BEV as a protective agent against radionecrosis and also suggest its possible role in large volume reRT. More evidence however is needed for BEV beyond this context. The current best evidence has not shown a definitive role for BEV up-front with two separate phase III trials failing to show an OS benefit [12,13]. In the relapsed setting, the evidence is more unclear. In multiple trials looking at concurrent BEV with different systemic treatments, there also has been no proven OS benefit [14,15]. However, the SEER dataset has shown some improvement in OS at a population level of GBM patients since the introduction of BEV [16]. Certainly, the role of concurrent BEV with reRT is still not well defined. There is therefore much anticipation regarding the results of RTOG 1205 (NCT 01730950), a phase II RCT randomising patients at recurrence to BEV alone or concurrent BEV with reRT of 35 Gy in 10 fractions for patients with recurrent tumours less than 50 mm. The primary endpoint assessing OS and the secondary endpoints assessing CNS toxicity will clarify the use of BEV. The results are expected in 2023. In the interim, the results of the current study provides more evidence to the possible benefit of concurrent BEV and reRT. In a prior study of GBM patients, median OS after progression on bevacizumab was only 4.5 months [17]. In the current study, the median OS was 7.5 months in the GBM subgroup who almost all progressed on BEV.

The current study was also able to offer some insight on sum doses and acceptable tolerances with large volume reRT. QUANTEC data suggests maximal doses of 54 Gy to both the brainstem and optic chiasm to avoid the risk of myelopathy [18,19]. In the context of reRT in HGGs, maximal acceptable tolerances are not well-quantified and current limited evidence deals with smaller PTVs and lower summated doses [20]. There is preclinical data to conservatively suggest 61% recovery in the spinal cord at one year post initial irradiation and this is thought to be likely applicable to other CNS tissues [21]. These models would suggest that maximum summated doses of up to 86 Gy to the optic chiasm and brainstem in the reRT setting might be tolerated. In our cohort, of the 19 patients who had summated data, three patients exceeded dose tolerances above 86 Gy for at least one of the noted critical structures. However, no patients reported myelopathy during follow up. We should note that assessment of all late toxicity would be limited by the short survival of patients. Furthermore the variety of reRT dose fractionations, which include some patients receiving hypofractionated regimens, make it difficult to evaluate toxicities. Nevertheless, our results suggest that concurrent administration of BEV facilitated larger reRT doses and volumes.

The current study demonstrated a need for improved selection of patients for reRT. Currently, the only validated selection criterion are those of the Combs scores [5,6]. These stratification scores utilise factors such as time to reRT, PTV volume and performance status to identify suitable candidates for reRT. In the current study, only ECOG status and IDH1 mutation status were significant in multivariate analysis. Other factors like median PTV and time to reRT were not significant. The reasons for these differences are likely multifactorial and reflect heterogeneity between cohorts. For example, our median PTV was far higher than past cohorts. Another difference was that the median time between diagnosis and reRT was also substantially longer than past cohorts at 21 months. However, this figure includes a substantial number of patients with anaplastic gliomas and also a cohort of patients who are on last-line treatment. Other cohorts often included patients earlier on in their treatment pathway. These differences support the idea that other factors will be needed to select patients with large volume recurrence for reRT.

The current study did have some limitations. Firstly, this study was a relatively small retrospective study and therefore low grade toxicities were difficult to quantify and often not routinely documented. Secondly, although this study was looking primarily at

large volume re-RT, there were a small number of patients ($n = 8$) within our cohort who did have smaller treatment volumes of less than 47 cm³. Finally, our functional outcomes was limited to ECOG status prior to reRT and 3 months after. More detailed outcomes could give a clearer picture of the tolerability of reRT. Future prospective trials should address all these limitations in order to achieve optimal outcomes in the reRT population.

5. Conclusion

The current study demonstrated the feasibility and safety of concurrent BEV and reRT in the management of patients with chemorefractory large volume relapsed high grade glioma. It is a management option that is available to patients with good performance status to extend survival duration.

Patient consent statement

All patients included in the current study have consented for the use of their data for research purposes.

Declaration of Competing Interest

The authors declare that they have no known competing financial interests or personal relationships that could have appeared to influence the work reported in this paper.

References

- [1] Ho ALK, Jena R. Re-irradiation in the brain: primary gliomas. *Clin Oncol (R Coll Radiol)* 2018;30:124–36.
- [2] Niyazi M, Ganswindt U, Schwarz SB, Kreth FW, Tonn JC, Geisler J, et al. Irradiation and bevacizumab in high-grade glioma retreatment settings. *Int J Radiat Oncol Biol Phys* 2012;82:67–76.
- [3] Palmer JD, Bhamidipati D, Song A, Eldredge-Hindy HB, Siglin J, Dan TD, et al. Bevacizumab and re-irradiation for recurrent high grade gliomas: does sequence matter?. *J Neurooncol* 2018;140:623–8.
- [4] Scoccianti S, Francolini G, Carta GA, Greto D, Detti B, Simontacchi G, et al. Re-irradiation as salvage treatment in recurrent glioblastoma: a comprehensive literature review to provide practical answers to frequently asked questions. *Crit Rev Oncol/Hematol* 2018;126:80–91.
- [5] Combs SE, Edler L, Rausch R, Welzel T, Wick W, Debus J. Generation and validation of a prognostic score to predict outcome after re-irradiation of recurrent glioma. *Acta Oncol* 2013;52:147–52.
- [6] Kessel KA, Hesse J, Straube C, Zimmer C, Schmidt-Graf F, Schlegel J, et al. Modification and optimization of an established prognostic score after re-irradiation of recurrent glioma. *PLoS ONE* 2017;12:e0180457.
- [7] Hundesberger T, Brugge D, Putora PM, Weder P, Weber J, Plasswilm L. Re-irradiation with and without bevacizumab as salvage therapy for recurrent or progressive high-grade gliomas. *J Neurooncol* 2013;112:133–9.
- [8] Bartsch R, Weitmann HD, Pennwieser W, Wenzel C, Muschitz S, Baldass M, et al. Retrospective analysis of re-irradiation in malignant glioma: a single-center experience. *Wien Klin Wochenschr* 2005;117:821–6.
- [9] Back M, Gzell CE, Kastelan M, Guo L, Wheeler HR. Large volume re-irradiation with bevacizumab is a feasible salvage option for patients with refractory high-grade glioma. *Neurooncol Pract* 2015;2:48–53.
- [10] Scholtyssek F, Zwiener I, Schlamann A, Seidel C, Meixensberger J, Bauer M, et al. Reirradiation in progressive high-grade gliomas: outcome, role of concurrent chemotherapy, prognostic factors and validation of a new prognostic score with an independent patient cohort. *Radiat Oncol* 2013;8:161.
- [11] Levin VA, Bidaut L, Hou P, Kumar AJ, Wefel JS, Bekele BN, et al. Randomized double-blind placebo-controlled trial of bevacizumab therapy for radiation necrosis of the central nervous system. *Int J Radiat Oncol Biol Phys* 2011;79:1487–95.
- [12] Fu P, He YS, Huang Q, Ding T, Cen YC, Zhao HY, et al. Bevacizumab treatment for newly diagnosed glioblastoma: systematic review and meta-analysis of clinical trials. *Mol Clin Oncol* 2016;4:833–8.
- [13] Tipping M, Eickhoff J, Ian Robins H. Clinical outcomes in recurrent glioblastoma with bevacizumab therapy: an analysis of the literature. *J Clin Neurosci* 2017;44:101–6.
- [14] van den Bent MJ, Klein M, Smits M, Reijneveld JC, French PJ, Clement P, et al. Bevacizumab and temozolomide in patients with first recurrence of WHO grade II and III glioma, without 1p/19q co-deletion (TAVAREC): a randomised controlled phase 2 EORTC trial. *Lancet Oncol* 2018;19:1170–9.
- [15] Wick W, Gorlia T, Bendszus M, Taphoorn M, Sahm F, Harting I, et al. Lomustine and bevacizumab in progressive glioblastoma. *N Engl J Med* 2017;377:1954–63.

- [16] Johnson DR, Omuro AMP, Ravelo A, Sommer N, Guerin A, Ionescu-Ittu R, et al. Overall survival in patients with glioblastoma before and after bevacizumab approval. *Curr Med Res Opin* 2018;34:813–20.
- [17] Iwamoto FM, Abrey LE, Beal K, Gutin PH, Rosenblum MK, Reuter VE, et al. Patterns of relapse and prognosis after bevacizumab failure in recurrent glioblastoma. *Neurology* 2009;73:1200–6.
- [18] Mayo C, Martel MK, Marks LB, Flickinger J, Nam J, Kirkpatrick J. Radiation dose-volume effects of optic nerves and chiasm. *Int J Radiat Oncol Biol Phys* 2010;76:S28–35.
- [19] Mayo C, Yorke E, Merchant TE. Radiation associated brainstem injury. *Int J Radiat Oncol Biol Phys* 2010;76:S36–41.
- [20] Krauze AV, Ning H, Cheng JY, Zhuge Y, Cooley-Zgela T, Smart DK, et al. Dose volume toxicity analysis for organs at risk in patients receiving reirradiation for recurrent high grade glioma. *Int J Radiat Oncol Biol Phys* 2015;93:E86.
- [21] Kirkpatrick JP, van der Kogel AJ, Schultheiss TE. Radiation dose-volume effects in the spinal cord. *Int J Radiat Oncol Biol Phys* 2010;76:S42–9.