

LETTER TO THE EDITOR**TO THE EDITOR****Glioblastoma Spinal Cord Metastasis With Short-Term Clinical Improvement After Radiation**

Keywords: Neuro-oncology, Radiotherapy, Rehabilitation medicine

Glioblastoma can spread in several ways. Intraparenchymal extension along white matter tracts is the most common method of spreading. Dissemination of glioblastoma through cerebrospinal fluid (CSF) can occur, causing drop metastases, bulky leptomeningeal disease (LMD), or spinal intramedullary metastasis. Very rarely, glioblastoma can have hematogenous spread: to the lungs, bones, lymph nodes, or liver.¹ Glioblastoma can spread systemically through a breached blood–brain barrier. The tumor itself can cause that initial breach but surgical procedures can also be the cause. Thereafter, glioblastoma cells can acquire mesenchymal features of invasiveness and develop resistance to immune defense mechanisms. The meningeal lymphatic system drains fluid from the glymphatic system to the meningeal compartment and deep cervical lymph nodes. These lymphatic vessels in the meninges may facilitate glioblastoma dissemination.²

External beam radiotherapy may be used to treat spinal cord metastases in glioblastoma. Biopsy may be performed to establish diagnosis, although this may not always be feasible depending on performance status or location, and decision to biopsy may be deferred if suspicion for metastasis is high in a patient with a pathologically confirmed intracranial diagnosis.

The prevailing dogma is that external beam radiotherapy can stop clinical decline but will not reverse deficits.^{3,4} Our patient's clinical improvement after radiotherapy challenges that dogma.

A 53-year-old man developed headaches and blurred vision. He had no other relevant medical history. Magnetic resonance imaging (MRI) showed a right temporal rim-enhancing lesion. He had a subtotal resection of the lesion. His tumor was isocitrate dehydrogenase wildtype and had the typical histological appearance of glioblastoma, with astrocytic cells, mitotic figures, microvascular proliferation, and necrosis. The tumor was BRAF V600E negative. p53 was extensively expressed, indicative of mutation in the corresponding gene. He underwent concomitant chemoradiotherapy – daily temozolomide plus 60 Gy focal radiotherapy in 30 fractions – and then ongoing adjuvant monthly temozolomide for his glioblastoma.

Ten months following initial diagnosis, during his seventh cycle of adjuvant temozolomide, he developed low back pain, followed by progressive right leg weakness. His legs were numb. He had urinary incontinence and decreased saddle sensation. His arm strength was 5/5 bilaterally. His left leg strength was 4/5 on the Medical Research Council (MRC) scale. The strength of his right hip flexors was 1/5 and ankle dorsiflexors 3/5. Deep tendon reflexes were brisk at his right knee and ankle. Pinprick sensation was reduced in the left leg, while vibration was reduced in the right leg. He had decreased pinprick sensation below the navel bilaterally and could not walk.

We diagnosed him with thoracic myelopathy and partial Brown–Séquard syndrome. Given his known glioblastoma, we were concerned about spinal cord metastasis. We arranged for spine imaging and admission to hospital directly from clinic.

His MRI showed an intramedullary, enhancing lesion centered at T11 (Figure 1, panels A, C). There was T2-weighted cord signal change from T4 through to the conus (Figure 1, panel B). Given the clinical context, his imaging was diagnostic for intramedullary metastasis from his glioblastoma. There was no evidence of nodular intradural extramedullary LMD. His MRI head showed no intracranial progression of his tumor.

He was treated with dexamethasone, 10 mg IV once on the day of presentation (followed by oral dexamethasone 8 mg twice daily thereafter for 1 month). He received external beam radiotherapy to the thoracic spine 3 days after admission. Radiotherapy was given to a dose of 30 Gy from T3 to L3 inclusive, in 10 daily fractions on weekdays. He began improving toward the end of his radiotherapy. He was able to taper off dexamethasone 2 weeks following radiation completion, and he continued to recover over the next 5 months.

He was admitted for intensive spinal cord rehabilitation for 5 weeks, and he made good progress. Once he was discharged home, we switched his temozolomide to lomustine.

Two months following completion of radiotherapy, he was walking with a cane. Five months following radiotherapy, he did not need the cane. He felt stronger after the spine radiotherapy and inpatient rehabilitation. He had normal strength of the left leg and 4/5 hip flexion and ankle dorsiflexion on the right. Despite the improved leg strength, his spine imaging did not change. He was grateful for the quality time he was able to spend with his friends and family over the holidays.

Unfortunately, 6 months following radiotherapy, he developed weakness and then paralysis of his legs. He lost bladder control. Repeat neuroimaging showed progression of his intracranial disease plus some increased T2 signal in his spinal cord, suggesting progressive disease there, too. We stopped his chemotherapy and arranged for home palliative care services to keep him comfortable. He died 19 months after his glioblastoma diagnosis.

Our patient had a better short-term clinical outcome than other published case reports of spinal intramedullary metastasis. Our patient's strength went from MRC 1/5 to MRC 4/5. There is one report of slight clinically improvement with radiotherapy in which the patient's leg strength improved from MRC 1/5 to MRC 2/5.⁵ Most reported cases describe no improvement with radiotherapy.^{4,5} The patient showed improvement clinically in the short term following radiotherapy without any change in the MRI scan.

Overt spread of intracranial glioblastoma to the spinal cord is rare.⁶ The incidence rate is 2–4%.^{7–9} Asymptomatic microscopic metastasis of glioblastoma is more common, with an autopsy series showing prevalence as high as 25%.^{3,10} A Memorial Sloan Kettering retrospective review analyzed 24 glioblastoma patients who developed LMD. Their median overall survival was 3.5 months from the time of LMD diagnosis. Patients treated for LMD with chemotherapy and radiation had a significantly

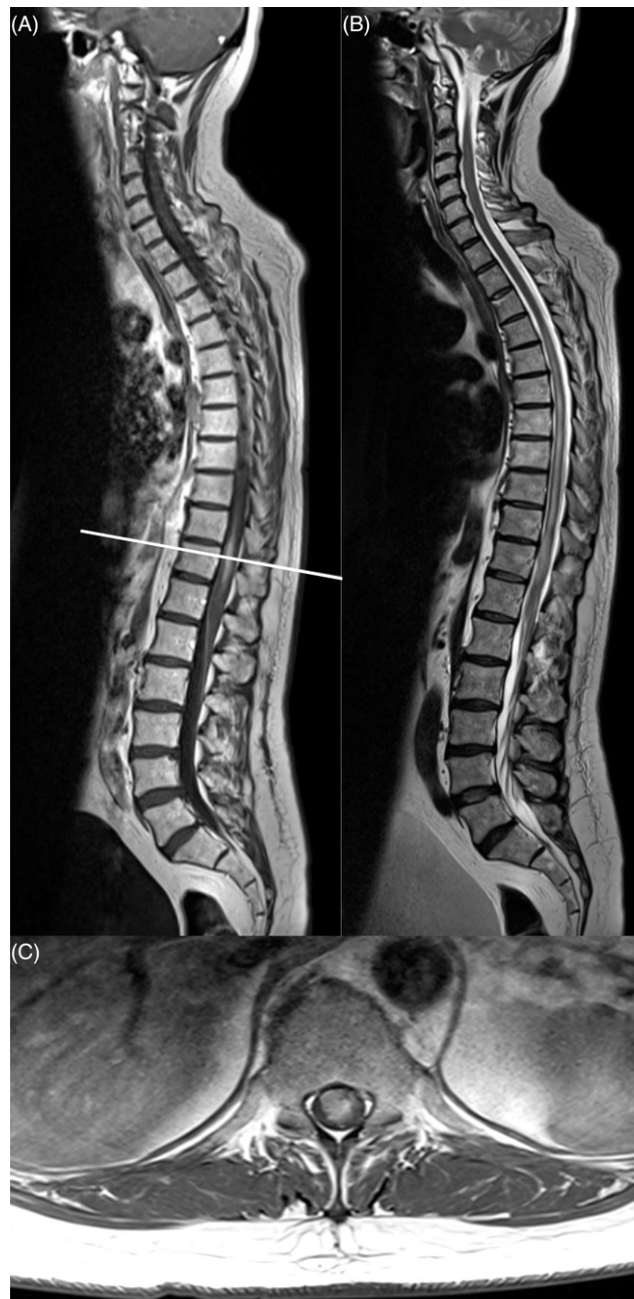

Figure 1: Sagittal T1-weighted post-contrast MRI spine from his initial hospitalization for spinal cord symptoms (A) revealed an enhancing focus centered around T11. Notably, there was no leptomeningeal enhancement or any bulky enhancing disease. There was T2-bright cord signal change (B) from T4 through to the conus. Axial T1-weighted post-contrast images (C) showed that the lesion was intramedullary. Given the clinical context, these images were diagnostic of spinal intramedullary glioblastoma metastasis.

prolonged survival (7.7 months) compared to chemotherapy alone, radiation alone, or palliative care.⁹

There are some predictors of glioblastoma metastasis. Theoretically, intraventricular tumor location, cerebellar tumor location, and intraoperative cyst rupture might be associated with CSF spread.⁷ Some histologic subtypes have a tendency to metastasize. Gliosarcomas are more likely to have extracranial spread, often by way of local invasion.¹¹ Glioblastoma with primitive neuroectodermal tumor components has a tendency to

metastasize.⁹ Epithelioid glioblastoma tends to spread to the leptomeninges.^{12,13} Our patient did not have any of these imaging or histological features, thus clinicians should be prepared to diagnose spinal cord metastasis in any patient with glioblastoma.

No molecular markers strongly predict risk of LMD in glioblastoma. Point mutations of BRAF V600E probably elevate the risk of LMD.¹² Mutations of p53 may be associated with LMD and were seen in four of six patients in one series.¹³ Future studies on molecular markers of LMD may be informative.

Glioblastoma spinal cord metastases can have different appearances on neuroimaging. There can be intramedullary lesions or there can be nodular leptomeningeal lesions. Despite these different patterns of appearance on spine imaging, they likely share the same underlying pathophysiology. Hamilton et al. described a patient who developed spinal intramedullary spread of his supratentorial glioblastoma.⁶ He had surgery to establish a diagnosis, and while there was no evidence of leptomeningeal dissemination on imaging or biopsy, there were microscopic arachnoid deposits of tumor. Thus, spinal intramedullary disease likely comes from direct microscopic spread of subarachnoid metastasis.

Symptomatic spinal cord metastasis of glioblastoma is a disabling consequence of an already-debilitating cancer. Our case illustrates that with prompt recognition, radiotherapy, and rehabilitation of spinal cord glioblastoma metastasis, patients can derive meaningful, albeit temporary, improvement of clinical function and quality of life. Treatment decisions should be individualized based on each patient's performance status, desire for treatment, and goals of care.

CONFLICT OF INTEREST


None.

STATEMENT OF AUTHORSHIP

Manuscript concept and case review: SAC and ISV. Critical revision of manuscript for intellectual content: DGM and WPM. All authors approved the final version of the manuscript to be published.

CONSENT

The patient gave written, informed consent to have this case report published. He reviewed a version of the manuscript prior to its submission.

*Seth A. Climans 

Princess Margaret Cancer Centre, Department of Medical Oncology, Toronto, Ontario, Canada

*Indu S. Voruganti

Princess Margaret Cancer Centre, Department of Radiation Oncology, Toronto, Ontario, Canada

David G. Munoz

Department of Pathology and Laboratory Medicine, St Michael's Hospital, Toronto, Ontario, Canada

Warren P. Mason

Princess Margaret Cancer Centre, Department of Medical Oncology, Toronto, Ontario, Canada

Correspondence to: Seth A. Climans, Princess Margaret Cancer Centre, Department of Medical Oncology, 610 University Ave, Room 18-715, Toronto, Ontario, Canada M5G 2C1. Email: seth.climans@gmail.com

*Shared co-first authorship

REFERENCES

1. da Cunha MLV, Maldaun MVC. Metastasis from glioblastoma multiforme: A meta-analysis. *Rev Assoc Med Bras*. 2019; 65:424–33.
2. Carvalho JADV, Barbosa CC de L, Feher O, et al. Systemic dissemination of glioblastoma: Literature review. *Rev Assoc Med Bras* (1992). 2019;65:460–68.
3. Vertosick FT, Selker RG. Brain stem and spinal metastases of supratentorial glioblastoma multiforme: A clinical series. *Neurosurgery*. 1990;27:516–22.
4. Alatakis S, Malham GM, Thien C. Spinal leptomeningeal metastasis from cerebral glioblastoma multiforme presenting with radicular pain: case report and literature review. *Surg Neurol*. 2001;56:33–8.
5. Scoccianti S, Detti B, Meattini I, et al. Symptomatic leptomeningeal and intramedullary metastases from intracranial glioblastoma multiforme: A case report. *Tumori*. 2008;94:877–81.
6. Hamilton MG, Tranmer BI, Hagen NA. Supratentorial glioblastoma with spinal cord intramedullary metastasis. *Can J Neurol Sci*. 1993;20:65–8.
7. Vollmer K, Pantazis G, Añon J, Roelcke U, Schwyzer L. Spinal metastases of supratentorial glioblastoma with primitive neuronal component. *World Neurosurg*. 2019;2:1–6.
8. Mandel JJ, Yust-Katz S, Cachia D, et al. Leptomeningeal dissemination in glioblastoma; an inspection of risk factors, treatment, and outcomes at a single institution. *J Neurooncol*. 2014; 120:597–605.
9. Andersen BM, Miranda C, Hatzoglou V, DeAngelis LM, Miller AM. Leptomeningeal metastases in glioma: The Memorial Sloan Kettering Cancer Center experience. *Neurology*. 2019;92: e2483–91.
10. Rosen J, Blau T, Grau SJ, Barbe MT, Fink GR, Galldiks N. Extracranial metastases of a cerebral glioblastoma: A case report and review of the literature. *Case Rep Oncol*. 2018; 11:591–600.
11. Nørøxe DS, Michaelsen SR, Broholm H, Møller S, Poulsen HS, Lassen U. Extracranial metastases in glioblastoma—Two case stories. *Clin Case Rep*. 2018;7:289–94.
12. Lim-Fat MJ, Song KW, Wen PY, Reardon DA, Gerstner ER, Arrillaga-Romany I. Clinical, radiological, and genomic features of BRAF V600E-mutated adult glioblastoma. *J Clin Oncol*. 2020;38:2554.
13. Alnahas I, Guillermo Prieto Eibl P, Gonzalez J, Giglio P, Puduvalli VK. Leptomeningeal spread of glioma in the molecular era. *J Clin Oncol*. 2019;37:e13537.