

Case Report

Primary central nervous system lymphoma and 5-aminolevulinic acid

Pierre Ferrer¹, Pablo Barbero¹, Gonzalo Monedero², Anna Lo Presti¹, Bartolome Bejarano³, Juan Ramon Penanes¹

Departments of ¹Neurosurgery and ²Radiology, Fundacion Jimenez Diaz University Hospital, Madrid, ³Department of Neurosurgery, University Clinic of Navarra, Pamplona, Navarra, Spain.

E-mail: *Pierre Ferrer - pierre.ferrer@quironsalud.es; Pablo Barbero - pablo.barbero@quironsalud.es; Gonzalo Monedero - gonzalo.monedero@quironsalud.es; Anna Lo Presti - alopresti@fjd.es; Bartolome Bejarano - bbejarano@unav.es; Juan Ramon Penanes - jrpenanes@gmail.com



*Corresponding author:

Pierre Ferrer,
Department of Neurosurgery,
Fundacion Jimenez Diaz
University Hospital, Avda.
Reyes Catolicos, 2,
Madrid-28040, Spain.

pierre.ferrer@quironsalud.es

Received : 15 April 2020

Accepted : 01 May 2020

Published : 23 May 2020

DOI

10.25259/SNI_185_2020

Quick Response Code:



ABSTRACT

Background: Despite surgical resection of primary central nervous system lymphomas (PCNSL) having been always discouraged, recent evidence supports that it might improve prognosis in this patient population. Five-aminolevulinic acid-derived fluorescence is widely used for the resection of malignant gliomas, but its role in PCNSL surgery remains unclear.

Case Description: We present two patients with a solitary solid intraparenchymal mass. As high-grade glioma led the list of differential diagnosis (other possibilities were metastasis, abscess, and PCNSL), a five-aminolevulinic acid-guided complete resection (with strong fluorescence in both cases) was done. Surgery was uneventfully carried on with complete resection until five-aminolevulinic acid-induced fluorescence was no longer evident. After surgery, patients have no neurological deficits and had good recovery. Pathological examination revealed that both tumors were PCNSL. Adjuvant radiotherapy and chemotherapy were started. After 1 year of follow-up, patients have good evolution and have no recurrences.

Conclusion: These cases add to the growing literature which shows that surgery might play an important role in the management of PCNSL with an accessible and single lesion. Five-aminolevulinic acid could also be a useful tool to achieve complete resection and improve prognosis in this group of patients.

Key words: 5-Aminolevulinic acid, Brain injuries, Lymphoma, Neuro-oncology, Neurosurgery

INTRODUCTION

Surgical resection of primary central nervous system lymphoma (PCNSL) is not routinely performed as its conventional management has regularly consisted of radiation treatment and chemotherapy after obtaining pathology diagnosis through biopsy. In addition, the role of 5-aminolevulinic acid (5-ALA)-induced fluorescence which has been established almost as protocol for malignant gliomas resection remains unexplored in PCNSL. Here, we describe two cases of PCNSL treated using 5-ALA-induced fluorescence-guided surgical resection with good clinical and radiological outcome.

CASE DESCRIPTION

We present two cases. They were in their sixties, a man (patient 1) and a woman (patient 2) without any significant medical history, who presented to our emergency department with headache.

This is an open-access article distributed under the terms of the Creative Commons Attribution-Non Commercial-Share Alike 4.0 License, which allows others to remix, tweak, and build upon the work non-commercially, as long as the author is credited and the new creations are licensed under the identical terms.

©2020 Published by Scientific Scholar on behalf of Surgical Neurology International

Neurological examination was normal. Magnetic resonance image (MRI) of the brain demonstrated in both cases a solitary solid intraparenchymal mass in the right frontal lobe with perilesional edema. The lesions were hypointense in noncontrast T1-weighted images and hyperintense in T2-weighted images. After contrast administration, both lesions enhanced with a ring-like pattern [Figure 1]. There was restricted diffusion, and only in case 2, minor increment of relative blood volume on perfusion maps was evident (about 1.6 respect to the healthy contralateral white matter) [Figure 2]. Differential diagnosis included high-grade glioma, metastasis, and abscess; however, the presence of marked restricted diffusion forced us to consider PCNSL as a possible diagnosis as well.

As high-grade glioma led the list of differential diagnosis, 5-ALA-guided surgery was recommended. During the intervention, there was strong 5-ALA-induced tumor fluorescence in both cases. Surgery was done with the navigation system StealthStation™ S8 (Medtronic, Minneapolis, USA), and the area of 5-ALA fluorescence corresponds exactly with the gadolinium enhancement on MRI in both cases. Surgery was uneventfully carried on until 5-ALA-induced fluorescence was no longer evident [Figure 3]. Postoperative MRI confirmed total resection, presenting only milimetric remains in the surgical site in patient 2 [Figure 4].

Pathological examination confirms that both tumors were PCNSL. They showed diffuse lymphoid cell proliferation

immunoreactive for B-cell marker but not for T-cell marker [Figure 5]. After surgery, an adjuvant chemotherapy treatment started. After an initial slight radiological worsening, whole brain radiotherapy was initiated. The patients presented a very good response to the treatment. After a 1 year follow-up, brain MRI shows no recurrence with complete remission and patients present with a Karnofsky performance status scale of 90.

DISCUSSION

PCNSL are rare and aggressive central nervous system (CNS) neoplasms.^[10,11] Radiologically, the lesions may be single or multifocal. The most common locations are subcortical regions (most frequent in frontal lobe) and periventricular structures. They usually enhance homogeneously after contrast administration and have restricted diffusion;^[5,7] however, in case of immunosuppression, the enhancement pattern may be more heterogeneous or even be absent. Neovascularization is not a prominent feature, as seen by low cerebral blood volume on perfusion studies.^[9]

Nowadays, the management of PCNSL consists of biopsy to obtain pathological diagnosis followed by chemotherapy and radiation therapy.^[8,9] Some authors have reported worse outcomes in patients who underwent surgical resection.^[1,3] However, these conclusions must be taken cautiously since most of these studies were done previous to the development of modern surgical techniques, chemotherapy and imaging.^[14]

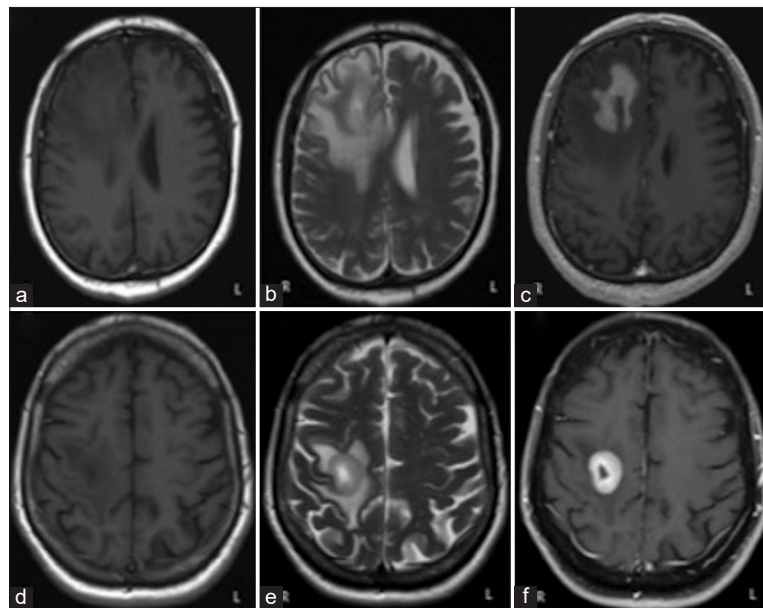


Figure 1: The images a, b, and c correspond to the patient 1. The images d, e, and f correspond to the patient 2. In both cases, we can appreciate a single intra-axial lesion in the right frontal lobe, prominently hypointense in T1 sequences (a and d) and hyperintense in T2 sequences (b and e). It shows intense contrast enhancement with hypocaptant center of cystic/necrotic aspect and is surrounded by a large halo of edema with vasogenic characteristics (c and f).

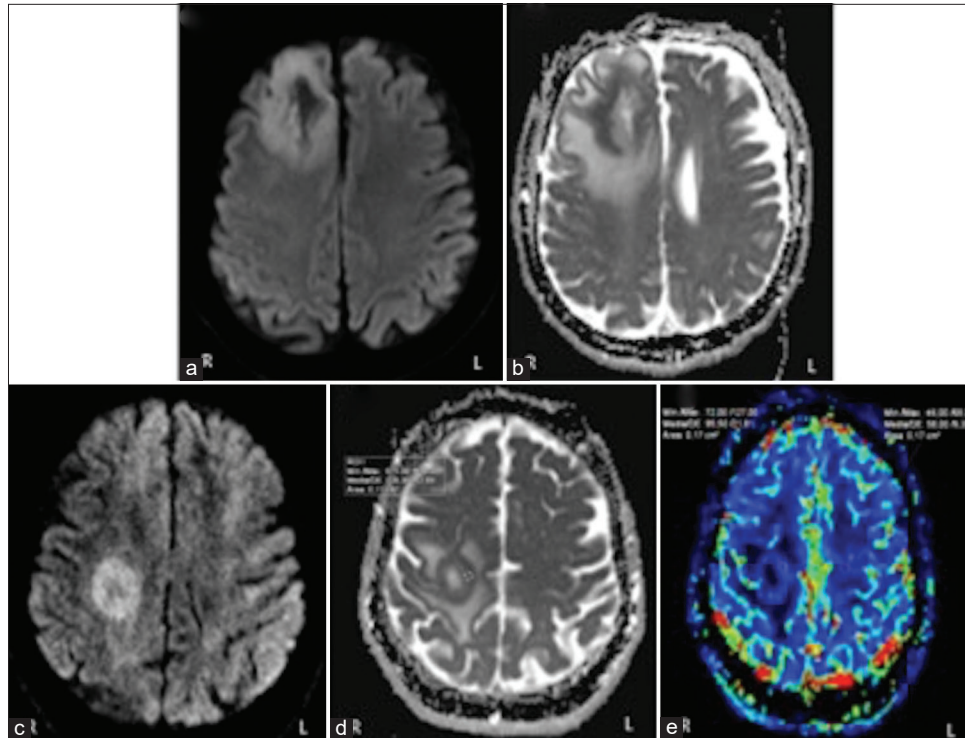


Figure 2: The images a and b correspond to the patient 1. The images c, d, and e correspond to the patient 2. Diffusion-weighted image demonstrate a clear rim of restricted diffusion in its solid marginal components: periphery of the lesion evince hyperintensity on diffusion-weighted imaging (a and c) and very low values on apparent diffusion coefficient map (b and d). In the perfusion study of the patient 2 (e), the peripheral region of the lesion manifests a slight increase in relative cerebral blood volume about 1.6 respect to the healthy contralateral white matter.

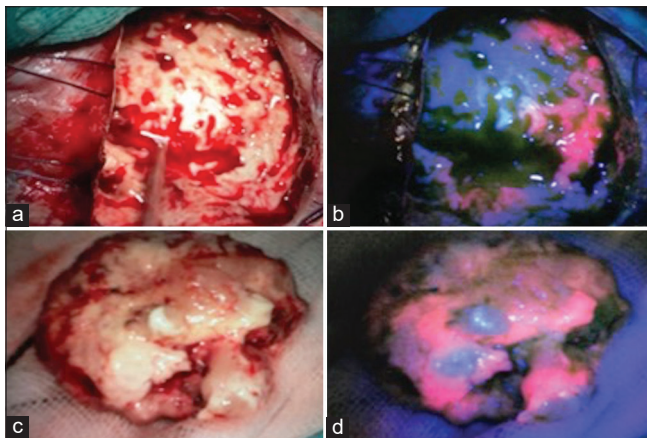


Figure 3: All images belong to the patient 1. These images correspond to the surgical site (a and b) and the tumor resection (c and d). We can appreciate strong red fluorescence under blue light illumination (OPMI/Pentero, Carl Zeiss, Oberkochen, Germany).

New advances in surgical technology and adjuvant treatments have led to more aggressive approaches reconsidering the role of surgical resection in PCNSL.^[2,6,12,14] Bellinzona *et al.*^[2] could not demonstrate a clear benefit from surgery in all patients with PCNSL, but they suggested that it might be a subgroup of patients with large single space-

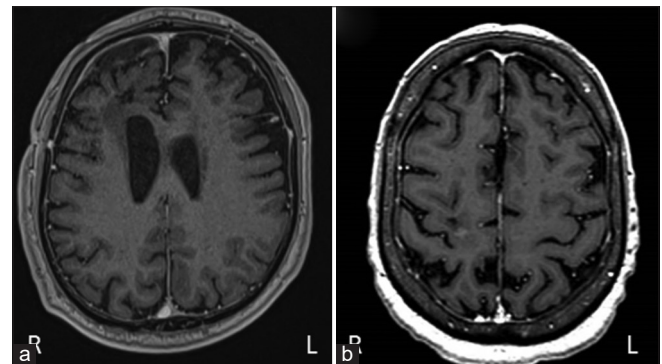


Figure 4: Postoperative magnetic resonance image (contrast-enhanced T1-weighted images). Total resection of the tumor was achieved in the patient 1 (a). The patient 2 present millimetric remains in the surgical site (b).

occupying lesions and deteriorating neurological status who might benefit from it. Weller *et al.*^[12] performed a secondary analysis of the German PCNSL Study Group-1 trial, and, considering that there were no significant differences in the baselines characteristic of both study groups such as age and Karnofsky performance status, they concluded that progression-free survival and overall survival were significantly shorter in biopsied patients compared to patients

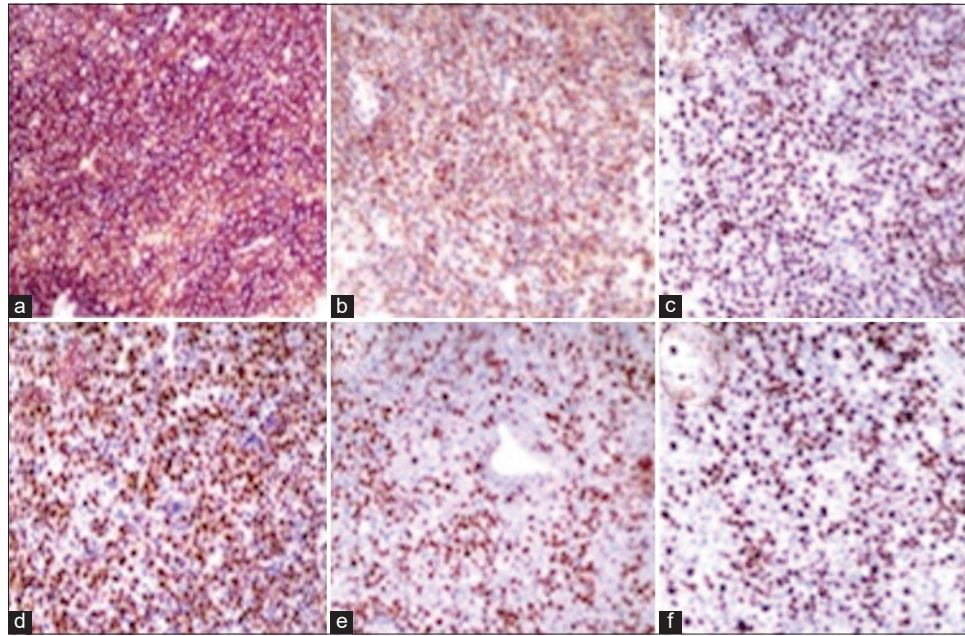


Figure 5: All images belong to the patient 2. Paraffin section with immunoperoxidase technique $\times 10$. Neoplastic cells express CD20 (a), BCL2 (b), BCL6 (c), MUM1 (d), and MYC (e). Ki-67 proliferation index is high (f).

with subtotal or gross total resection (GTR). The impact of extent of resection was similar for progression-free survival but less prominent for overall survival when adjusted for the number of lesions. Interestingly, there was no difference in progression-free survival or overall survival between patients who underwent GTR versus subtotal resection. While this study was limited as a *post hoc* analysis of randomized data, it suggests a survival benefit associated with cytoreductive surgery for PCNSL. Jelicic *et al.*^[6] published in 2015 a 10-year retrospective series of patients who underwent complete resection and had a significantly longer overall survival than patients who underwent either subtotal resection or biopsy only. Despite limited by its small sample size, retrospective nature, and lack of reported complications, this study suggests a potential benefit not only from surgical resection but also encourages surgeons to achieve GTR to improve prognosis in patients with PCNSL.

While the use of 5-ALA is known to be associated with increased extent of resection that leads to improved progression-free survival in patients with high-grade gliomas, its role in PCNSL remains unclear. Yamamoto *et al.*^[13] reported 41 patients with PCNSL diagnostic biopsies of which 34 (corresponding to 82.9% of the samples) had fluorescence with 5-ALA. This high percentage of fluorescence of PCNSL has been corroborated in other series.^[4] To the light of scientific literature and our experience, the use of fluorescence could not be restricted to gliomas. In the case of PCNSL, 5-ALA could provide an increased extent of resection and, according to the latest studies, a longer overall survival.

CONCLUSION

PCNSL is rare primary CNS tumors associated with substantial morbidity and mortality. The field of this tumor management is evolving substantially in recent decades and will continue to do so. These cases add to the growing literature which shows that surgery resection is a safe and effective method that might improve overall survival in patients with accessible PCNSL and single lesions, and it could be optimized by the use of 5-ALA. The follow-up period after treatment was 1 year, so long-term results are needed in future to confirm these good outcomes. In this context, there is a need for prospective studies to investigate the safety and therapeutic benefit of cytoreductive surgery for PCNSL.

Declaration of patient consent

Patient's consent not required as patients identity is not disclosed or compromised.

Financial support and sponsorship

No.

Conflicts of interest

There are no conflicts of interest.

REFERENCES

1. Bataille B, Delwail V, Menet E, Vandermarcq P, Ingrand P, Wager M, *et al.* Primary intracerebral malignant lymphoma:

- Report of 248 Cases. *J Neurosurg* 2000;92:261-6.
2. Bellinzona M, Roser F, Ostertag H, Gaab RM, Saini M. Surgical removal of primary central nervous system lymphomas (PCNSL) presenting as space occupying lesions: A series of 33 cases. *Eur J Surg Oncol* 2005;31:100-5.
3. Caroli E, Acqui M, Ferrante L. Primary cerebral lymphoma: A retrospective study in 22 immunocompetent patients. *Tumori* 2004;90:294-8.
4. Evers G, Kamp M, Warneke N, Berdel W, Sabel M, Stummer W, *et al.* 5-aminolevulinic acid-induced fluorescence in primary central nervous system lymphoma. *World Neurosurg* 2017;98:375-80.
5. Haldorsen IS, Espeland A, Larsson EM. Central nervous system lymphoma: Characteristic findings on traditional and advanced imaging. *AJNR Am J Neuroradiol* 2011;32:984-92.
6. Jelacic J, Todorovic Balint M, Raicevic S, Ilic R, Stanisavljevic D, Bila J, *et al.* The possible benefit from total tumour resection in primary diffuse large B-cell lymphoma of central nervous system-a one-decade single-centre experience. *Br J Neurosurg* 2016;30:80-5.
7. Lukas RV, Stupp R, Gondi V, Raizer JJ. Primary central nervous system lymphoma-PART 1: Epidemiology, diagnosis, staging, and prognosis. *Oncology (Williston Park)* 2018;32:17-22.
8. Lukas RV, Stupp R, Gondi V, Raizer JJ. Primary central nervous system lymphoma-PART 2: Modern therapeutic management and future directions. *Oncology (Williston Park)* 2018;32:e11-9.
9. Mangla R, Kolar B, Zhu T, Zhong J, Almast J, Ekholm S. Percentage signal recovery derived from MR dynamic susceptibility contrast imaging is useful to differentiate common enhancing malignant lesions of the brain. *AJNR Am J Neuroradiol* 2011;32:1004-10.
10. Ostrom QT, Gittleman H, Xu J, Kromer C, Wolinsky Y, Kruchko C, *et al.* CBTRUS statistical report: Primary brain and other central nervous system tumors diagnosed in the United States in 2009-2013. *Neuro Oncol* 2016;18:v1-75.
11. Shiels MS, Pfeiffer RM, Besson C, Clarke CA, Morton LM, Nogueira L, *et al.* Trends in primary central nervous system lymphoma incidence and survival in the U.S. *Br J Haematol* 2016;174:417-24.
12. Weller M, Martus P, Roth P, Thiel E, Korfel A, German PCNSL Study Group. Surgery for primary CNS lymphoma? Challenging a paradigm. *Neuro Oncol* 2012;14:1481-4.
13. Yamamoto T, Ishikawa E, Miki S, Sakamoto N, Zaboronok A, Matsuda M, *et al.* Photodynamic diagnosis using 5-aminolevulinic acid in 41 biopsies for primary central nervous system lymphoma. *Photochem Photobiol* 2015;91:1452-7.
14. Yun J, Iwamoto FM, Sonabend AM. Primary central nervous system lymphoma: A critical review of the role of surgery for resection. *Arch Cancer Res* 2016;4:71.

How to cite this article: Ferrer P, Barbero P, Monedero G, Lo Presti A, Bejarano B, Penanes JR. Primary central nervous system lymphoma and 5-aminolevulinic acid. *Surg Neurol Int* 2020;11:122.