

## Pediatric Cerebellar Pilomyxoid Astrocytoma: Clinical and Radiological Findings in Three Cases

### Abstract

Pilomyxoid astrocytomas (PMA) is a particular form of glial tumors distinct from pilocytic astrocytomas (PA). On the last 2016 WHO classification for CNS tumours, no definite grade assignment was proposed for these lesions. They may be more aggressive with a different clinical course compared to PA due to their greater propensity for local recurrence and cerebrospinal dissemination. Most cases arise from the hypothalamic region. Only few studies reported cerebellar localization of the lesion. We report 3 pediatric cases treated for pediatric PMA of the posterior fossa. Clinical, radiological, and prognostic features were reviewed. The age of our patients was between 1 and 9 years old. Signs of intracranial hypertension were found in all patients. One of them presented an increased head circumference and the 2 others had a cerebellar syndrome. Brain CT-scan and MRI displayed a large well-circumscribed intra-axial solid and cystic posterior fossa tumor. Total surgical resection was performed for all tumors. After a 2 years follow up, no signs of recurrence were noticed. In the literature, PMA been reported with overwhelming majority in children aged between 2 months and 4 years. Despite of many pathological similarities with PAs, PMAs have some specific features in histology, leading to their identification as independent type of glioma. Radiological differential diagnosis between PMAs and PAs can be made using arterial spin labeling imaging, which shows low perfusion parameters in PAs. Clinical and radiological follow up are mandatory do to different natural history and higher rates of local recurrence of this tumor compared to PA. Prognosis is favorable when complete surgical exeresis is possible.

**Keywords:** Astrocytoma, neurosurgery, pediatrics

**Ghassen Gader,  
Ghassen Belkahla,  
Nadhir Karmani<sup>1</sup>,  
Khalil Saadaoui<sup>2</sup>,  
Mouna Rkhami,  
Jalel Kallel<sup>1</sup>,  
Ihsèn Zammel,  
Mohamed Badri**

*Department of Neurosurgery,  
Trauma and Burns Center,  
Ben Arous, <sup>1</sup>Department of  
Neurosurgery, National  
Institute of Neurology, Tunis,*

*<sup>2</sup>Department of Neurosurgery,  
Universitary Hospital of  
Sahloul, Sousse, Tunisia*

### Introduction

Pilomyxoid astrocytoma (PMA) is a very rare tumor that merits recognition as a unique and specific entity. PMA shares the same features as pilocytic astrocytoma (PA), the most common central nervous system (CNS) tumor in the pediatric population. However, some pathological differences have been described to make part between these two entities. Previous studies have shown PMA to behave more aggressively than PA, with shorter overall survival as well as a higher rate of recurrence and dissemination.<sup>[1,2]</sup> PMA is considered as a pediatric tumor, mainly involving hypothalamic and chiasmatic regions.<sup>[3,4]</sup> Only few studies reported the cerebellum as a localization of this lesion.<sup>[5,6]</sup> This review summarizes the clinical, radiographic, prognosis, and current therapeutic options of cerebellar PMA through three pediatric cases.

This is an open access journal, and articles are distributed under the terms of the Creative Commons Attribution-NonCommercial-ShareAlike 4.0 License, which allows others to remix, tweak, and build upon the work non-commercially, as long as appropriate credit is given and the new creations are licensed under the identical terms.

For reprints contact: [reprints@medknow.com](mailto:reprints@medknow.com)

### Cases Reports [Table 1]

#### Case 1

A 1-year-old boy with normal background history presented with signs of intracranial hypertension with increased head circumference.

Brain magnetic resonance imaging (MRI) shows a large 51 mm diameter well-circumscribed intra-axial heterogeneous tumor in the left cerebellar lobe. The tumor was hyperintense on T2-weighted images (WIs) and hypointense T1-WI with peripheral contrast enhancement [Figure 1]. A hydrocephalus was also present due to the obstruction of the 4<sup>th</sup> ventricle.

The patient underwent a total resection of the tumor via left suboccipital craniotomy. The tumor was pale pink and the cyst contained yellowish turbid fluid.

**How to cite this article:** Gader G, Belkahla G, Karmani N, Saadaoui K, Rkhami M, Kallel J, *et al.* Pediatric cerebellar pilomyxoid astrocytoma: Clinical and radiological findings in three cases. *Asian J Neurosurg* 2020;15:262-5.

**Submitted:** 01-Sep-2019 **Accepted:** 19-Jan-2020  
**Published:** 07-Apr-2020

#### Address for correspondence:

*Dr. Ghassen Gader,  
Department of Neurosurgery,  
Trauma and Burns Center,  
Ben Arous, Tunisia.  
E-mail: [gastghagad@yahoo.fr](mailto:gastghagad@yahoo.fr)*

#### Access this article online

**Website:** [www.asianjns.org](http://www.asianjns.org)

**DOI:** 10.4103/ajns.AJNS\_268\_19

#### Quick Response Code:



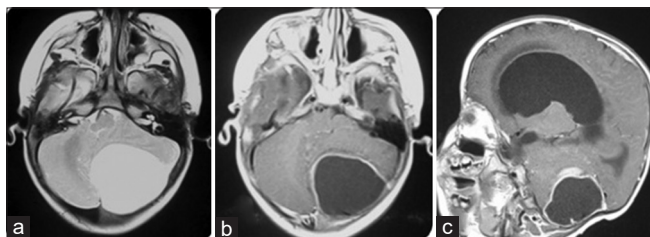
Postoperative course was uneventful. The patient showed clinical improvement, as well as regression of hydrocephalus on control brain computed tomography scan.

Histological examination revealed monomorphous bipolar cells with loose myxoid background. No biphasic pattern, Rosenthal fibers, or eosinophilic granular bodies were noticed. The tumor cells were arranged around vessels in a pattern resembling pseudorosettes seen in ependymomas, with no evidence of neovascularization, significant pleomorphism, abnormal mitoses, or necrosis [Figure 2].

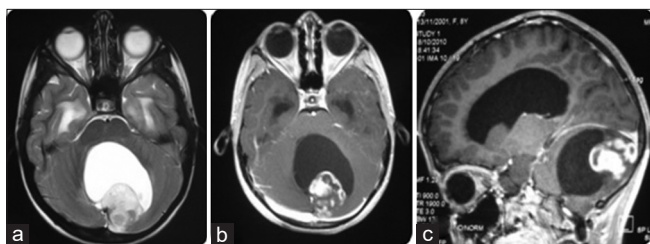
A 2-year follow-up showed no signs of recurrence. No adjuvant treatment was proposed.

### Case 2

A 7-year-old boy, with no pathologic background, presented with signs of intracranial hypertension (headache and vomiting) for 1 year with aggravation in the last 2 weeks. Clinical examination found a fully conscious patient with wide-based ataxic gait. Neither papillary edema nor cutaneous stigmata of neurofibromatosis had been found. Brain MRI showed a large 60 mm diameter well-circumscribed intra-axial solid and cystic tumor located in the vermis and left cerebellar lobe. The tumor was hyperintense in T2-WI and hypointense in T1-WI with contrast enhancement [Figure 3]. Surgical procedure was the same as the first case with total resection confirmed with postoperative brain scan [Figure 4]. Histological features were the same as for the first patient.



**Figure 1:** Brain MRI: (a) axial section on a T2-weighted image; (b) axial section on a T1-weighted image with contrast product injection; (c) sagittal section on a T1-weighted image with contrast product injection. They show a large 51 mm diameter well-circumscribed intra-axial heterogeneous tumor in the left cerebellar lobe. The tumor is hyperintense on T2-weighted image and hypointense T1-weighted image with peripheral contrast enhancement. A hydrocephalus is associated due to the obstruction of the 4<sup>th</sup> ventricle



**Figure 3:** Brain MRI: (a) axial section on a T2-weighted image; (b) axial section on a T1-weighted image with contrast product injection; (c) sagittal section on a T1-weighted image with contrast product injection. They show a large 60 mm diameter well-circumscribed intra-axial solid and cystic tumor located in the vermis and left cerebellar lobe. The tumor was hyperintense in T2-weighted image and hypointense in T1-weighted image with contrast enhancement

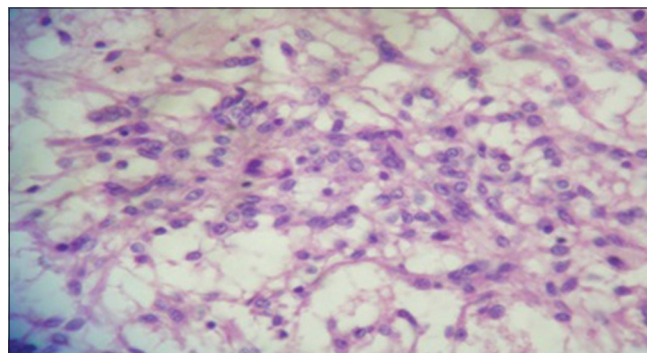
Two-year follow-up showed no signs of recurrence and no adjuvant treatment was needed.

### Case 3

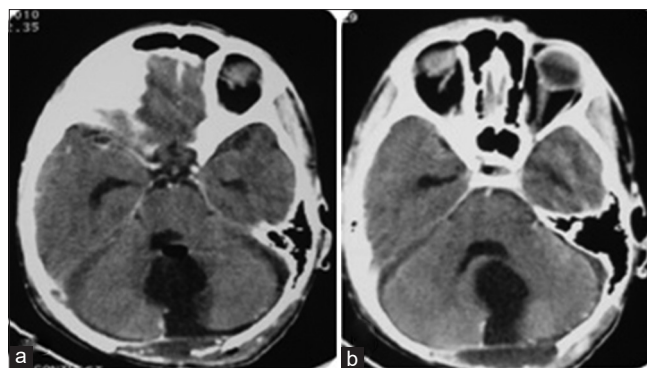
A 9-year-old girl with no abnormal background consulted with progressive gait disturbance and frequent falls for several days added to signs of high intracranial hypertension for 1 year. Wide-based ataxic gait was observed with no other signs in clinical examination. Brain MRI found a large 70 mm diameter well-circumscribed intra-axial solid and cystic tumor located in the vermis and left cerebellar lobe [Figure 5]. A total resection of the tumor via suboccipital craniotomy was performed. The histological features of the tumor were the same as the two previous cases. Two-year follow-up showed no signs of recurrence and no adjuvant treatment was performed.

### Discussion

PMA has been defined as a distinct entity among brain tumors, but on the last 2016 World Health Organization (WHO) classification for CNS tumors, no definite grade assignment was proposed for these lesions.<sup>[1,2]</sup> PMAs have been reported with overwhelming

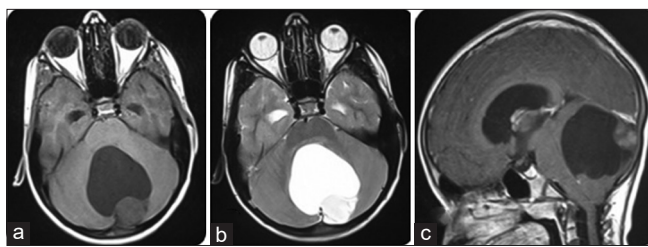


**Figure 2:** Histological examination of the tumor revealing monomorphous bipolar cells with loose myxoid background. No biphasic pattern, Rosenthal fibers, or eosinophilic granular bodies were noticed. The tumor cells were arranged around vessels in a pattern resembling pseudo rosettes seen in ependymomas, with no evidence of neovascularization, significant pleomorphism, abnormal mitoses, or necrosis



**Figure 4:** Axial sections of a postoperative brain CT scan (a) without injection of contrast product; (b) with injection of contrast product. They show a complete exeresis of the tumor

majority in children aged between 2 months and 4 years.<sup>[7]</sup> These tumors are known to be mostly located in the chiasmatic-hypothalamic region, but many other locations were reported, including the spinal cord,



**Figure 5:** Brain MRI: (a) axial section on a T1-weighted image with contrast product injection; (b) axial section on a T2-weighted image; (c) sagittal section on a T1-weighted image with contrast product injection. They show a large 60 mm diameter well-circumscribed intra-axial solid and cystic tumor located in the vermis and left cerebellar lobe. The tumor was hyperintense in T2-weighted image and hypointense in T1-weighted image with discrete peripheral contrast enhancement

temporal lobe, occipital lobe, and sellar-suprasellar region.<sup>[8-10]</sup> In the adulthood, PMAs may be located in different regions from those of the childhood, such as the deep temporal area,<sup>[11]</sup> spinal cord,<sup>[12]</sup> and fourth ventricle.<sup>[13]</sup>

In our pediatric series, the posterior fossa localization was found in all three patients. In the literature, only few studies reported the cerebellum as a possible localization for PMAs.<sup>[5,6]</sup> Despite many pathological similarities with PAs, PMAs have some specific features in histology, leading to their identification as independent type of glioma. These characteristics include monomorphous growth of piloid cells, with an angiocentric pattern, rich in myxoid background, and lacking of Rosenthal fibers or eosinophilic granular bodies.<sup>[14]</sup> Furthermore, necrosis is more commonly associated with PMA, whereas cystic formations, calcifications and perilesional oedema are more common in classic PAs.<sup>[14]</sup> Immunohistochemical

**Table 1: Summary of the features concerning the patients reported in this article**

Case n	Age	Gender	Pathologic background	Functional symptoms	Physical examination	MRI	Treatment	Postoperative course	Histological examination	Outcome
1	1	Male	None	Intracranial hypertension	Increased head circumference	Large well-circumscribed intra-axial heterogenous tumor in the left cerebellar lobe Hyperintense on T2 WI and hypointense on T1 WI with peripheral contrast enhancement Associated hydrocephalus due to the obstruction of the 4th ventricle	Total resection of the tumor via suboccipital craniotomy	Clinical improvement and regression of the hydrocephalus on control brain CT-scan	Monomorphous bipolar cells with loose myxoid background, The tumor cells were arranged around vessels in a pattern resembling pseudo rosettes	No signs of recurrence (2 years follow up) No adjuvant treatment was proposed
2	7	Male	None	Intracranial hypertension	Ataxic gait	Large well-circumscribed intra-axial solid and cystic tumor located in the vermis and left cerebellar lobe Hyperintense on T2 WI and hypointense on T1 WI with contrast enhancement				No signs of recurrence (2 years follow up) No adjuvant treatment
3	9	Female	None	Gait disturbance Frequent falls Intracranial hypertension	Ataxic gait	Large well-circumscribed intra-axial solid and cystic tumor located in the vermis and left cerebellar lobe Hyperintense on T2-WI and hypointense on T1-WI with contrast enhancement				No signs of recurrence (2 years follow up) No adjuvant treatment



studies proved that PMAs stains are strongly positive for glial fibrillary acidic protein and vimentin and are negative for neuronal markers.<sup>[14]</sup> PMAs and PAs share also some radiological similarity: they both show isointensity on T1-WI sequences, hyperintensity on T2-WI, and FLAIR sequences. However, PMAs are often solid, rarely with peripheral edema. 40% of PMAs show homogenous enhancement and 30%–60% display heterogeneous enhancement.<sup>[13,15]</sup> Radiological differential diagnosis between PMAs and PAs can be made using arterial spin labeling imaging, which shows low perfusion parameters in PAs.<sup>[16,17]</sup>

Yeom *et al.*<sup>[16]</sup> showed that the maximal relative tumor blood flow of high-grade tumors (Grades III and IV) was significantly higher than that of low-grade tumors (Grades I and II). In another report by Komotar *et al.*,<sup>[11]</sup> 76% of patients with PMAs exhibited local recurrence, versus 50% for those with PAs, with an increased rates of leptomeningeal dissemination (14%). Furthermore, PMAs have significantly decreased mean progression free time and overall survival.

All of our three patients underwent a total surgical resection. No adjuvant treatments were proposed. All of our patients showed a positive posttherapeutic evolution, having shown no signs of clinical or radiological recurrence. In the literature, there is still no consensus about the management of PMAs. Nevertheless, some reports showed that gross total resection was the primary treatment strategy and the most reliable predictor of outcome in children with low-grade gliomas where surgery can be performed without excessive morbidity.<sup>[18]</sup> Adjuvant chemo- or radiotherapy is restricted to cases with subtotal excision or recurrence.<sup>[5]</sup>

## Conclusions

PMAs are classified as low-grade tumor, but must be distinguished from PAs. The WHO classification defines PMA as a subgroup of PAs with more aggressive attributes. A close clinical and radiological follow-up is needed due to an increased risk of recurrences and dissemination. Gross total resection is the most important factor to predict the outcome of PMA.

## Declaration of patient consent

The authors certify that they have obtained all appropriate patient consent forms. In the form the patient(s) has/have given his/her/their consent for his/her/their images and other clinical information to be reported in the journal. The patients understand that their names and initials will not be published and due efforts will be made to conceal their identity, but anonymity cannot be guaranteed.

## Financial support and sponsorship

Nil.

## Conflicts of interest

There are no conflicts of interest.

## References

1. Jänisch W, Schreiber D, Martin H, Gerlach H. Diencephalic pilocytic astrocytoma with clinical onset in infancy. Biological behavior and pathomorphological findings in 11 children. *Zentralbl Allg Pathol* 1985;130:31-43.
2. Tihan T, Burger PC. A variant of pilocytic astrocytoma: A possible distinct clinicopathological entity with a less favorable outcome. *J Neuropathol Exp Neurol* 1998;57:500.
3. Louis DN, Ohgaki H, Wiestler OD, Cavenee WK, Burger PC, Jouvet A, *et al.* The 2007 WHO classification of tumours of the central nervous system. *Acta Neuropathol* 2007;114:97-109.
4. Komotar RJ, Burger PC, Carson BS, Brem H, Olivi A, Goldthwaite PT, *et al.* Pilocytic and pilomyxoid hypothalamic/chiasmatic astrocytomas. *Neurosurgery* 2004;54:72-9.
5. Ge PF, Wang HF, Qu LM, Chen B, Fu S, Luo Y. Pilomyxoid astrocytoma in cerebellum. *Chin J Cancer Res* 2011;23:242-4.
6. Forbes JA, Mobley BC, O'Lynn TM, Cooper CM, Ghiassi M, Hanif R, *et al.* Pediatric cerebellar pilomyxoid-spectrum astrocytomas. *J Neurosurg Pediatr* 2011;8:90-6.
7. Morales H, Kwock L, Castillo M. Magnetic resonance imaging and spectroscopy of pilomyxoid astrocytomas: Case reports and comparison with pilocytic astrocytomas. *J Comput Assist Tomogr* 2007;31:682-7.
8. Linscott LL, Osborn AG, Blaser S, Castillo M, Hewlett RH, Wieselthaler N, *et al.* Pilomyxoid astrocytoma: Expanding the imaging spectrum. *AJNR Am J Neuroradiol* 2008;29:1861-6.
9. Buccoliero AM, Gheri CF, Maio V, Moncini D, Castiglione F, Garbini F, *et al.* Occipital pilomyxoid astrocytoma in a 14-year-old girl-case report. *Clin Neuropathol* 2008;27:373-7.
10. Alimohamadi M, Bidabadi MS, Ayan Z, Ketabchi E, Amirjamshidi A. Pilomyxoid astrocytoma with involvement of the sella turcica in an adolescent. *J Clin Neurosci* 2009;16:1648-9.
11. Komotar RJ, Mocco J, Zacharia BE, Wilson DA, Kim PY, Canoll PD, *et al.* Astrocytoma with pilomyxoid features presenting in an adult. *Neuropathology* 2006;26:89-93.
12. Sajadi A, Janzer RC, Lu TL, Duff JM. Pilomyxoid astrocytoma of the spinal cord in an adult. *Acta Neurochir (Wien)* 2008;150:729-31.
13. Komakula ST, Fenton LZ, Kleinschmidt-DeMasters BK, Foreman NK. Pilomyxoid astrocytoma: Neuroimaging with clinicopathologic correlates in 4 cases followed over time. *J Pediatr Hematol Oncol* 2007;29:465-70.
14. Koeller KK, Rushing EJ. From the archives of the AFIP: Pilocytic astrocytoma: Radiologic-pathologic correlation. *Radiographics* 2004;24:1693-708.
15. Arslanoglu A, Cirak B, Horska A, Okoh J, Tihan T, Aronson L, *et al.* MR imaging characteristics of pilomyxoid astrocytomas. *AJNR Am J Neuroradiol* 2003;24:1906-8.
16. Yeom KW, Mitchell LA, Lober RM, Barnes PD, Vogel H, Fisher PG, *et al.* Arterial spin-labeled perfusion of pediatric brain tumors. *AJNR Am J Neuroradiol* 2014;35:395-401.
17. Bing F, Kremer S, Lamalle L, Chabardes S, Ashraf A, Pasquier B, *et al.* Value of perfusion MRI in the study of pilocytic astrocytoma and hemangioblastoma: Preliminary findings. *J Neuroradiol* 2009;36:82-7.
18. Skovrlj B, Pain M, Bederson JB, Fowkes M. Pilomyxoid astrocytoma of the cerebellar vermis in an elderly patient. *Surg Neurol Int* 2014;5:29.