

# Efficacy of apatinib combined with temozolomide in the treatment of recurrent high-grade glioma: A meta-analysis

GUANGLIE LI, XIWEI XU, JIANQI CUI, FAN ZHANG and SIYANG WANG

Department of Head and Neck Oncology, The Fifth Affiliated Hospital of Sun Yat-sen University, Zhuhai, Guangdong 519000, P.R. China

Received September 9, 2022; Accepted July 7, 2023

DOI: 10.3892/etm.2023.12151

**Abstract.** Recurrent high-grade glioma is a refractory disease, and its prognosis is poor. Although the treatment of apatinib combined with temozolomide provides improved efficacy and is able to prolong survival, this conclusion has been based on small samples. In order to clarify this treatment's efficacy, a meta-analysis was performed in the present study. Different databases were screened and finally, 10 studies were included, comprising 357 patients with recurrent high-grade gliomas. The efficacy and prognosis were analyzed using Stata software. The results indicated that the overall objective response rate (ORR) and disease control rate (DCR) of apatinib combined with temozolomide were 0.36 (95% CI, 0.26-0.46) and 0.86 (95% CI, 0.82-0.89), respectively. Subgroup analysis indicated that the overall ORR was 0.43 (95% CI, 0.29-0.57) and 0.26 (95% CI, 0.14-0.38), and the DCR was 0.89 (95% CI, 0.85-0.93) and 0.76 (95% CI, 0.69-0.84) in the treatment of apatinib with temozolomide dose-dense group and the conventional-dose group (5/28 regimen), respectively. Further prognostic analysis indicated that the median overall survival of patients with high-grade glioma treated with apatinib combined with temozolomide was 8.21 months (95% CI, 7.20-9.22 months) and the median progression-free survival was 5.45 months (95% CI, 4.53-6.37). Analysis of the publication bias of the effect size revealed that there was bias in the DCR, while no bias was found in the remaining effect size (ORR, median overall survival and median progression-free survival). After correction by the trim-and-fill method, bias was indicated to have no significant impact on the results. In conclusion, apatinib combined with temozolomide has the effect that, compared with traditional Bevacizumab treatment, it can improve the efficacy in the treatment of recurrent high-grade glioma and

improve prognosis. When combining with dose-dense temozolomide, the effect may be better than that of the conventional 5/28 regimen.

## Introduction

Gliomas are the most common primary intracranial tumors in adults. Among them, high-grade gliomas include anaplastic gliomas and glioblastomas; they are characterized by rapid progression, high malignancy, a 5-year survival rate of <10% and a poor prognosis (1), thus seriously threatening the life of affected patients. Currently, the standard treatment is to perform surgical resection to the maximum extent to preserve nerve function. After the operation, temozolomide chemoradiotherapy and adjuvant chemotherapy (Stupp regimen) are used. However, the median overall survival (mOS) time for glioblastoma is only 14.6 months, the 2-year survival rate is only 26.5%, the median progression-free survival (mPFS) time is only 6.9 months and ~85% of patients have disease progression within 2 years (2). At present, there is no single standard treatment plan for recurrent high-grade glioma. The commonly used treatment methods include reoperation, recourse radiotherapy, temozolomide chemotherapy, bevacizumab anti-vascular treatment, carmustine and irinotecan (3). Although new treatment models have emerged on this basis, such as tumor electric field therapy (4) and oncolytic virus therapy (5), the efficacy is still not ideal. Therefore, it is of clinical significance to continue to search for more novel treatment models not only to improve the therapeutic efficacy of patients with recurrent high-grade glioma but also to improve patient prognosis.

Previous studies have indicated that the growth and recurrence of high-grade glioma are closely related to tumor angiogenesis (6,7). As a monoclonal antibody against vascular endothelial cytokines, bevacizumab has been approved in China and abroad to treat recurrent high-grade glioma, but it has serious adverse effects, such as hypertension and bleeding (8). As bevacizumab is expensive and needs to be administered by intravenous infusion once every two weeks, numerous patients have poor compliance or miss the treatment timepoint. Various patients cannot afford the cost for economic reasons and the treatment efficacy is not guaranteed.

Apatinib is a new oral small-molecule inhibitor of vascular endothelial growth factor receptor-2 (VEGFR-2), which is

---

*Correspondence to:* Dr Siyang Wang, Department of Head and Neck Oncology, The Fifth Affiliated Hospital of Sun Yat-sen University, 52 Meihua East Road, Xiangzhou, Zhuhai, Guangdong 519000, P.R. China  
E-mail: 13570608929@163.com

**Key words:** apatinib, temozolomide, recurrent, high-grade glioma, efficacy

convenient, economical and efficient. It selectively competes for the ATP binding site of VEGFR-2 in cells, blocks the downstream signal transduction and inhibits angiogenesis in tumor tissues, thereby exerting its anti-tumor effect (9). Apatinib is the first small-molecule anti-angiogenic targeted drug worldwide proven to be safe and effective and has achieved gratifying results in treating advanced gastric cancer (10). The clinical application of apatinib in other tumors and the relevant mechanisms have also been widely explored. An increasing number of studies indicate that apatinib has a significant anti-tumor effect in various tumor types (11-13). Apatinib has also been demonstrated to enhance the inhibitory effect of temozolomide on the proliferation and invasion of glioma cells, suggesting that apatinib and temozolomide have synergistic anti-tumor effects in glioma (10). In recent years, accumulating data have revealed that combining apatinib and temozolomide may significantly improve the treatment efficacy of recurrent high-grade glioma, but the conclusions are all based on small samples (14-16). The present meta-analysis aimed to analyze all of the relevant studies in a combined manner, clarify the efficacy of apatinib plus temozolomide in patients with recurrent high-grade glioma and provide evidence for its utility in future clinical treatment.

## Materials and methods

**Data sources.** The literature related to the topic of the present study was searched without any limitations regarding the language, and the search date was limited up to May 2023. The PubMed (<https://pubmed.ncbi.nlm.nih.gov>), Web of Science (<https://webofknowledge.com>), Cochrane Library (<https://www.cochranelibrary.com>), Chinese National Knowledge Infrastructure (<https://www.cnki.net>) and Wanfang (<https://www.wanfangdata.com.cn>) databases were searched, also including a search for ahead of print articles. The search terms were as follows: 'Apatinib', 'temozolomide', 'TMZ', 'temodal', 'temodar', 'relapse', 'recurrent', 'recrudescent', 'glioblastoma' and 'glioma'. The search strategy is detailed in Appendix S1, and abstracts without full-text were not included in the present meta-analysis. The contents of domestic Chinese Food and Drug Administration-approved documents were also reviewed and the identified literature was screened to determine whether there were any further related publications. In addition, the safety data of the manufacturer's (Jiangsu Hengrui Medicine Co., Ltd.) updated instructions for apatinib were reviewed to obtain relevant information and these were considered to be the latest data that were analyzed. When the relevant data required to be clarified, the authors of the studies and the manufacturer of apatinib were contacted.

**Inclusion and exclusion criteria.** All included studies were required to meet the following inclusion criteria: i) All patients in the study had undergone surgical resection or brain biopsy and were confirmed to be World Health Organization grade III or IV. After the operation, they received the standard Stupp regimen chemotherapy and radiotherapy (2), and the subsequent maintenance chemotherapy failed. Pathology or MRI examination confirmed that they were relapsed, and there were clear, measurable lesions on MRI. ii) All patients in the study were treated with apatinib combined with temozolomide




Figure 1. Flow chart of the study selection. CNKI, Chinese National Knowledge Infrastructure.

[conventional 5/28 regimen (2) or dense regimen (17)] after the recurrence was confirmed. iii) The diagnosis, treatment plan, response criteria, overall objective response rate (ORR) and disease control rate (DCR) of recurrent high-grade glioma were reported in the study. iv) The general clinical characteristics of patients, such as age and Karnowski performance status score, were clearly described in the study. v) The type of study was that of a randomized or nonrandomized controlled trial.

The exclusion criteria were as follows: i) Patients did not receive standard chemoradiotherapy after the operation; ii) only apatinib monotherapy or temozolomide monotherapy was administered; iii) the study's treatment results were not clearly described; and iv) the studies involved case reports, reviews and other meta-analyses.

**Data extraction.** According to the PRISMA guidelines (18), two researchers (GL and XX) extracted relevant data from the articles' text, tables and figures and cross-checked them. In the case of any disagreement, a third author (SW) was consulted to discuss and solve the issue. The specific contents extracted from the literature included the following: i) The basic information of the included study, including the title, first author name and publication year; ii) baseline characteristics of the subjects, including sample size and age; iii) specific details of treatment measures, including treatment plan and drug dosage; and iv) outcome measures, such as ORR, DCR, mOS and mPFS.

**Meta-analysis.** The results were analyzed using Stata 17.0 statistical software (StataCorp LP). The forest plot was drawn at first using the random-effects model, combining the effects of each study to evaluate the overall efficacy and prognosis associated with apatinib combined with temozolomide for recurrent high-grade glioma. For the consistency evaluation of the study, the traditional statistical test (Cochran's Q-test) was first used for evaluation, and the  $I^2$  test was then used for verification. If the  $I^2$ -value was  $\leq 50\%$ , the fixed-effects model was used to integrate all effect sizes. If the  $I^2$ -value was  $> 50\%$ , the random-effects model was used to integrate all effect sizes and indicate substantial heterogeneity. Subsequently, further funnel plot and sensitivity analyses were performed to identify the source of heterogeneity, and subgroup analysis was conducted as necessary to identify sources of heterogeneity (19). For the

Table I. Baseline characteristics of all included studies.

First author, year	Study type	Temozolomide dosing	Sample size	Mean $\pm$ SD or median age (range), years	Intervention	CR, n	PR, n	SD, n	PD, n	ORR, %	DCR, %	Median OS (95% CI), months	Median PFS (95% CI), months	(Refs.)
Wang <i>et al</i> , 2019	Single-arm	Dose-dense	20	50.5 (27.0-67.0)	Apatinib (500 mg/day) + temozolomide (100 mg/m <sup>2</sup> , take for 1 week, stop for 1 week)	1	8	9	2	9/20 (45.0)	18/20 (90)	9 (8.2-12.2)	6 (5.3-7.8)	(14)
Zhou <i>et al</i> , 2020	Randomized- controlled	Dose-dense	12	48.0 $\pm$ 7.0	Apatinib (500 mg/day) + temozolomide (150 mg/m <sup>2</sup> , take for 1 week, stop for 1 week)	0	8	3	1	8/12 (66.7)	11/12 (91.7)	NA (8.2-12.2)	NA (5.3-7.8)	(15)
		Conventional- dose	14	50.0 $\pm$ 8.0	Apatinib (500 mg/day) + temozolomide (200 mg/m <sup>2</sup> , take for 5 days, stop for 23 days)	0	3	5	6	3/14 (21.4)	8/14 (51.7)	NA (8.2-12.2)	NA (5.3-7.8)	
Liu <i>et al</i> , 2020	Randomized- controlled	Dose-dense	15	40.3 (21.0-71.0)	Apatinib (500 mg/day) + temozolomide (150 mg/m <sup>2</sup> , take for 1 week, stop for 1 week)	1	7	5	2	8/15 (53.4)	13/15 (86.7)	NA (8.2-12.2)	NA (5.3-7.8)	(21)
Ge <i>et al</i> , 2021	Single-arm	Dose-dense	31	53.0 (21.0-70.0)	Apatinib (500 mg/day) + temozolomide (50 mg/m <sup>2</sup> , take every day)	3	5	17	6	8/31 (25.8)	25/31 (80.6)	8.2 (6.9-9.5)	4.9 (2.8-7.0)	(16)
Yao <i>et al</i> , 2021	Single-arm	Dose-dense	18	NA (18.0-65.0)	Apatinib (500 mg/day) + temozolomide (50 mg/m <sup>2</sup> , take every day)	0	4	10	3	4/17 (23.5)	14/17 (82.3)	9.1 (7.6-10.6)	4 (3.2-4.8)	(22)

Table I. Continued.

First author, year	Study type	Temozolomide dosing	Sample size	Mean $\pm$ SD or median age (range), years	Intervention	CR, n	PR, n	SD, n	PD, n	ORR, %	DCR, %	Median OS (95% CI), months	Median PFS (95% CI), months	(Refs.)
Gao <i>et al</i> , 2021	Randomized- controlled	Conventional- dose	26	NA	Apatinib (500 mg/day) + temozolomide (150 mg/m <sup>2</sup> , take for 5 days, stop for 23 days)	1	17	6	2	10/26 (38.5)	22/26 (84.6)	8.7 (8.2-9.3)	7.6 (5.7-9.4)	(23)
Li <i>et al</i> , 2021	Single-arm	Conventional- dose	51	53.0 (31.0-70.0)	Apatinib (500 mg/day) + temozolomide (150 mg/m <sup>2</sup> , take for 5 days, stop for 23 days)	2	15	20	14	17/51 (33.3)	37/51 (72.5)	NA	5.9 (5.4-6.5)	(24)
Xu <i>et al</i> , 2022	Single-arm	Dose-dense	79	46.1 $\pm$ 15.2 (15.0-70.0)	Apatinib (500 mg/day) + temozolomide (100 mg/m <sup>2</sup> , take for 1 week, stop for 1 week)	0	23	46	10	23/79 (29.1)	66/79 (83.5)	6.4 (5.3-7.5)	4.9 (3.9-5.9)	(25)
Zhang <i>et al</i> , 2022	Randomized- controlled	Conventional- dose	37	NA	Apatinib (500 mg/day) + temozolomide (200 mg/m <sup>2</sup> , take for 5 days, stop for 23 days)	0	5	24	8	5/37 (13.5)	29/37 (78.4)	NA	NA	(26)
Quan <i>et al</i> , 2022	Randomized- controlled	Dose-dense	54	62.5 $\pm$ 4.2 (52.0-74.0)	Apatinib (500 mg/day) + temozolomide (100 mg/m <sup>2</sup> , take for 3 weeks, stop for 1 week)	0	34	17	3	34/54 (63.0)	51/54 (94.4)	17	NA	(27)

NA, not available; CR, complete response; PR, partial response; SD, stable disease; PD, progressive disease; ORR, objective response rate; DCR, disease control rate; OS, overall survival; PFS, progression-free survival.

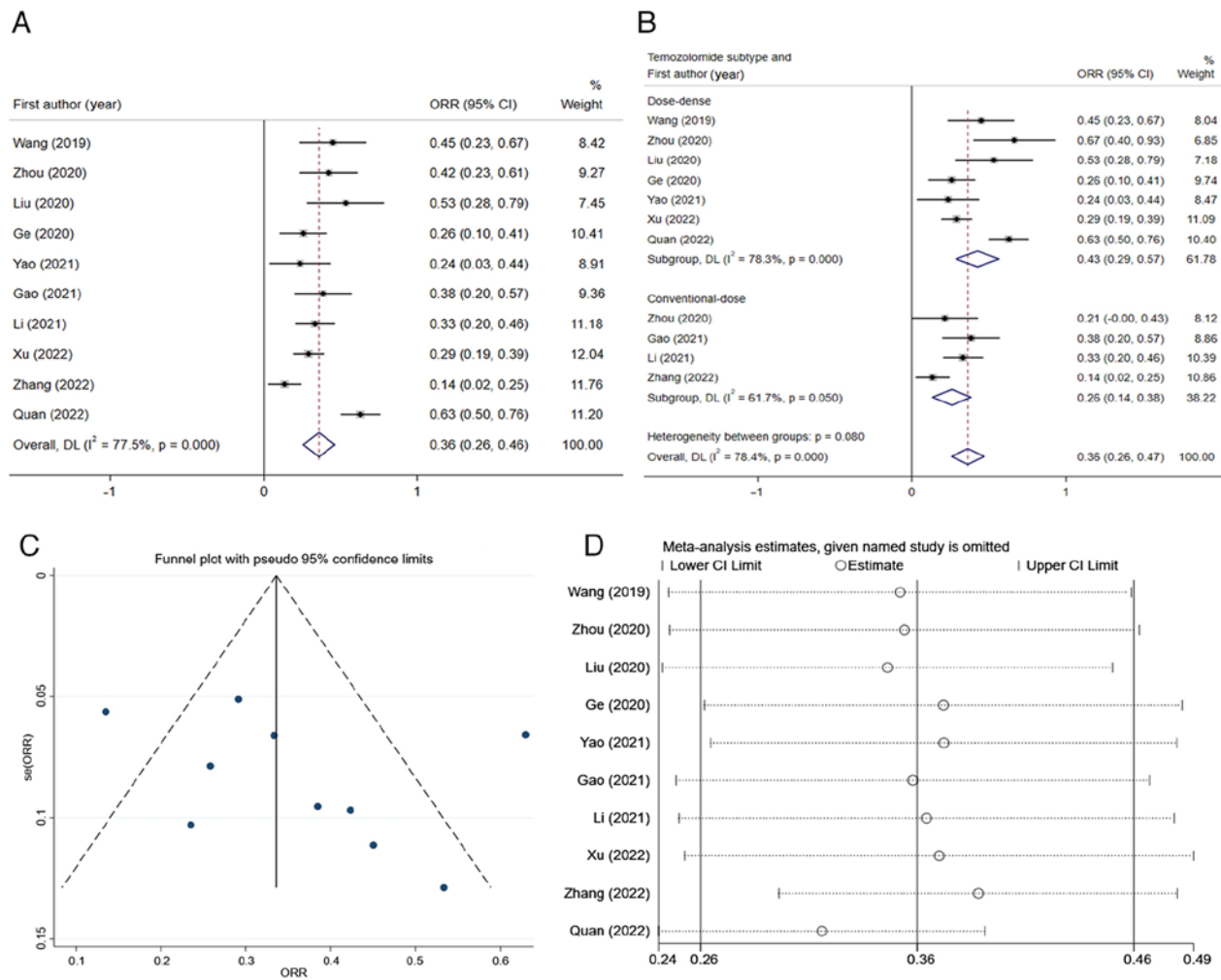


Figure 2. Overall ORR of apatinib combined with temozolomide in the treatment of recurrent high-grade glioma. (A) After integrating the ORRs of all studies using the random-effects model, the total ORR was 0.36 (95% CI, 0.26-0.46). (B) The subgroup analysis results suggested that the total ORR of apatinib combined with dose-dense temozolomide was 0.43 (95% CI, 0.29-0.57) and the total ORR for the conventional-dose group was 0.26 (95% CI, 0.14-0.38). (C) Funnel plots of ORR for each study. (D) Sensitivity analysis of ORR for each study. ORR, objective response rate; se, standard error; DL, random-effects model.

evaluation of publication bias, Begg's test and Egger's test were used (20).  $P < 0.05$  was considered to indicate a statistically significant difference.

## Results

**Literature screening.** Initially, 44 entries were retrieved from all databases. After removing duplicate entries and abstracts, 15 studies were selected. After removing any studies that did not meet the subject and inclusion criteria, 10 studies were finally included in the comprehensive analysis (14-16,21-27). The specific screening process is illustrated in Fig. 1. A total of 357 patients with recurrent high-grade glioma were included in the present meta-analysis. The name of the first author, publication year, sample size, median age, specific interventions and outcome indicators are listed in Table I.

### Meta-analysis results

**Overall ORR in the treatment of recurrent high-grade glioma with apatinib combined with temozolomide.** A comprehensive analysis of the results of the 10 studies included was performed.

The heterogeneity test was performed, and it was found that the  $I^2$ -value was 77.5%, thereby being  $>50\%$ . Accordingly, the random-effects model was used for the meta-analysis. The results indicated that the overall ORR of patients with recurrent high-grade glioma who received apatinib and temozolomide was 0.36 (95% CI, 0.26-0.46) (Fig. 2A). Furthermore, a sensitivity analysis was performed and a funnel plot was generated to identify the sources of heterogeneity (Fig. 2C and D). Among all studies, there were two studies with significant deviation (26,27), and after excluding these two studies, the  $I^2$ -value was reduced to 2.3% (Fig. 2B). The 10 studies were then stratified according to different dosage schemes of temozolomide. The subgroup analysis indicated that the overall ORR of the dose-dense temozolomide group was 0.43 (95% CI, 0.29-0.57), while that of the conventional-dose temozolomide was 0.26 (95% CI, 0.14-0.38) (Fig. 2B). There was a significant difference ( $P < 0.05$ ) between subgroups.

**Overall DCR in the treatment of recurrent high-grade glioma with apatinib combined with temozolomide.** Next, the combined DCR of the 10 studies was calculated and the result indicated that the total DCR value after integration was

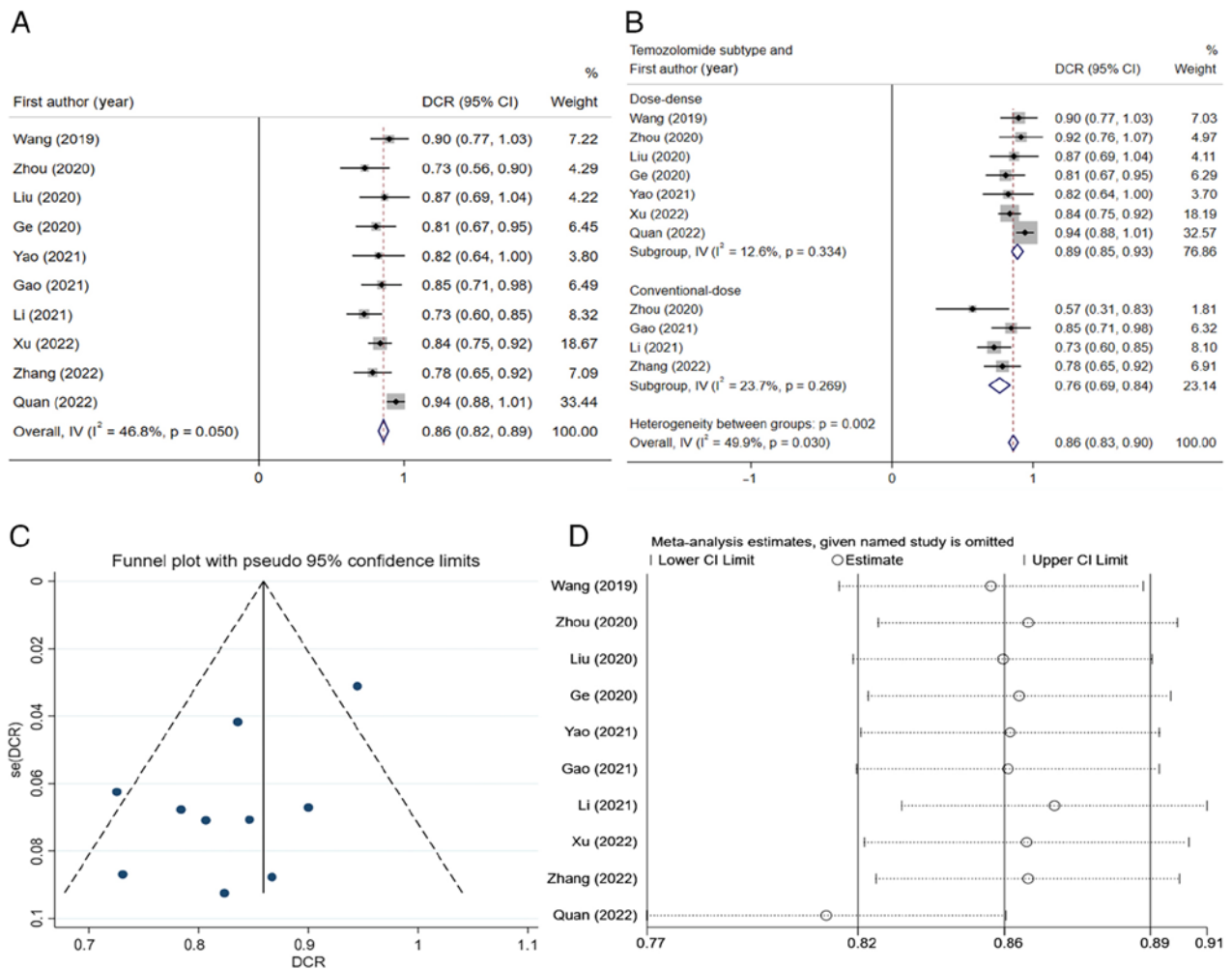


Figure 3. DCR of apatinib combined with temozolomide in the treatment of recurrent high-grade glioma. (A) After integrating the DCRs of all studies using the fixed-effects model, the total DCR was 0.86 (95% CI, 0.82-0.89). (B) The subgroup analysis results suggested that the total DCR of apatinib combined with dose-dense temozolomide group was 0.89 (95% CI, 0.85-0.93) and the total DCR of the conventional-dose group was 0.76 (95% CI, 0.69-0.84). (C) Funnel plots of the DCR for each study. (D) Sensitivity analysis of the DCR for each study. DCR, disease control rate; IV, inverse variance; se, standard error.

0.86 (95% CI, 0.82-0.89) (Fig. 3A). Since the  $I^2$ -value of this result was  $46.8\% \leq 50\%$ , the fixed-effects model was used for integration. As could be seen from Fig. 3A, Quan *et al* (27) held significant weight and had significant impacts on the pooled result, but the result was not very heterogeneous, and this study could be considered for inclusion in the analysis. The funnel plot and sensitivity analysis results are presented in Fig. 3C and D, respectively. The studies were again grouped according to the different dosage regimens of temozolomide, and it was indicated that the total DCR of the dose-dense group was 0.89 (95% CI, 0.85-0.93) and the total DCR of the conventional-dose group was 0.76 (95% CI, 0.69-0.84) (Fig. 3B). There was a significant difference ( $P < 0.05$ ) between subgroups.

**Prognostic analysis of apatinib combined with temozolomide in the treatment of recurrent high-grade glioma.** Prognostic analysis indicated that the total mOS of apatinib combined with temozolomide in treating recurrent high-grade glioma was 8.21 months (95% CI, 7.20-9.22) (Fig. 4A). Due to the significant heterogeneity of the results ( $I^2 = 73.4\%$ , thereby being  $> 50\%$ ), the random-effects model was used for analysis. Funnel plots (Fig. 4B) and sensitivity analysis (Fig. 4C)

suggested that the bias in the study by Xu *et al* (25) was significant. After excluding this study, the  $I^2$ -value could be reduced to 0% (data not shown). This indicated that the result of this study was the main source of heterogeneity. After integrating the mPFS of various studies, the total mPFS was determined to be 5.45 months (95% CI, 4.53-6.37) (Fig. 5A). Due to the significant heterogeneity of the results ( $I^2 = 77.7\%$  thereby being  $> 50\%$ ), a funnel plot was drawn (Fig. 5B) and a sensitivity analysis was performed (Fig. 5C), indicating significant deviations in the results of two studies (22,23). After excluding these two studies and conducting further analysis, it was found that the  $I^2$ -value could be decreased to 19.6% (data not shown), indicating that these two studies may be major sources of heterogeneity.

**Publication bias.** The analysis indicated that there was no significant publication bias of the overall ORR in the treatment of recurrent high-grade gliomas with apatinib and temozolomide using either the Begg's test ( $P = 0.152$ ) or Egger's test ( $P = 0.329$ ). For each study's DCR, publication bias was also examined using Begg's and Egger's tests, and it was found that there was publication bias [Begg's test ( $P = 0.721$ ); Egger's test ( $P = 0.034$ )]. The impact of this bias on the analysis results was

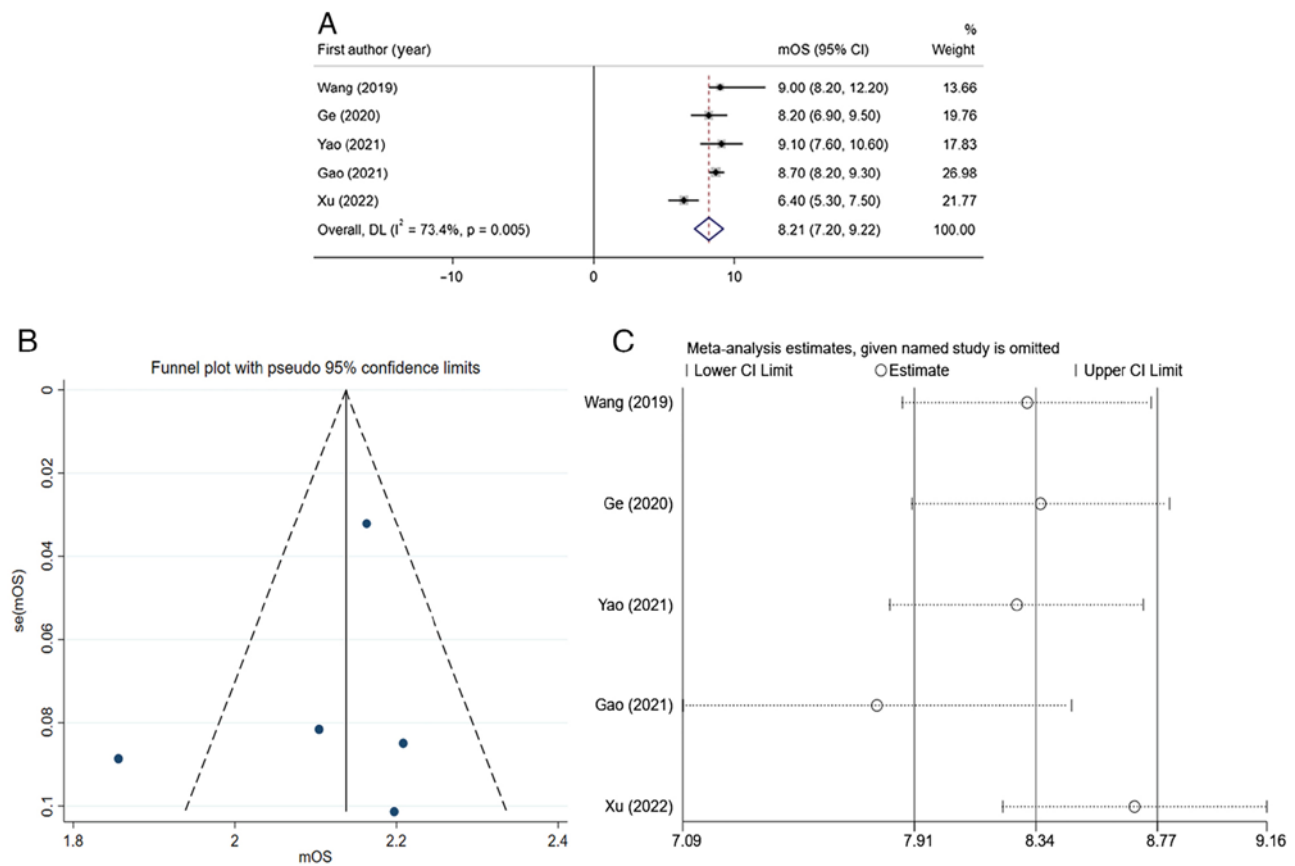


Figure 4. mOS of apatinib combined with temozolomide in the treatment of recurrent high-grade glioma. (A) After integrating the mOS of various studies using the random-effects model, the total mOS was 8.21 months (95% CI, 7.20-9.22). (B) Funnel plots of mOS for each study. (C) Sensitivity analysis of mOS for each study. mOS, median overall survival; se, standard error; DL, random-effects model.

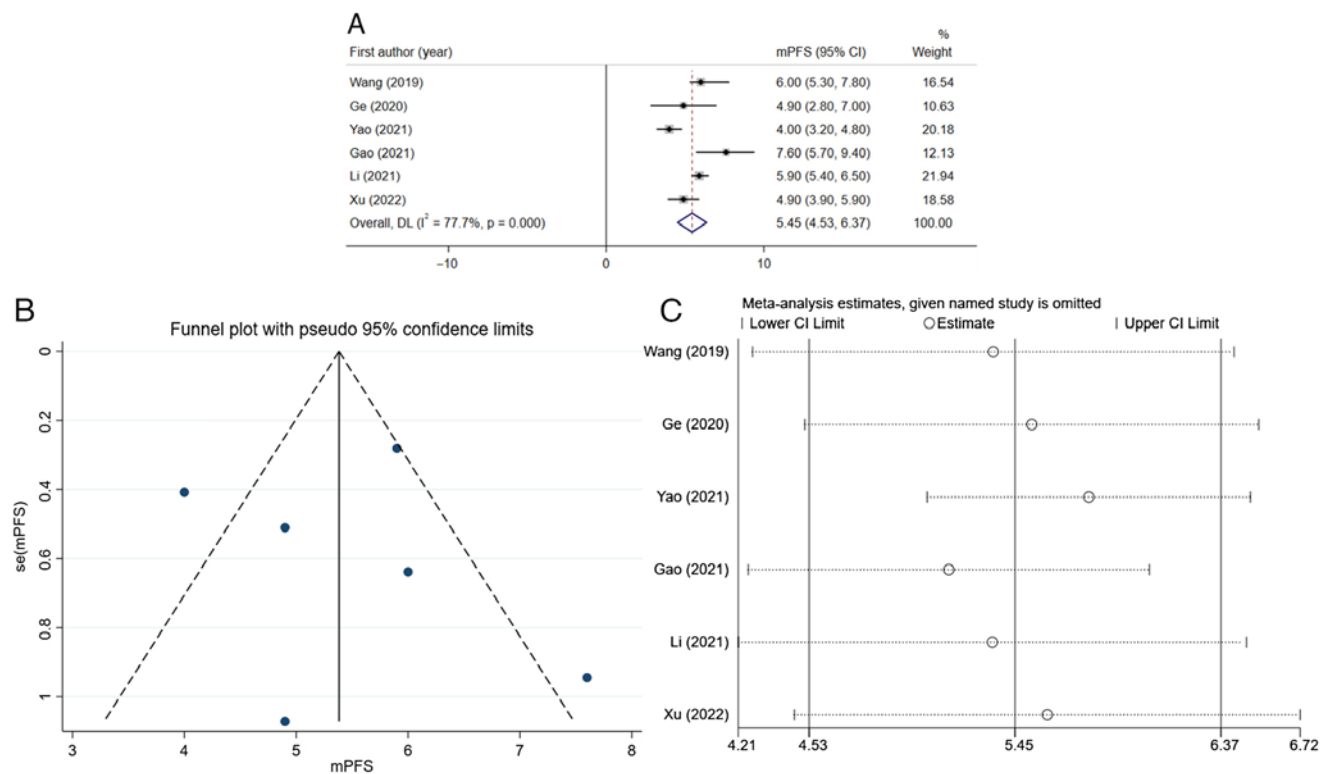


Figure 5. mPFS of apatinib combined with temozolomide in the treatment of recurrent high-grade glioma. (A) After integrating the mPFS of various studies using the random-effects model, the total mPFS was 5.45 months (95% CI, 4.53-6.37). (B) Funnel plots of mPFS for each study. (C) Sensitivity analysis of mPFS for each study. mPFS, median progression-free survival; se, standard error; DL, random-effects model.

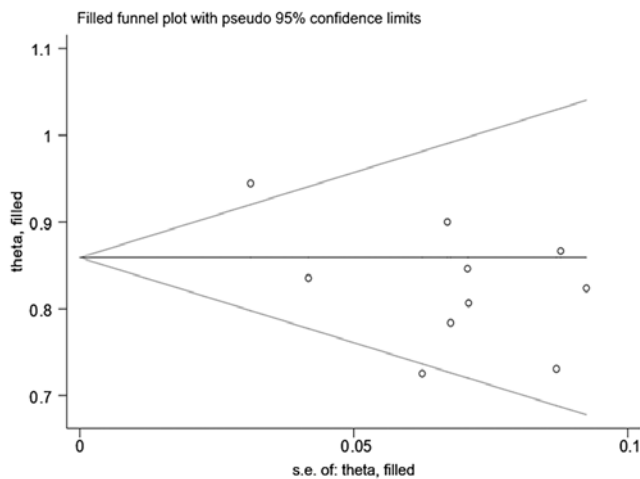


Figure 6. Filled funnel plot after correcting publication bias through the trim-and-fill method. se, standard error.

further evaluated through the trim-and-fill method, and it was found that the results were stable ( $P < 0.05$ ) (Fig. 6). Assessment of the publication bias of mOS in the prognostic analysis of the treatment of recurrent high-grade glioma with apatinib and temozolomide suggested that there was no significant publication bias according to Begg's test ( $P = 1.000$ ) and Egger's test ( $P = 0.752$ ). In addition, the results of publication bias of mPFS indicated no significant publication bias according to Begg's test ( $P = 1.000$ ) and Egger's test ( $P = 0.885$ ).

## Discussion

Glioma is a common primary intracranial tumor, which is difficult to treat and resect. In spite of receiving post-operative radiotherapy and chemotherapy, most patients still relapse, and the curative effect is poor thereafter. Currently, there is no standard treatment strategy for recurrent high-grade glioma (28,29). Temozolomide dose-dense chemotherapy combined with cisplatin, carboplatin, cyclophosphamide and other drugs has been tried clinically for the treatment of recurrent high-grade glioma, but the effect is not ideal (30).

Improvement of the clinical efficacy of recurrent high-grade glioma and the quality of life of patients remains an unsolved problem. Malignant glioma is a tumor rich in neovascularization, and high expression of VEGF and its receptor VEGFR2 may promote the proliferation, infiltration and metastasis of glioma cells (31). Both apatinib and bevacizumab are antiangiogenic agents, but the former has more advantages. Apatinib is an oral small-molecule tyrosine kinase inhibitor that targets the intracellular domain of VEGFR2 (32,33). Unlike bevacizumab, apatinib may promote tumor cell apoptosis through the intracellular autocrine VEGF signaling pathway. In addition, apatinib may also inhibit c-Kit, c-Src, platelet-derived growth factor receptor- $\beta$  and MET, directly exerting anti-tumor effects (34,35). Bevacizumab has been widely used for clinical treatment, but its efficacy is still unclear. Apatinib has attracted the attention of researchers, and cell experiments have confirmed that apatinib is able to inhibit the proliferation, invasion and metastasis of glioma cells, promote tumor cell

apoptosis and synergistically increase the anti-tumor effects of temozolomide (10).

After screening, 357 patients with high-grade, relapsed glioma were included in the present meta-analysis. These patients had relapsed after receiving the standard Stupp regimen. In certain studies, the regimen of apatinib combined with dose-dense temozolomide was used when relapse occurred (14-16,21,22,25,27). Other studies continued the conventional 5/28 temozolomide regimen based on apatinib (15,23,24,26). It was found that the overall ORR and DCR of high-grade glioma treated with apatinib and temozolomide reached 36 and 86%, respectively. After subgroup analysis, it was found that the overall ORR (43%) and DCR (89%) of the apatinib with dose-dense temozolomide group ( $n = 229$ ) were higher than those of the apatinib with conventional-dose temozolomide group ( $n = 128$ ; ORR = 26%; DCR = 76%). The results indicate that the therapeutic effect of the combination of apatinib and dose-dense temozolomide may be better than that of the conventional regimen. Further prognostic analysis indicated that the overall mOS of patients with recurrent high-grade glioma treated with apatinib combined with temozolomide chemotherapy was 8.21 months and the mPFS was 5.45 months. At present, there is no relevant meta-analysis or large-sample clinical study that analyzed the efficacy of bevacizumab combined with temozolomide or bevacizumab alone in the treatment of high-grade glioma. Duerinck *et al* (36) found that the ORR, DCR, mOS and mPFS of 313 patients with recurrent glioblastoma treated with single bevacizumab were 35.5%, 63.5%, 6 and 3 months, respectively. Another study found that the ORR of patients with recurrent high-grade gliomas was only 20%, the mOS was 4.3 months and the mPFS was 3.5 months after treatment with bevacizumab combined with dose-dense temozolomide (37). From the data of RTOG 0625 clinical trial (38), the total ORR of bevacizumab combined with dose-dense temozolomide in the treatment of recurrent glioblastoma was only 19%, mOS was 4.7 months and mPFS was 9.4 months. Although the results of the present meta-analysis were based on the conclusion of small-sample trials, they indirectly indicate that the combination of apatinib and temozolomide may be better than bevacizumab and temozolomide.

At present, there is no large-sample study that evaluated the efficacy of apatinib combined with temozolomide in the treatment of recurrent high-grade glioma. Based on extensive database retrieval, the present meta-analysis found that apatinib combined with temozolomide has a certain efficacy through data analysis of 10 studies, providing medical evidence for subsequent clinical application. The present study had certain limitations. Firstly, most of the studies were single group studies and only a small number were randomized controlled clinical trials. The sample size included in the current meta-analysis was not large and the stability and reliability of the results cannot be guaranteed. Secondly, during the integration of the ORR, subgroup analysis and prognostic analysis, significant heterogeneity was found among studies, which may affect accuracy and credibility. Thirdly, when analyzing the publication bias of each effect size, bias of the DCR was found. Although the significant impact of bias on the results was excluded through the trim-and-fill method, it may still affect the validity of the results. Lastly, the subjects included



in the present meta-analysis were mainly Chinese individuals and the efficacy in populations from other countries or regions remains undetermined.

In conclusion, the present analysis indicated that the combination of apatinib and temozolomide chemotherapy has certain efficacy and potential to improve prognosis, and it may offer a new modality for the treatment of recurrent high-grade glioma in the future. Although the synergistic effect of apatinib and temozolomide has been demonstrated in cell experiments, its clinical application remains insufficient. The present meta-analysis study provided a comprehensive analysis based on existing research data, thereby obtaining objective results. However, there are not several relevant clinical large-sample trials or controlled trials with other drug schemes to verify its efficacy. If more prospective or randomized controlled studies were available in the future, more accurate and stable results may be obtained by further analysis.

### Acknowledgements

Not applicable.

### Funding

No funding was received.

### Availability of data and materials

All data generated or analyzed during this study are included in this published article.

### Authors' contributions

GL designed the study. GL, JC and XX screened the literature and extracted the data. GL and XX confirm the authenticity of all the raw data. GL and FZ conducted the meta-analysis. SW acquired, analyzed, verified and reviewed the results. All authors have read and approved the final version of the manuscript.

### Ethics approval and consent to participate

Not applicable.

### Patient consent for publication

Not applicable.

### Competing interests

The authors declare that they have no competing interests.

### References

- Wu H, Deng Z, Wang H, Li X, Sun T, Tao Z, Yao L, Jin Y, Wang X, Yang L, *et al*: MGMT autoantibodies as a potential prediction of recurrence and treatment response biomarker for glioma patients. *Cancer Med* 8: 4359-4369, 2019.
- Stupp R, Mason WP, van den Bent MJ, Weller M, Fisher B, Taphoorn MJB, Belanger K, Brandes A, Marosi C, Bogdahn U, *et al*: Radiotherapy plus concomitant and adjuvant temozolomide for glioblastoma. *N Engl J Med* 352: 987-996, 2005.
- Hervy-Jumper SL and Berger MS: Reoperation for recurrent high-grade glioma: A current perspective of the literature. *Neurosurgery* 75: 491-499, 2014.
- Stupp R, Wong ET, Kanner AA, Steinberg D, Engelhard H, Heidecke V, Kirson ED, Taillibert S, Liebermann F, Dbaly V, *et al*: NovoTTF-100A versus physician's choice chemotherapy in recurrent glioblastoma: A randomized phase III trial of a novel treatment modality. *Eur J Cancer* 48: 2192-2202, 2012.
- Lang FF, Conrad C, Gomez-Manzano C, Yung WKA, Sawaya R, Weinberg JS, Prabhu SS, Rao G, Fuller GN, Aldape KD, *et al*: Phase I study of DNX-2401(Delta-24-RGD) oncolytic adenovirus: Replication and immunotherapeutic effects in recurrent malignant glioma. *J Clin Oncol* 36: 1419-1427, 2018.
- Tuetttenberg J, Friedel C and Vajkoczy P: Angiogenesis in malignant glioma-a target for antitumor therapy? *Crit Rev Oncol Hematol* 59: 181-193, 2006.
- Rainer E, Wang H, Traub-Weidinger T, Widhalm G, Fueger B, Chang J, Zhu Z, Marosi C, Haug A, Hacker M and Li S: The prognostic value of [<sup>125</sup>I]-vascular endothelial growth factor ([<sup>125</sup>I]-VEGF) in glioma. *Eur J Nucl Med Mol Imaging* 45: 2396-2403, 2018.
- Kreisl TN, Kim L, Moore K, Duic P, Royce C, Stroud I, Garren N, Mackey M, Butman JA, Camphausen K, *et al*: Phase II trial of single-agent bevacizumab followed by bevacizumab plus irinotecan at tumor progression in recurrent glioblastoma. *J Clin Oncol* 27: 740-745, 2009.
- Liang Q, Kong L, Du Y, Zhu X and Tian J: Antitumorigenic and antiangiogenic efficacy of apatinib in liver cancer evaluated by multimodality molecular imaging. *Exp Mol Med* 51: 1-11, 2019.
- Wang C, Jiang M, Hou H, Lin Q, Yan Z and Zhang X: Apatinib suppresses cell growth and metastasis and promotes antitumor activity of temozolomide in glioma. *Oncol Lett* 16: 5607-5614, 2018.
- Li J, Qin S, Xu J, Xiong J, Wu C, Bai Y, Liu W, Tong J, Liu Y, Xu R, *et al*: Randomized, double-blind, Placebo-controlled phase III trial of Apatinib in patients with chemotherapy-refractory advanced or metastatic adenocarcinoma of the stomach or Gastroesophageal junction. *J Clin Oncol* 34: 1448-1454, 2016.
- Zhang L, Shi M, Huang C, Liu X, Xiong JP, Liu GC, Liu W, Zhang Y, Li K, Yu H and Jiang H: A phase II, multicenter, placebo-controlled trial of apatinib in patients with advanced nonsquamous non-small cell lung cancer (NSCLC) after two previous treatment regimens. *J Clin Oncol* 30 (15\_suppl): 7548, 2012.
- Hu X, Cao J, Hu W, Wu C, Pan Y, Cai L, Tong Z, Wang S, Li J, Wang Z, *et al*: Multicenter phase II study of apatinib in non-triple-negative metastatic breast cancer. *BMC Cancer* 14: 820, 2014.
- Wang Y, Meng X, Zhou S, Zhu Y, Xu J and Tao R: Apatinib plus temozolomide for recurrent glioblastoma: An uncontrolled, open-label study. *Onco Targets Ther* 12: 10579-10585, 2019.
- Zhou PC, Pan HH, Liang TS and Yang DK: Short-term efficacy of apatinib combined with dose-dense temozolomide in treatment of recurrent malignant glioma after postoperative chemoradiotherapy. *J Med Forum* 41: 73-79, 2020 (In Chinese).
- Ge J, Li C, Xue F, Qi S, Gao Z, Yu C and Zhang J: Apatinib plus Temozolomide: An effective salvage treatment for recurrent glioblastoma. *Front Oncol* 10: 601175, 2021.
- Wei W, Chen X, Ma XM, Wang D and Guo Z: The efficacy and safety of various dose-dense regimens of temozolomide for recurrent high-grade glioma: A systematic review with meta-analysis. *J Neurooncol* 125: 339-349, 2015.
- Page MJ, McKenzie JE, Bossuyt PM, Boutron I, Hoffmann TC, Mulrow CD, Shamseer L, Tetzlaff JM, Akl EA, Brennan SE, *et al*: The PRISMA 2020 statement: An updated guideline for reporting systematic reviews. *BMJ* 372: n71, 2021.
- Higgins JPT, Thompson SG, Deeks JJ and Altman DG: Measuring inconsistency in meta-analyses. *BMJ* 327: 557-560, 2003.
- Egger M, Smith GD, Schneider M and Minder C: Bias in meta-analysis detected by a simple, graphical test. *BMJ* 315: 629-634, 1997.
- Liu ZJ, Sun HW, Song ZY, Guo S, Gao M, Zhou G and Liu X: Apatinib combined with dose-dense temozolomide in the treatment of recurrent malignant glioma. *Chin J Pract Nerv Dis* 23: 958-962, 2020 (In Chinese).
- Yao H, Liu JG, Zhang C, Shao Y, Li X, Feng M, Wang X, Gan W, Zhou Y and Huang Y: Clinical study of apatinib plus temozolomide for the treatment of recurrent high-grade gliomas. *J Clin Neurosci* 90: 82-88, 2021.

23. Gao M, Li MY, Ma QQ, Shi H and Yang Y: Brucea javanica oil emulsion combined with apatinib and temozolomide in the treatment of recurrent high-grade glioma. *J Basic Clin Oncol* 34: 36-40, 2021 (In Chinese).
24. Li TY, Hai L, Wu H, Hong X, Lu X and Sun X: Clinical research of apatinib in the treatment of drug-resistant recurrent glioblastoma. *Chin J Clin Oncol* 48: 619-623, 2021 (In Chinese).
25. Xu KY, Jiao Y, Wang JK, Liu X, Sun H, Luo W and Zhao H: Effect of apatinib combined with temozolomide in the treatment of recurrent high-grade glioma. *Henan J Surgery* 28: 30-32, 2022 (In Chinese).
26. Zhang M, Gao LY, Liu X, Dong F, Su Q, Zhang Y, Li F, Wang H and Han P: Low-dose Apatinib improves the prognosis of patients with recurrent high-grade gliomas. *Evid Based Complement Alternat Med* 2022: 3181133, 2022.
27. Quan LL, Song HB and Song LL: Short term and long-term efficacy of bevacizumab monoclonal antibody and apatinib combined with temozolomide in treatment of recurrent high-grade glioma. *Chin J Mod Med* 32: 11-15, 2022 (In Chinese).
28. Ostrom QT, Cioffi G, Gittleman H, Patil N, Waite K, Kruchko C and Barnholtz-Sloan JS: CBTRUS statistical report: Primary brain and other central nervous system tumors diagnosed in the United States in 2012-2016. *Neuro Oncol* 21 (Suppl 5): v1-v100, 2019.
29. Wick W, Weller M, Van den bent M, Sanson M, Weiler M, von Deimling A, Plass C, Hegi M, Platten M, Reifenberger G, *et al*: MGMT testing-the challenges for biomarker-based glioma treatment. *Nat Rev Neurol* 10: 372-385, 2014.
30. Nabors LB, Portnow J, Ahluwalia M, Baehring J, Brem H, Brem S, Butowski N, Campian JL, Clark SW, Fabiano AJ, *et al*: Central nervous system cancers, version 3.2020, NCCN clinical practice guidelines in oncology. *J Natl Compr Canc Netw* 18: 1537-1570, 2020.
31. Jain HV, Nör JE and Jackson TL: Modeling the VEGF-Bcl-2-CXCL8 pathway in intratumoral angiogenesis. *Bull Math Biol* 70: 89-117, 2008.
32. Peng S, Zhang Y, Peng H, Ke Z, Xu L, Su T, Tsung A, Tohme S, Huang H, Zhang Q, *et al*: Intracellular autocrine VEGF signaling promotes EBDC cell proliferation, which can be inhibited by Apatinib. *Cancer Lett* 373: 193-202, 2016.
33. Peng H, Zhang Q, Li J, Zhang N, Hua Y, Xu L, Deng Y, Lai J, Peng Z, Peng B, *et al*: Apatinib inhibits VEGF signaling and promotes apoptosis in intrahepatic cholangiocarcinoma. *Oncotarget* 7: 17220-17229, 2016.
34. Tong XZ, Wang F, Liang S, Zhang X, He JH, Chen XG, Liang YG, Mi YJ, To KKW and Fu LW: Apatinib (YN968D1) enhances the efficacy of conventional chemotherapeutic drugs in side population cells and ABCB1-overexpressing leukemia cells. *Biochem Pharmacol* 83: 586-597, 2012.
35. Roviello G, Ravelli A, Fiaschi AI, Cappelletti MR, Gobbi A, Senti C, Zanotti L, Polom K, Reynolds AR, Fox SB and Generali D: Apatinib for the treatment of gastric cancer. *Expert Rev Gastroenterol Hepatol* 10: 887-892, 2016.
36. Duerinck J, Clement PM, Bouttens F, Andre C, Neyns B, Staelens Y, Fraeyenhove FV, Baurain JF, Luce S, D'hondt L, *et al*: Patient outcome in the Belgian medical need program on bevacizumab for recurrent glioblastoma. *J Neurol* 262: 742-751, 2015.
37. Verhoeff JJC, Lavini C, van Linde ME, Stalpers LJA, Majoie CBLM, Reijneveld JC, van Furth WR and Richel DJ: Bevacizumab and dose-intense temozolomide in recurrent high-grade glioma. *Ann Oncol* 21: 1723-1727, 2010.
38. Gilbert MR, Pugh SL, Aldape K, Sorensen AG, Mikkelsen T, Penas-Prado M, Bokstein F, Kwok Y, Lee RJ and Mehta M: NRG oncology RTOG 0625: A randomized phase II trial of bevacizumab with either irinotecan or dose-dense temozolomide in recurrent glioblastoma. *J Neurooncol* 131: 193-199, 2017.



Copyright © 2023 Li *et al*. This work is licensed under a Creative Commons Attribution-NonCommercial-NoDerivatives 4.0 International (CC BY-NC-ND 4.0) License.