

## Prolonged response to entrectinib in an adult patient with recurrent glioblastoma harboring a *GOPC::ROS1* fusion

Giulia Cerretti<sup>®</sup>, Marta Padovan, Angela Guerriero, Marta Maccari, Alberto Bosio, Mario Caccese, Eugenia Cella, Giovanna Pintacuda, Giovanni Librizzi, and Giuseppe Lombardi<sup>®</sup>

All author affiliations are listed at the end of the article

**Corresponding Author:** Giulia Cerretti, MD, IRCCS Istituto Oncologico Veneto, Via Gattamelata 64—35128, Padova, Italy ([giuliacerretti@gmail.com](mailto:giuliacerretti@gmail.com), [giulia.cerretti@iov.veneto.it](mailto:giulia.cerretti@iov.veneto.it))

**Data on the use of targeted therapies in glioma are still limited, and the identification of useful targetable mutations is still under investigation. Among all the relevant alterations identified through next-generation sequencing tests, *ROS1* alterations can rarely be found in gliomas, and the most common of them is *GOPC::ROS1* fusion. Targeted therapies, such as entrectinib, are available for such alterations. Hereby, the case of a patient affected by *GOPC::ROS1* fused glioblastoma and treated with entrectinib is presented; this patient achieved a complete and prolonged response with no relevant toxicities from the treatment.**

Glioblastoma is the most common malignant primary brain tumor. Despite some therapeutic advances including surgery, radiotherapy, systemic therapy (chemotherapy, targeted therapy), tumor treating fields, and supportive care, the overall prognosis remains poor, and long-term survival is difficult to achieve (usually <2 years).<sup>1</sup>

Next-generation sequencing (NGS) is a useful tool that is increasingly being used in clinical practice due to the widespread availability of commercial assays, but there are doubts about the impact of this strategy on the choice of glioblastoma therapies.<sup>2</sup> The European Society of Medical Oncology for Clinical Actionability of Molecular Targets (ESCAT) Scale is a tool designed to guide the appropriate and clinically relevant interpretation of NGS tests for the detection of useful molecular alterations in cancer.<sup>3</sup>

The types of targetable genetic variants identified in glioblastoma are numerous. In *IDH* wild-type (*IDHwt*) glioblastoma, a number of different targets have been identified, including the phosphoinositide 3-kinase (*PI3K*) and *MET* pathways, the v-Raf murine sarcoma viral oncogene homolog V1 (*BRAF*) V600E mutations, and fusions such as in the fibroblast growth factor receptor and neurotrophic tyrosine receptor kinase (*NTRK*).<sup>4</sup> Rare cases of *NTRK/ROS1/ALK* fusion-positive high-grade glioma in adults have been described.<sup>5</sup>

*ROS1* encodes an evolutionarily conserved RTK and a variety of cancers express aberrant isoforms of this gene. In contrast to *ROS1* overexpression, splice variants, mutations,

or amplifications, much data support the notion that *ROS1* fusions are true drivers of oncogenesis. *ROS1* fusions exhibit ligand-independent, constitutive catalytic activity. These fusions activate canonical cell survival and growth signaling pathways, including the aforementioned *RAS–MEK–ERK*, *JAK–STAT3*, *PI3K–AKT–mTOR*, and *SHP2* cascades.<sup>6</sup>

The role of *ROS1* fusions is particularly relevant in non-small-cell lung cancer (NSCLC), where rearrangements are present in approximately 0.9%–2.6% of cases, with different gene partners (*CD74*, *EZR*, *SDC4*, and *SLC34A2*); 2TKIs have been validated as first-line therapy for *ROS1*-positive NSCLCs crizotinib and entrectinib.<sup>7</sup>

*GOPC::ROS1* fusions have been identified in hepatic angiosarcoma,<sup>8</sup> atypical Spitz naevi,<sup>9</sup> nasopharyngeal papillary adenocarcinoma,<sup>10</sup> and pediatric/adult gliomas and glioneuronal tumors.<sup>11,12</sup> They represent the most common *ROS1* fusion in gliomas, according to pediatric data.<sup>13,14</sup>

In adult gliomas, *ROS1* fusions account for approximately 0.5%–1% of cases; in pediatric gliomas, they account for approximately 7% of cases.<sup>14–16</sup> The first *ROS1* gene fusion was identified in the U118MG glioblastoma cell line in 1987; subsequently, a series of studies characterized the oncogenic potential of this fusion in gliomagenesis and the signaling pathways it activates.<sup>6</sup>

Several therapies targeting alterations in the *NTRK/ROS1/ALK* pathway have been investigated.

Among them, entrectinib is a potent *TRKA/B/C*, *ROS1*, *ALK* tyrosine kinase inhibitor with high central nervous system (CNS) penetrance, and it is already approved for the treatment of adults and children aged ≥12 years with *NTRK* fusion-positive solid tumors and adults with *ROS1* fusion-positive NSCLC. The most common side effects include hepatotoxicity, cardiotoxicity including congestive heart failure and QTc interval prolongation, bone fractures, vision problems, visual disturbances, and hyperuricemia.

To the best of our knowledge, treatment response to entrectinib in adult patients with *ROS1* fusion-positive glioblastoma has not yet been reported; this is the first report

of an excellent and durable response to entrectinib in a recurrent glioblastoma patient with *GOPC::ROS1* fusion.

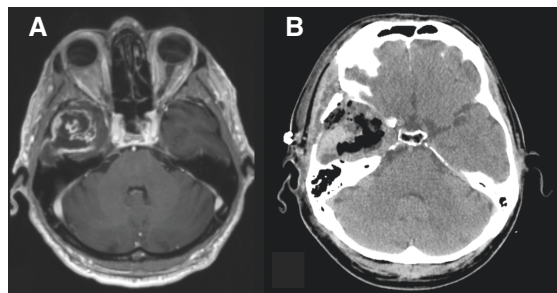
This case was included in a larger series of patients treated with targeted therapies published by Padovan et al.<sup>5</sup>

## Clinical Presentation

The case of a 68-year-old male patient with IDHwt glioblastoma is presented. The patient was referred to our center, the Veneto Institute of Oncology, in January 2022. He had no relevant familial cancer history. He was diagnosed with right temporal glioblastoma in July 2020; immunohistochemistry confirmed the IDHwt status and pyrosequencing confirmed the absence of methylation on the *MGMT* promoter. He was treated with radical resection (Figure 1) followed by standard treatment according to the Stupp protocol. He underwent concomitant CT-RT until November 2020 and then he received 12 cycles of temozolomide until November 2021.

A brain MRI performed in January 2022 showed disease progression with the appearance of a new enhancing nodule medial to the surgical resection, within the irradiation field (RT completed 1 year and 2 months before; Figure 2).

When the patient was referred to our center, he was in good clinical conditions, ECOG PS 0 (KPS 100), with no detectable neurological deficits. He had no relevant past medical history and no toxicities from previous treatments. Formalin-fixed paraffin-embedded tumor tissue from the first surgery in July 2020 was analyzed by a molecular NGS test using the FoundationOne®CDx test (a kit analyzing 324 genes, available as a prescreen in Roche's STARTRK2 clinical trial NCT02568267<sup>17</sup>), and *GOPC::ROS1* fusion was detected. Other alterations detected were *PTEN* loss, *CDKN2A/2B* loss, *EGFR* T263P mutation, *TERT* promoter C250T mutation; tumor mutational burden 2.52, and microsatellite status stable. Of note, IHC analysis for *ROS1* fusion was performed on tissue and was negative (clone D4D6, Cell Signaling Technology, dilution 1:100 was used; Figure 3).



**Figure 1.** (A) Preoperative gadolinium brain MRI. (B) Postoperative CT scan.

Following the screening procedures, the patient was accepted into the study and started treatment with entrectinib 600 mg/day continuously. After 2 months of treatment, a partial response according to RANO criteria was reported, and after 6 months of treatment, in August 2022, a complete response was achieved and maintained for an additional 6 months. No toxicities were observed; the patient was monitored regularly by clinical examination, laboratory tests, cardiological evaluation, bone density scan, and ophthalmological evaluation. The treatment was well tolerated and no dose reductions or discontinuations were required.

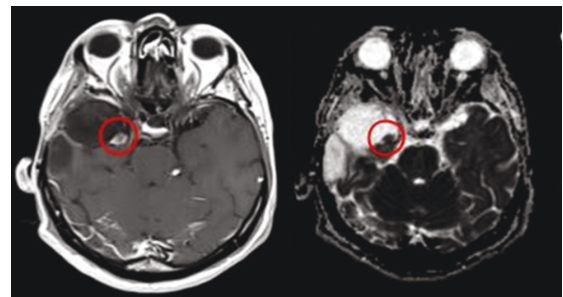
The brain MRI performed in January 2023 showed disease progression due to the appearance of a new enhancing lesion below the site of the previous nodule, within the previous irradiation field, and treatment was discontinued (Figure 4). He underwent a second surgery and is currently receiving palliative care for support.

## Discussion

We present the case of a patient diagnosed with aggressive glioblastoma with negative prognostic factors (unmethylated *MGMT* promoter) and *GOPC::ROS1* fusion who relapsed on standard first-line Stupp protocol therapy and achieved an impressive and durable response to entrectinib as second-line therapy. The patient experienced no toxicity.

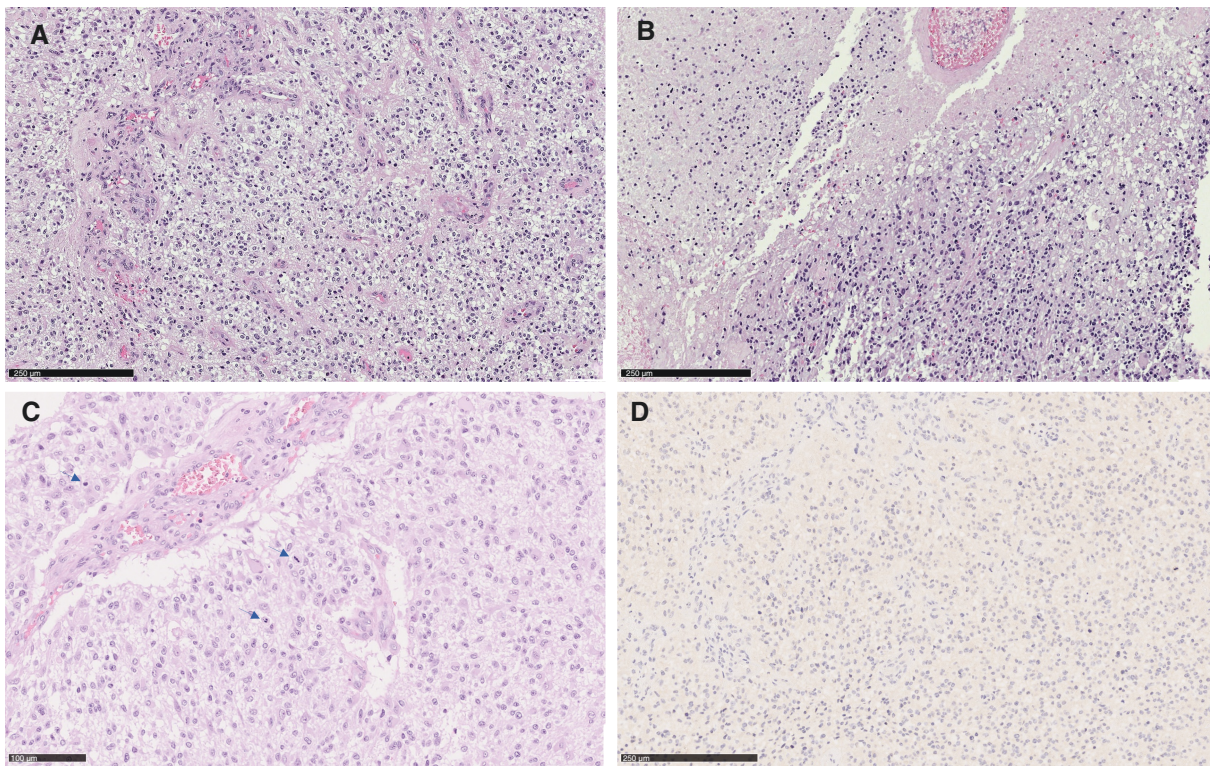
NGS testing is a tool that is increasingly being used in clinical practice and also in primary CNS tumors; strategies to implement a rational approach to molecular testing are increasingly being evaluated.<sup>18</sup>

According to the ESCAT, *ROS1* alterations in NSCLC are at level Tier IB, which means that the target is suitable for routine use and that specific recommended drugs are available if a specific molecular alteration is detected.<sup>3</sup> Instead, according to the EANO guidelines, *ROS1* fusions in adult patients with glioma, glioneuronal, or neuronal tumors are considered Tier IIIA, which means that testing for the target should only be considered in patients who have exhausted

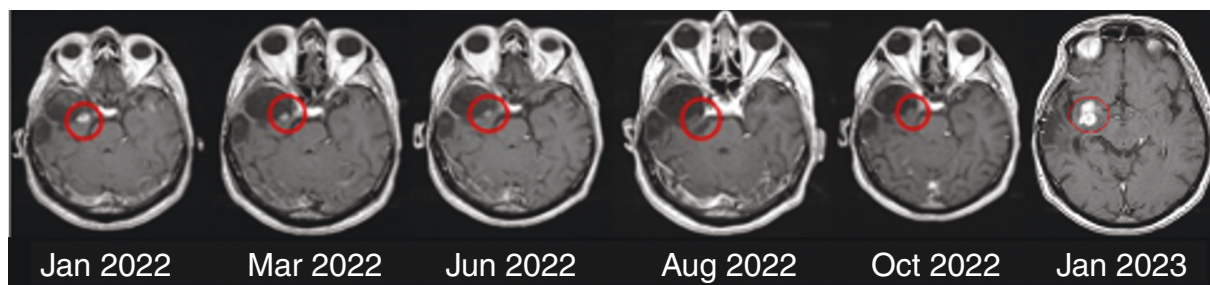


**Figure 2.** Post-contrast T1-weighted MRI shows progressive disease with the appearance of an enhancement node at the surgical pericavity (left). The apparent diffusion coefficient (ADC) map shows a corresponding increase in ADC values ( $ADC = 970 \times 10^{-6} \text{ mm}^2/\text{s}$ ), consistent with an increased cellularity (right).





**Figure 3.** Hypercellularity and microvascular proliferation (A), necrosis (B), and marked cytological atypia with numerous mitotic figures (arrows, C). Negative ROS1 immunohistochemistry in this patient (D).



**Figure 4.** Brain MRI from January 2022 (baseline) to January 2033 (progression) with durable response to entrectinib.

standard treatment options, are in good enough clinical conditions and have clinical trial options available.<sup>18</sup> In our case, NGS testing revealed a targetable molecular alteration suitable for targeted treatment in a clinical trial after progression on first-line standard therapy.

Although *ROS1* was negative on immunohistochemistry in our case, international guidelines recommend immunohistochemistry (IHC) as a screening method for *ROS1* fusions in lung cancer<sup>19</sup> and this technique is usually highly concordant and less expensive than FISH. Confirmation of positive cases is recommended by a cytogenetic or molecular method. There is still no real-world evidence for the determination of *ROS1*, although there are 2 commercially available antibodies. In addition, it is

important to consider that *ROS1* expression without underlying rearrangement (false positives) has been described in almost one-third of tumors.<sup>19</sup> In gliomas, although *ROS1* rearrangements can be detected by FISH, *GOPC::ROS1* fusions can be difficult to detect by FISH analysis because both genes are closely located on 6q22.1 and require a specifically designed probe set to detect them.<sup>20</sup> Therefore, the use of molecular techniques to detect such alterations is justified.

*ROS1* fusions have been highly characterized in NSCLC; to date, 4 FDA-approved drugs have significant activity against *ROS1* fusion in NSCLC, crizotinib, ceritinib, lorlatinib, and entrectinib.<sup>21</sup> Recently, repotrectinib was added to the list.<sup>22</sup>

In primary CNS tumors, *ROS1* fusions have been reported in a few glioma cases, especially in pediatric patients; specifically, it is the second most common alteration in the hemispheric RTK-driven hemispheric infantile gliomas.<sup>23</sup> Limited data are available in adult patients and, to our knowledge, no data are available in adult glioblastoma patients with *GOPC::ROS1* fusions treated with entrectinib as in this patient.

Entrectinib has been approved for the treatment of *ROS1* mutated NSCLC and is especially effective in case of CNS involvement due to its high penetrance of the blood–brain barrier and responses in CNS metastatic disease.<sup>24</sup> This supports the use of this drug in the CNS setting.

The STARTRK-NG trial was a phase 1/2 basket trial evaluating entrectinib activity in pediatric patients with extracranial solid tumors or primary CNS tumors, with or without target gene fusions in *NTRK1/2/3*, *ROS1*, or *ALK*.<sup>25</sup> In this trial, 16 pediatric patients with primary CNS tumors were enrolled; specifically 1 patient with *GOPC::ROS1* pilocytic astrocytoma, 1 patient with *GOPC::ROS1* glioma NOS, and 1 patient with *GOPC::ROS1* diffuse midline glioma. In the general population, the objective response rate (ORR) was 50.0% (95% confidence interval [CI] 24.7–75.4), while in the specific subgroup with *ROS1* fusion, the ORR was 62.5% (95% CI 24.5–91.5). Adverse events (AEs) led to dose reduction in 16 patients (37.2%) and 8 patients (18.6%) discontinued entrectinib due to AEs.<sup>25</sup> Based on STARTRK-NG, the STARTRK2 trial was designed as a basket trial including adult solid tumors (also CNS primary tumors) with gene fusions in *NTRK1/2/3*, *ROS1*, or *ALK* treated with entrectinib.<sup>17</sup>

In our case, we also confirmed the response to entrectinib according to the RANO criteria in a patient with *ROS1* fusion glioblastoma, reporting an impressive and durable response over 12 months with optimal tolerability.

While IDHwt GBM with specific rare targetable mutations share genetic and epigenetic similarities with nontargetable IDHwt GBM, there may be a distinct biological feature that contributes to a more favorable disease course and potentially prolonged response to therapy. This clinical case highlights the importance of considering NGS testing in glioblastoma patients, especially after failure of first-line therapy in patients with good performance status. Otherwise, it is extremely important to refer glioblastoma patients to highly specialized neuro-oncology centers and to recognize that NGS testing can indeed be a powerful tool to modify the therapeutic strategy. Access to clinical trials evaluating new targeted therapies remains a fundamental opportunity for these patients, who otherwise have a very poor prognosis and few therapeutic options.

Concerns remain regarding the implementation and financing of these tests, the possible predictive value of the molecular alterations detected by such tests, the problem of their interpretation, and, finally, access to the therapeutic options that may be available.

## Keywords

complete response | entrectinib | glioblastoma | *ROS1* | targeted therapy

## Funding

This research received “Ricerca Corrente 2024” funding from the Italian Ministry of Health to cover publication costs (CDC 099183).

## Conflict of interest statement

The authors declare no conflicts of interest.

## Authorship statement

Writing—original draft: G.C., M.P., G.Lo., A.G., G.Li.; Writing—review and editing: G.C., M.P., G.Lo., A.G., G.Li., M.M., A.B., M.C., E.C., G.P.

## Affiliations

Department of Oncology, Oncology 1, Veneto Institute of Oncology IOV—IRCCS, Padova, Italy (G.C., M.P., M.M., A.B., M.C., G.Lo.); PhD course in Clinical and Experimental Oncology and Immunology, Department of Surgery, Oncology and Gastroenterology, University of Padova, Padova, Italy (G.C., M.P.); Surgical Pathology Unit, University Hospital of Padova, Padova, Italy (A.G.); School of Specialization in Medical Oncology, Department of Surgery, Oncology and Gastroenterology, University of Padova, Padova, Italy (M.M., A.B.); Oncology 2, IRCCS Ospedale San Martino, Genova, Italy (E.C.); Radiology Unit, Veneto Institute of Oncology IOV – IRCCS (G.P.); Department of Neuroscience, Azienda Ospedale-Università di Padova, Padova, Italy (G.Li.)

## References

1. Tan AC, Ashley DM, López GY, et al. Management of glioblastoma: state of the art and future directions. *CA Cancer J Clin.* 2020;70(4):299–312.
2. Zeitlberger AM, Putora PM, Hofer S, et al. Next generation sequencing in adult patients with glioblastoma in Switzerland: a multi-centre decision analysis. *J Neurooncol.* 2022;158(3):359–367.
3. Mateo J, Chakravarty D, Dienstmann R, et al. A framework to rank genomic alterations as targets for cancer precision medicine: the ESMO Scale for Clinical Actionability of molecular Targets (ESCAT). *Ann Oncol.* 2018;29(9):1895–1902.
4. Mj LF, Gc Y, M T, et al. Clinical utility of targeted next-generation sequencing assay in IDH-wildtype glioblastoma for therapy decision-making. *Neuro-Oncology.* 2022;24(7):1140–1149.
5. Padovan M, Maccari M, Bosio A, et al. Actionable molecular alterations in newly diagnosed and recurrent IDH1/2 wild-type glioblastoma patients and therapeutic implications: a large mono-institutional experience using extensive next-generation sequencing analysis. *Eur J Cancer.* 2023;191:112959.



6. Drilon A, Jenkins C, Iyer S, et al. ROS1-dependent cancers—biology, diagnostics and therapeutics. *Nat Rev Clin Oncol*. 2021;18(1):35–55.
7. Gendarme S, Bylicki O, Chouaid C, Guisier F. ROS-1 fusions in non-small-cell lung cancer: evidence to date. *Curr Oncol*. 2022;29(2):641–658.
8. Ei M, S P, D D, et al. ROS1-GOPC/FIG: a novel gene fusion in hepatic angiosarcoma. *Oncotarget*. 2019;10(2):35–55.
9. Goto K, Pissaloux D, Kauer F, Huriet V, Tirode F, de la Fouchardière A. GOPC-ROS1 mosaicism in agminated *Spitz naevi*: report of two cases. *Virchows Arch Int J Pathol*. 2021;479(3):559–564.
10. Wang J, Luo S, Li Y, Zheng H. Nasopharyngeal papillary adenocarcinoma harboring a fusion of ROS1 with GOPC: a case report. *Medicine (Baltimore)*. 2021;100(3):e24377.
11. Richardson TE, Tang K, Vasudevaraja V, et al. GOPC-ROS1 fusion due to microdeletion at 6q22 is an oncogenic driver in a subset of pediatric gliomas and glioneuronal tumors. *J Neuropathol Exp Neurol*. 2019;78(12):1089–1099.
12. Karayan-Tapon L, Cortes U, Rivet P, et al. Lack of GOPC-ROS1 (FIG-ROS1) rearrangement in adult human gliomas. *Eur J Cancer*. 2014;50(13):2364–2366.
13. Meredith DM, Cooley LD, Dubuc A, et al. ROS1 alterations as a potential driver of gliomas in infant, pediatric, and adult patients. *Modn Pathol*. 2023;36(11):100294.
14. Sievers P, Stichel D, Sill M, et al. GOPC:ROS1 and other ROS1 fusions represent a rare but recurrent drug target in a variety of glioma types. *Acta Neuropathol (Berl)*. 2021;142(6):1065–1069.
15. Davare MA, Henderson JJ, Agarwal A, et al. Rare but recurrent ROS1 fusions resulting from chromosome 6q22 microdeletions are targetable oncogenes in glioma. *Clin Cancer Res*. 2018;24(24):6471–6482.
16. Nagasaka M, Zhang SS, Baca Y, et al. Pan-tumor survey of ROS1 fusions detected by next-generation RNA and whole transcriptome sequencing. *BMC Cancer*. 2023;23(1):1000.
17. Hoffmann-La Roche. Study Of Entrectinib (Rxdx-101) in Children and Adolescents With Locally Advanced or Metastatic Solid or Primary CNS Tumors and/or Who Have No Satisfactory Treatment Options (STARTRK-NG). <https://clinicaltrials.gov/ct2/show/NCT02568267>
18. Capper D, Reifenberger G, French PJ, et al. EANO guideline on rational molecular testing of gliomas, glioneuronal, and neuronal tumors in adults for targeted therapy selection. *Neuro-Oncology*. 2023;25(5):813–826.
19. Martín-López J, Rojo F, Martínez-Pozo A, et al. Biomarker testing strategies in non-small cell lung cancer in the real-world setting: analysis of methods in the Prospective Central Lung Cancer Biomarker Registry (LungPath) from the Spanish Society of Pathology (SEAP). *J Clin Pathol*. 2023;76(5):327–332.
20. Nakano Y, Tomiyama A, Kohno T, et al. Identification of a novel KLC1–ROS1 fusion in a case of pediatric low-grade localized glioma. *Brain Tumor Pathol*. 2019;36(1):14–19.
21. Azelby CM, Sakamoto MR, Bowles DW. ROS1 targeted therapies: current status. *Curr Oncol Rep*. 2021;23(8):94.
22. Dhillon S. Repotrectinib: first approval. *Drugs*. 2024;84(2):239–246.
23. Guerreiro Stucklin AS, Ryall S, Fukuoka K, et al. Alterations in ALK/ROS1/NTRK/MET drive a group of infantile hemispheric gliomas. *Nat Commun*. 2019;10(1):4343.
24. Menichincheri M, Ardini E, Magnaghi P, et al. Discovery of entrectinib: a new 3-aminoindazole as a potent anaplastic lymphoma kinase (ALK), c-ros oncogene 1 kinase (ROS1), and pan-tropomyosin receptor kinases (pan-TRKs) inhibitor. *J Med Chem*. 2016;59(7):3392–3408.
25. Desai AV, Robinson GW, Gauvain K, et al. Entrectinib in children and young adults with solid or primary CNS tumors harboring NTRK, ROS1, or ALK aberrations (STARTRK-NG). *Neuro-Oncology*. 2022;24(10):1776–1789.