



OPEN ACCESS

Petroclival meningioma regression after combined oestrogen and nomegestrol acetate interruption

Julie Lebeau,¹ Louis Deprez,² Axelle Pintiaux,³ Gilles Reuter ⁴¹CHU de Liège, Liège, Belgium²Radiodiagnostics, CHU de Liège, Liège, Belgium³Gynaecology and Obstetrics, CHU de Liège, Liège, Belgium⁴Neurosurgery, CHU de Liège Hospital Sart Tilman, Liège, Belgium**Correspondence to**Dr Gilles Reuter;
gilles.reuter@chuliege.be

Accepted 25 December 2024

SUMMARY

Meningioma regression after progestin treatment interruption is already established. Zoely is a combined oral contraceptive including oestradiol and progestin (nomegestrol acetate). The effect of combined oestrogen with nomegestrol acetate on meningioma is currently unknown. We report the case of a woman in her early 50s under Zoely for 5 years who was diagnosed with a large petroclival meningioma. After cessation of Zoely, the patient showed clinical improvement and shrinkage of the tumour volume from 27.22 cm³ to 20.54 cm³ in 6 months. This is probably the first report of spontaneous meningioma regression after Zoely interruption.

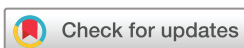BACKGROUND

Along with older age, female gender,¹ genetic disorders (neurofibromatosis type 2, neurofibromatosis type 1, protein patched homolog 1 mutation, cyclic-AMP response element-binding protein mutation, von Hippel-Lindau disease, phosphatase and tensin homolog mutation, cyclin dependent kinase inhibitor 2a mutation),² personal and/or familial history of meningioma or breast cancer,³ history of ionising radiation,⁴ black race⁵ and obesity,⁶ progestins are acknowledged risk factors for meningioma. Progestins are synthetic progesterone derivatives, and among them cyproterone acetate, nomegestrol acetate, chlormadinone acetate, promegestone, medrogestone and medroxyprogesterone acetate have been proven to be dose-dependent risk factors for meningioma.^{7–8} When stopping progestin, progestin-associated meningioma can show spontaneous shrinkage or stabilisation.^{9–12} In a retrospective study involving 125 progestin-associated meningiomas, regression was observed in 29.6% of cases, stability in 68.5% and continued growth only in 1.9% of cases. Therefore, these meningiomas can now be managed conservatively.¹³ Progesterone receptor (PR) expression is found at various degrees in meningioma.¹⁴ The expression of PR is higher in premenopausal women (78.2%) compared with postmenopausal women (68.4%) and men (65.1%).¹⁵ Higher PR expression is associated with good prognosis and a lower risk of recurrence.^{16,17} Oestrogen receptors (ERs) seem less correlated to meningioma progression and regression. ERs were only found in 8.7%, 1.6% and 6.8% of grade 1, 2 and 3 meningiomas (grade 3 being the most aggressive meningioma), respectively.¹⁵ Other investigations have reported lower ER expression and found no correlation with recurrence rates.¹⁸ The expression of ER in women (14.7%) is higher compared with men (7.5%). Androgen receptor

expression was identified with a prevalence of up to 88% in recent publications.^{14,19} A recent study on a cohort of patients using androgenic steroids did not find an increased risk of meningioma.²⁰ Zoely is a frequently prescribed combined oral contraceptive (COC) comprising 1.5 mg of oestradiol and 2.5 mg of nomegestrol acetate. Regarding the risk of meningioma, the real-life risk of the COC is currently unknown and the results of the different studies are inconclusive. It is suspected that in some instances, oestradiol might offer a protective effect against meningioma. In COC, most of the case-control studies showed no increased risk of meningiomas in women using hormonal therapy.^{21–27} In a series of incidental intracranial meningioma in perimenopausal women comparing women with and without oestrogen-based hormonal replacement therapy (e-HRT), the growth rate and incidence of meningioma were reported to be lower in the group with e-HRT.²⁸ In a previous report, concurrent oestrogen prescription was weakly but significantly associated with meningioma risk, with an age adjusted HR=1.6 (1.1–2.4) for cyproterone acetate exposure.²⁹ Simultaneous oestrogen prescription with chlormadinone acetate (HR=0.8 (0.5–1.3))³⁰ and nomegestrol acetate (HR=1.0 (0.7–1.7)) was not significantly associated with meningioma risk.³¹ In the latest 'EPIPHARE', a French epidemiological study,⁸ simultaneous oestrogen and progestogen exposure on meningioma risk was not investigated. The risk of meningioma with Zoely was not evaluated in the largest and most recent series of nomegestrol acetate-associated meningioma studies. This medication is not reimbursed in France, therefore Zoely was not part of the examined database.³² The real-life effect of a Zoely-type COC is consequently unknown.

CASE PRESENTATION

For almost a year and a half, a woman in her early 50s was gradually complaining of ophthalmological problems and cognitive dysfunction, which, in a work context, led to a state of mood disturbances. She was absent from work because of these symptoms. Later on, symptoms of gait imbalance arose. She was taking Zoely COC as the contraceptive pill for 5 years. Regarding her medical history, she had two unremarkable pregnancies and had undergone thyroidectomy for follicular adenoma. Since then, she took thyroid hormone replacement therapy. For anxiety and mood swings, she took venlafaxine, alprazolam and mirtazapine. She had no familial history of breast cancer or meningioma, she had no history of radiation therapy nor did she have



© BMJ Publishing Group Limited 2025. Re-use permitted under CC BY-NC. No commercial re-use. See rights and permissions. Published by BMJ Group.

To cite: Lebeau J, Deprez L, Pintiaux A, et al. *BMJ Case Rep* 2025;**18**:e263529. doi:10.1136/bcr-2024-263529

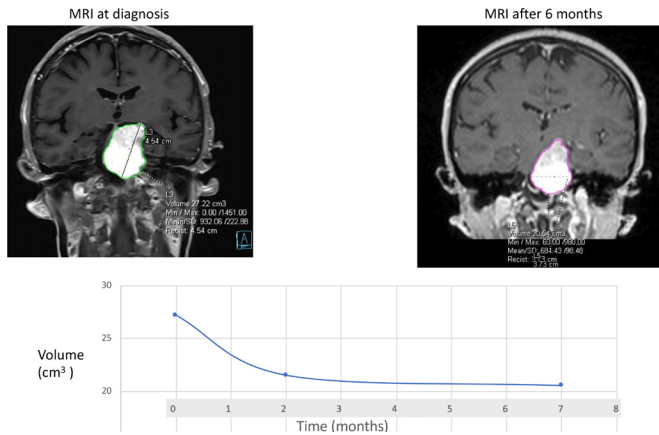


Figure 1 Volumetric evolution of the meningioma after cessation of Zoely.

any specific gynaecological condition or menstrual disorder and she was not obese. The neurological examination was normal; specifically, she had no cranial nerve deficit. The MRI at diagnosis showed a large left petroclival meningioma. The initial volume was 27.22 cm³ (as estimated with syngo.via (Siemens Healthineers, Germany)), based on contrast enhanced spin echo 1 mm T1-weighted imaging on 3T MRI scanner (Siemens Vida, Siemens Healthineers, Germany). The autocontoured tumour volume from syngo.via was reviewed and validated by an expert neuroradiologist (LD). A conservative management was suggested and Zoely was immediately stopped at diagnosis. Except in her medication, there was no other change. There was no active treatment. The patient's diet and lifestyle remained unchanged. At 1-month follow-up, the patient reported a significant regression of gait imbalance and cognitive dysfunction and an improvement of ophthalmological problems. This led to an improvement of her mood. The MRI at 2 months after Zoely interruption showed tumour shrinkage to 21.53 cm³ (see figure 1).

OUTCOME AND FOLLOW-UP

At 6-month follow-up, the patient was asymptomatic and preparing to get back to work. The tumour volume was 20.54 cm³. She did not require any surgical intervention or radiation therapy. A yearly imaging follow-up was planned to assess long-term stability.

DISCUSSION

This is, to our knowledge, the first report of meningioma regression after Zoely discontinuation. We observed a significant volumetric regression of the meningioma already at 2 months and even more, approximately 25%, at 6-month follow-up along with clinical improvement. The natural history of meningioma is not to regress spontaneously. This phenomenon is only observed after delivery in pregnancy-induced meningioma³⁵ or after cessation of treatment in progestin-associated meningioma.¹⁰ The pattern of tumour regression in this case follows the same regression rate as previously described in a series of cyproterone acetate-associated and norgestrel acetate-associated meningiomas.^{10 34} Furthermore, this patient did not have any specific risk factors that would make her specifically sensitive to this COC. As this patient did not receive radiation therapy nor surgery or any other kind of treatment, we conclude that Zoely treatment stopping is the factor behind this clinical and radiological improvement. The main limitation of this article is that only

a single case is reported and that this observation might not be applicable to the general population.

Another limitation of this study is the absence of pathological confirmation. As the tumour has this typical dural attachment and regresses after progestin cessation, there is no other possibility than progestin-induced meningioma. Furthermore, histological confirmation would require surgical excision or stereotactic biopsy. As the clinical course is highly favourable without intervention, any of these procedures carries an unacceptable operative risk for the patient.

Further efforts to elaborate consensual cut-off volumetric regression values should be considered. As meningioma regression observation is confined to progestin-associated meningioma, there is no validated radiological assessment method for volumetric regression. An arbitrary volume of 15% increase was suggested for progression,³⁵ but a consensual volume decrease cut-off for regression remains to be validated.

In a broader perspective, COCs are very useful, not only for their primary indication, but also as an alternative treatment to invasive gynaecological procedures such as hysterectomies. There are several conditions related to perimenopause that could benefit from the use of modern contraceptives, mainly hormonal, with the goals of avoiding unintended pregnancies and giving further possible benefits beyond contraception (menstrual cycle control, avoiding heavy

Patient's perspective

Persistent sight problems, after several visits to the ophthalmologist and new glasses, caused me a lot of stress and ultimately a permanent state of anxiety. I began psychiatric and psychological treatment and was placed on sick leave at the end of 2022. The symptoms were discomfort in my peripheral vision, which made it difficult for me to read PCs and paper documents. I also found it hard to situate myself easily in a new environment. On a cognitive level, I had the impression that my short-term memory was diminished.

Despite the relaxation associated with the work stoppage, the vision problems were a constant reminder that something was wrong.

Around the middle of 2022, problems with balance and clumsiness began. The side-effects of the medication I was taking to combat stress and anxiety were often cited as the reason for these sight and balance problems. At the end of 2022, my lack of balance became increasingly severe and panicky. I could no longer turn around or tilt my head down without nearly falling over. I also felt dizzy in the head. I could no longer coordinate my movements well enough to jump or run.

In early 2023, I fainted twice and lost consciousness. The GP ordered a scan and my meningioma was discovered. The diagnosis was obviously bad news, but for me it was almost a relief because I was so psychologically exhausted. I was finally going to be taken care of. The neurosurgeon immediately took me off the Zoely pill and three weeks later I began to notice a reduction in my vision and balance symptoms. Within a month they were no longer present.

Around middle of 2023, I have been undergoing treatment with a stomatologist, a physiotherapist and an osteopath; the experience I have gone through has most likely caused many tensions, contractions in the cervical, trapezius and temporomandibular joints. I hope to be able to start working again soon.

Learning points

- ▶ Combined oral contraception with Zoely (1.5 mg oestradiol+2.5 mg nomegestrol acetate) can be considered a risk factor of meningioma.
- ▶ Cessation of Zoely leads to the same volumetric regression as with cessation of nomegestrol acetate alone.
- ▶ Conservative treatment may be adequate for Zoely-associated meningioma.

bleeding, reduction of vasomotor symptoms, mood and sleep disorders, brain fog, protection against bone loss and positive oncological risk/benefit balance (endometrial protection)).^{36 37}

NOMAC-E2 (ie, Zoely) can be considered a valid alternative to other COCs in perimenopausal women as it contains oestradiol, the natural oestrogen generally used during menopause.^{38 39}

As discussed, Zoely should be prescribed with the same precautions as nomegestrol acetate alone. Particularly, this COC should be avoided in patients with a history of breast cancer and/or meningioma. An MRI at 5 years of treatment should be proposed and the treatment should be immediately stopped if any neurological or ophthalmological symptoms occur until an MRI proves that the patient does not suffer from meningioma. When stopping the treatment, almost no progestin-induced meningioma required surgery, as only 1.9% of meningiomas managed conservatively showed ongoing growth after treatment withdrawal.¹³

Contributors All authors contributed to this work. GR is the guarantor.

Funding The authors have not declared a specific grant for this research from any funding agency in the public, commercial or not-for-profit sectors.

Competing interests None declared.

Patient consent for publication Consent obtained directly from patient(s).

Ethics approval This study is part of a broader study that was approved by the local committee of CHU de Liège under the reference 2022/09: "Prospective Study on Meningioma and Progestin", "Etude Prospective Méningiomes et Progestatifs (EPMP)" v2.

Provenance and peer review Not commissioned; externally peer reviewed.

Open access This is an open access article distributed in accordance with the Creative Commons Attribution Non Commercial (CC BY-NC 4.0) license, which permits others to distribute, remix, adapt, build upon this work non-commercially, and license their derivative works on different terms, provided the original work is properly cited and the use is non-commercial. See: <http://creativecommons.org/licenses/by-nc/4.0/>.

Case reports provide a valuable learning resource for the scientific community and can indicate areas of interest for future research. They should not be used in isolation to guide treatment choices or public health policy.

ORCID iD

Gilles Reuter <http://orcid.org/0000-0002-7484-3110>

REFERENCES

- 1 Wiemels JL, Wrensch M, Claus EB. Epidemiology and etiology of meningioma. *J Neurooncol* 2010;99:307–14.
- 2 Kerr K, Qualmann K, Esquenazi Y, et al. Familial Syndromes Involving Meningiomas Provide Mechanistic Insight Into Sporadic Disease. *Neurosurgery* 2018;83:1107–18.
- 3 Degeneffe A, De Maertelaer V, De Witte O, et al. The Association Between Meningioma and Breast Cancer: A Systematic Review and Meta-analysis. *JAMA Netw Open* 2023;6:e2318620.
- 4 Umansky F, Shoshan Y, Rosenthal G, et al. Radiation-induced meningioma. *Neurosurg Focus* 2008;24:E7.
- 5 Dolecek TA, Dressler EVM, Thakkar JP, et al. Epidemiology of meningiomas post-Public Law 107-206: The Benign Brain Tumor Cancer Registries Amendment Act. *Cancer* 2015;121:2400–10.
- 6 Khazanchi R, Nandoliya KR, Shahin MN, et al. Obesity and meningioma: a US population-based study paired with analysis of a multi-institutional cohort. *J Neurosurg* 2024;140:1558–67.
- 7 Hoisnard L, Laanani M, Passeri T, et al. Risk of intracranial meningioma with three potent progestogens: A population-based case-control study. *Eur J Neurol* 2022;29:2801–9.
- 8 Roland N, Neumann A, Hoisnard L, et al. Utilisation de progestatifs et risque de méningiome intracrânien: une étude cas-témoins à partir des données du Système national des données de santé (SNDS). *J Epidemiol Popul Health* 2024;72:202290.
- 9 Bernat AL, Bonnin S, Labidi M, et al. Regression of Giant Olfactory Groove Meningioma and Complete Visual Acuity Recovery after Discontinuation of Cyproterone Acetate. *J Ophthalmic Vis Res* 2018;13:355–8.
- 10 Bernat AL, Oyama K, Hamdi S, et al. Growth stabilization and regression of meningiomas after discontinuation of cyproterone acetate: a case series of 12 patients. *Acta Neurochir (Wien)* 2015;157:1741–6.
- 11 Cebula H, Pham TQ, Boyer P, et al. Regression of meningiomas after discontinuation of cyproterone acetate in a transsexual patient. *Acta Neurochir (Wien)* 2010;152:1955–6.
- 12 Gonçalves AMG, Page P, Domigo V, et al. Abrupt regression of a meningioma after discontinuation of cyproterone treatment. *AJNR Am J Neuroradiol* 2010;31:1504–5.
- 13 Malaie H, Samoyeau T, Zanella M, et al. Evolution of the neurosurgical management of progestin-associated meningiomas: a 23-year single-center experience. *J Neurooncol* 2021;152:279–88.
- 14 Portet S, Banor T, Bousquet J, et al. New Insights into Expression of Hormonal Receptors by Meningiomas. *World Neurosurg* 2020;140:e87–96.
- 15 Agopiantz M, Carnot M, Denis C, et al. Hormone Receptor Expression in Meningiomas: A Systematic Review. *Cancers (Basel)* 2023;15:980.
- 16 Pravdenkova S, Al-Mefty O, Sawyer J, et al. Progesterone and estrogen receptors: opposing prognostic indicators in meningiomas. *J Neurosurg* 2006;105:163–73.
- 17 Hsu DW, Efrid JT, Hedley-Whyte ET. Progesterone and estrogen receptors in meningiomas: prognostic considerations. *J Neurosurg* 1997;86:113–20.
- 18 Liu F, Chen W, Chen J. Letter to the Editor. Is there any relationship between estrogen receptor/progesterone receptor status and recurrence of meningioma? *J Neurosurg* 2018;128:1899–901.
- 19 Carroll RS, Zhang J, Dashner K, et al. Androgen receptor expression in meningiomas. *J Neurosurg* 1995;82:453–60.
- 20 Giraldi L, Heerfordt IM, Windfeld-Mathiasen J, et al. Extensive androgen exposure and meningioma risk - A matched cohort study. *Clin Neurol Neurosurg* 2024;239:108217.
- 21 Samarut E, Lugat A, Amelot A, et al. Meningiomas and cyproterone acetate: a retrospective, monocentric cohort of 388 patients treated by surgery or radiotherapy for intracranial meningioma. *J Neurooncol* 2021;152:115–23.
- 22 Cea-Soriano L, Blenk T, Wallander M-A, et al. Hormonal therapies and meningioma: is there a link? *Cancer Epidemiol* 2012;36:198–205.
- 23 Hatch EE, Linet MS, Zhang J, et al. Reproductive and hormonal factors and risk of brain tumors in adult females. *Int J Cancer* 2005;114:797–805.
- 24 Custer B, Longstreth WT Jr, Phillips LE, et al. Hormonal exposures and the risk of intracranial meningioma in women: a population-based case-control study. *BMC Cancer* 2006;6:152.
- 25 Lee E, Grutsch J, Persky V, et al. Association of meningioma with reproductive factors. *Int J Cancer* 2006;119:1152–7.
- 26 Claus EB, Calvocoressi L, Bondy ML, et al. Exogenous hormone use, reproductive factors, and risk of intracranial meningioma in females. *J Neurosurg* 2013;118:649–56.
- 27 Korhonen K, Raitanen J, Isola J, et al. Exogenous sex hormone use and risk of meningioma: a population-based case-control study in Finland. *Cancer Causes Control* 2010;21:2149–56.
- 28 Dressler L, Yuen CA, Wilmington A, et al. Estrogen hormone replacement therapy in incidental intracranial meningioma: a growth-rate analysis. *Sci Rep* 2020;10:17960.
- 29 Weill A, Nguyen P, Labidi M, et al. Use of high dose cyproterone acetate and risk of intracranial meningioma in women: cohort study. *BMJ* 2021;372:n37.
- 30 Nguyen P. Utilisation prolongée de l'acétate de chlormadinone et risque de méningiome intracrânien: une étude de cohorte à partir des données du SNDS. EPI-PHARE, ema.europa.eu; 2021.
- 31 Nguyen P. Utilisation prolongée de l'acétate de nomegestrol et risque de méningiome intracrânien: une étude de cohorte à partir des données du SNDS. EPI-PHARE in ema.europa.eu; 2021.
- 32 Nguyen P, Roland N, Neumann A, et al. Prolonged use of nomegestrol acetate and risk of intracranial meningioma: a population-based cohort study. *Lancet Reg Health Eur* 2024;42:100928.
- 33 Kerschbaumer J, Freyschlag CF, Stockhammer G, et al. Hormone-dependent shrinkage of a sphenoid wing meningioma after pregnancy: case report. *J Neurosurg* 2016;124:137–40.
- 34 Passeri T, Champagne P-O, Bernat A-L, et al. Spontaneous regression of meningiomas after interruption of nomegestrol acetate: a series of three patients. *Acta Neurochir (Wien)* 2019;161:761–5.
- 35 Behbahani M, Skeie GO, Eide GE, et al. A prospective study of the natural history of incidental meningioma—Hold your horses! *Neurooncol Pract* 2019;6:438–50.

- 36 von Stockum S, Becker K, Bauerfeind A, *et al.* NOMAC-E2 compares to LNG combined oral contraceptives in women over forty: real-world PRO-E2 study. *Gynecol Endocrinol* 2023;39:2166032.
- 37 Grandi G, Di Vinci P, Sgandurra A, *et al.* Contraception During Perimenopause: Practical Guidance. *Int J Womens Health* 2022;14:913–29.
- 38 Troia L, Martone S, Morgante G, *et al.* Management of perimenopause disorders: hormonal treatment. *Gynecol Endocrinol* 2021;37:195–200.
- 39 Pintiaux A, Gaspard U, Nisolle M. Zoely, a combined oral contraceptive, monophasic pill containing estradiol and norgestrel acetate. *Rev Med Liege* 2012;67:152–6.

Copyright 2025 BMJ Publishing Group. All rights reserved. For permission to reuse any of this content visit <https://www.bmj.com/company/products-services/rights-and-licensing/permissions/>
BMJ Case Report Fellows may re-use this article for personal use and teaching without any further permission.

Become a Fellow of BMJ Case Reports today and you can:

- ▶ Submit as many cases as you like
- ▶ Enjoy fast sympathetic peer review and rapid publication of accepted articles
- ▶ Access all the published articles
- ▶ Re-use any of the published material for personal use and teaching without further permission

Customer Service

If you have any further queries about your subscription, please contact our customer services team on +44 (0) 207111 1105 or via email at support@bmj.com.

Visit casereports.bmj.com for more articles like this and to become a Fellow